




Atul Luthra



ECHO

MADE EASY[®]

3rd Edition

JAYPEE

Echo Made Easy[®]

www.cambodiamed.blogspot.com

Echo Made Easy[®]

Third Edition

Atul Luthra

MBBS MD DNB

Diplomate

National Board of Medicine

Physician and Cardiologist

New Delhi, India

www.atulluthra.in

atulluthra@sify.com



**JAYPEE BROTHERS MEDICAL
PUBLISHERS (P) LTD**

New Delhi • Panama City • London • Dhaka • Kathmandu



Jaypee Brothers Medical Publishers (P) Ltd.

Headquarter

Jaypee Brothers Medical Publishers (P) Ltd
4838/24, Ansari Road, Daryaganj
New Delhi 110 002, India
Phone: +91-11-43574357
Fax: +91-11-43574314
Email: jaypee@jaypeebrothers.com

Overseas Offices

J.P. Medical Ltd.,
83 Victoria Street London
SW1H 0HW (UK)
Phone: +44-2031708910
Fax: +02-03-0086180
Email: info@jpmedpub.com

Jaypee-Highlights Medical Publishers Inc.
City of Knowledge, Bld. 237, Clayton
Panama City, Panama
Phone: +507-301-0496
Fax: +507-301-0499
Email: cservice@jphmedical.com

Jaypee Brothers Medical Publishers (P) Ltd
17/1-B Babar Road, Block-B
Shaymali, Mohammadpur
Dhaka-1207, Bangladesh
Mobile: +08801912003485
Email: jaypeedhaka@gmail.com

Jaypee Brothers Medical Publishers (P) Ltd
Shorakhute
Kathmandu, Nepal
Phone: +00977-9841528578
Email: jaypee.nepal@gmail.com

Website: www.jaypeebrothers.com
Website: www.jaypeedigital.com

© 2012, Jaypee Brothers Medical Publishers

All rights reserved. No part of this book may be reproduced in any form or by any means without the prior permission of the publisher.

Inquiries for bulk sales may be solicited at: jaypee@jaypeebrothers.com

This book has been published in good faith that the contents provided by the author contained herein are original, and is intended for educational purposes only. While every effort is made to ensure accuracy of information, the publisher and the author specifically disclaim any damage, liability, or loss incurred, directly or indirectly, from the use or application of any of the contents of this work. If not specifically stated, all figures and tables are courtesy of the author.

Echo Made Easy®

First Edition : 2005

Second Edition : 2007

Third Edition : **2012**

ISBN 978-81-8448-939-2

Printed at

To
My Parents
Ms Prem Luthra
and
Mr Prem Luthra
Who guide and bless me
from heaven



Preface to the Third Edition

Ever since the second edition of *Echo Made Easy* was published five years back, there have been tremendous advancements in the field of echocardiography. To name a few, three-dimensional technique, tissue-Doppler study and myocardial-contrast imaging have gained considerable popularity. Nevertheless, there remains an unmet need for a simplistic book on basic echocardiography for the uninitiated reader. It gives me immense pleasure to present to cardiology students, resident doctors, nurses and technicians working in cardiology units, this vastly improved third edition of *Echo Made Easy*.

The initial chapters will help the readers to understand the principles of conventional echo and color-Doppler imaging, the various echo-windows and the normal views of cardiac structures. The abnormalities observed in different forms of heart disease including congenital, valvular, coronary, hypertensive, myocardial, endocardial and pericardial diseases have been discussed under separate sections. Due emphasis has been laid on diagnostic pitfalls, differential diagnosis, causative factors and clinical significance.

Those who have read the previous editions of *Echo Made Easy* will definitely notice a remarkable improvement in the layout of the book. Readers will appreciate a bewildering array of striking figures and impressive tables. For this, I am extremely grateful to Dr Rakesh Gupta, an expert in echocardiography of international repute. He has been very kind and generous in providing me with real-time images from his vast and valuable

collection. I am also very thankful to M/s Jaypee Brothers Medical Publishers (P) Ltd, New Delhi, India, who infuse life into subsequent editions of all my books, by virtue of their typesetting and artwork expertise. Do keep pouring with your comments and criticism. Bouquets and brickbats are both welcome. Bon voyage through *Echo Made Easy*, third edition.

Atul Luthra



Preface to the First Edition

Ultrasound has revolutionized clinical practice by providing the fifth dimension to physical examination after inspection, palpation, percussion and auscultation. Echocardiography is the application of ultrasound for examining the heart. It is a practically useful, widely available, cost-effective and noninvasive diagnostic tool. Usage of echo is rapidly expanding with more and more clinicians requesting for and interpreting it to solve vexing clinical dilemmas.

While I was preparing the manuscript of this book, many a time two questions crossed my mind. First, is such a book really required? And second, am I the right person to write it? At the end of the day, I, somehow, managed to convince myself that a precise and practical account of echocardiography is indeed required and that an academic Physician like myself can do justice to this highly technical subject.

The book begins with the basic principles of ultrasound and Doppler and the clinical applications of various echo-modalities including 2-D echo, M-mode scan, Doppler echo and color-flow mapping. This is followed by an account of different echo-windows and normal echo-views along with normal values and dimensions. The echo features of various forms of heart disease such as congenital, valvular, coronary and hypertensive disorders are individually discussed. Due emphasis has been laid on pitfalls in diagnosis, differentiation between seemingly similar findings, their causation and clinical relevance. Understandably, figures and diagrams can never create the impact of dynamic echo display on the video-screen. Nevertheless, they have been especially created to leave a long-lasting visual

impression on the mind. In keeping with the spirit of simplicity, difficult topics like complex congenital cardiac disease, prosthetic heart valves and transesophageal echocardiography have been purposely excluded.

The book is particularly meant for students of cardiology as well as keen established clinicians wanting to know more about echo. If I can coax some Physicians like myself to integrate echocardiography into their day-to-day clinical practice, I will feel genuinely elated for a mission successfully accomplished.

Atul Luthra



Acknowledgments

I am extremely grateful to:

- My school teachers who helped me to acquire good command over English language.
- My professors at medical college who taught me the science and art of clinical medicine.
- My heart patients whose echo-reports stimulated my gray matter and made me wiser.
- Authors of books on echocardiography to which I referred liberally, while preparing the manuscript.
- Dr Rakesh Gupta who has been kind and supportive in providing me with excellent images.
- My readers whose generous appreciation, candid comments and constructive criticism constantly stimulate me.
- M/s Jaypee Brothers Medical Publishers (P) Ltd, New Delhi, India, who repose their unflinching faith in me and provide encouragement along with expert editorial assistance.



Contents

1. <i>What is an Echo?</i>	1
• Principles of Ultrasound	1
• Principles of Doppler	6
2. <i>Conventional Echo</i>	15
• Two-dimensional (2-D) Echo	15
• Motion-mode (M-Mode) Echo	17
• Continuous Wave (CW) Doppler	18
• Pulsed Wave (PW) Doppler	19
• Clinical Applications of Echo	20
3. <i>Color Doppler Echo</i>	23
• Principles of Color Doppler	23
• Applications of Color Doppler	28
4. <i>The Echo Windows</i>	33
• Transthoracic Echo	33
• Standard Echo Windows	34
• Transesophageal Echo	43
• Future Directions in Echo	46
5. <i>Normal Views and Values</i>	51
• Echo Interpretation	51
• Scanning Sequence	51
• What is Normal?	53

• Normal Variants	53
• Normal Dimensions	55
• Normal Valves	60
6. Ventricular Dysfunction	65
• LV Systolic Dysfunction	65
• LV Diastolic Dysfunction	77
• RV Systolic Dysfunction	83
7. Cardiomyopathies	87
• Dilated Cardiomyopathy	87
• Restrictive Cardiomyopathy	92
• Hypertrophic Cardiomyopathy	96
8. Coronary Artery Disease	103
• Indications for Echo in CAD	103
• Myocardial Ischemia	104
• Myocardial Infarction	105
• Left Ventricular Dysfunction	111
• Right Ventricular Dysfunction	113
• Acute Mitral Regurgitation	114
• Ventricular Septal Defect	116
• Left Ventricular Aneurysm	117
• Ventricular Mural Thrombus	118
• Acute Pericardial Effusion	119
• Coronary Artery Anomalies	119
• Simulating Conditions	120
• Stress Echocardiography	121
9. Systemic Hypertension	125
• Indications for Echo in HTN	125
• Left Ventricular Hypertrophy	125

10. <i>Pulmonary Hypertension</i>	131
• Detection of Pulmonary HTN	131
• Estimation of Pulmonary HTN	134
11. <i>Diseases of Aorta</i>	141
• Sinus of Valsalva Aneurysm	143
• Dilatation of Aorta	144
• Aneurysm of Aorta	145
• Coarctation of Aorta	146
• Dissection of Aorta	148
12. <i>Congenital Diseases</i>	151
• Ventricular Septal Defect	152
• Atrial Septal Defect	154
• Patent Ductus Arteriosus	158
• Tetralogy of Fallot	160
• Eisenmenger Reaction	162
• Quantification of Shunt	162
13. <i>Valvular Diseases</i>	165
• Mitral Stenosis	166
• Mitral Valve Prolapse	176
• Flail Mitral Leaflet	179
• Mitral Annular Calcification	181
• Mitral Regurgitation	183
• Tricuspid Stenosis	191
• Tricuspid Regurgitation	194
• Ebstein Anomaly	200
• Aortic Stenosis	201

• Aortic Regurgitation	214
• Pulmonary Stenosis	225
• Pulmonary Regurgitation	228
14. Pericardial Diseases	233
• Pericardial Effusion	233
• Cardiac Tamponade	237
• Constrictive Pericarditis	240
15. Endocardial Diseases	243
• Classification of Endocarditis	243
• Predisposing Cardiac Lesions	244
• Indications for Serial Echoes	245
• Echo Features of Endocarditis	245
16. Intracardiac Masses	253
• Cardiac Tumors	253
• Left Atrial Myxoma	254
• Atrial Thrombus	258
• Ventricular Thrombus	261
17. Thromboembolic Diseases	265
• Indications for Echo in CVA	265
• Thromboembolism in Mitral Stenosis	267
18. Systemic Diseases	269
 <i>Index</i>	 271



1

What is an Echo?

PRINCIPLES OF ULTRASOUND

- Sound is a mechanical disturbance produced by passage of energy through a medium which may be gas, liquid or solid. Every sound has a particular frequency, a wavelength, its own velocity and an intensity.
- Sound energy is transmitted through a medium in the form of cycles or waves. Each wave consists of a peak and a trough. The peak coincides with adjacent group of molecules moving towards each other (compression phase). The trough coincides with adjacent group of molecules moving away from each other (rarefaction phase).
- Frequency of sound is the number of times per second, sound undergoes a cycle of rise and fall. It is expressed in cycles per second, or hertz (Hz) and multiples thereof.
 - 1 hertz (Hz) = 1 cycle per second
 - 1 kilohertz (KHz) = 10^3 Hz = 1000 Hz
 - 1 megahertz (MHz) = 10^6 Hz = 1000000 Hz
- Frequency is appreciated by the listener as pitch of sound.
- Wavelength is the distance travelled by sound in one cycle of rise and fall. The length of the wave is the distance between two consecutive peaks.

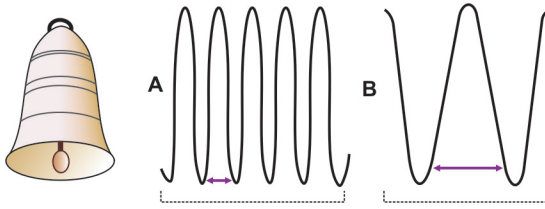


Fig. 1.1: Relationship between frequency and wavelength:
 A. High frequency, short wavelength
 B. Low frequency, long wavelength

- Frequency and wavelength are inter-related. Since, sound travels a fixed distance in one second, more the cycles in a second (greater the frequency), shorter is the wavelength (Fig. 1.1).
- Therefore, $\text{Velocity} = \text{Frequency} \times \text{Wavelength}$.
- Velocity of sound is expressed in meters per second (m/sec) and is determined by the nature of the medium through which sound propagates. In soft tissue, the velocity is 1540 m/sec.
- Intensity of sound is nothing but its loudness or amplitude expressed in decibels. Higher the intensity of sound, greater is the distance upto which it is audible.
- The normal audible range of sound frequency is 20 Hz to 20 KHz. Sound whose frequency is above what is audible to the human ear (more than 20 KHz) is known as ultrasound.
- The technique of using ultrasound to examine the heart is known as echocardiography or simply echo.
- Electricity and ultrasound are two different forms of energy that can be transformed from one to the other by special crystals made of ceramic such as barium titanate.
- Ultrasound relies on the property of such crystals to transform electrical current of changing voltage into mechanical vibrations or ultrasound waves. This is known as the piezoelectric (pressure-electric) effect (Fig. 1.2).

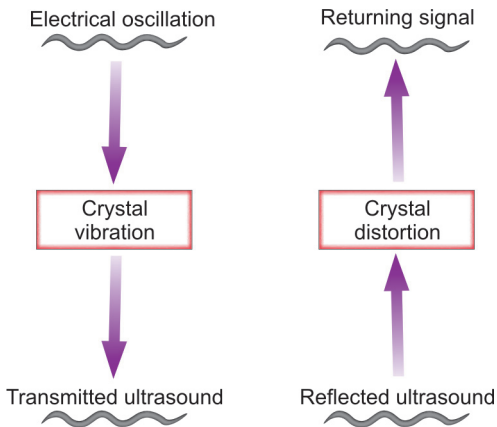


Fig. 1.2: The piezoelectric effect in ultrasound

- When electrical current is passed through a piezoelectric crystal, the crystal vibrates. This generates ultrasound waves which are transmitted through the body by the transducer which houses several such crystals.
- Most of these ultrasound waves are scattered or absorbed by the tissues, without any obvious effect. Only a few waves are reflected back to the transducer and echoed.
- Reflected ultrasound waves again distort the piezoelectric crystals and produce an electrical current. These reflected echoes are processed by filtration and amplification, to be eventually displayed on the cathode-ray-tube.
- The reflected signal gives information about the depth and nature of the tissue studied. Most of the reflection occurs at interfaces between tissues of different density and hence a different echo-reflectivity.

TABLE 1.1**Echo-reflectivity of various tissues on the gray-scale**

<i>Tissue</i>	<i>Reflectivity</i>	<i>Shade</i>
Bone	High	White
Muscle	Low	Gray
Air	Nil	Black

- The magnitude of electrical current produced by the reflected ultrasound determines the intensity and brightness on the display screen.
- On the gray-scale, high reflectivity (from bone) is white, low reflectivity (from muscle) is gray, and no reflection (from air) is black (Table 1.1).
- The location of the image produced by the reflected ultrasound depends upon the time lag between transmission and reflection of ultrasound.
- Deeper structures are shown on the lower portion of the display screen while superficial structures are shown on the upper portion. This is because the transducer is at the apex of the triangular image on the screen (Fig. 1.3).
- When ultrasound is transmitted through a uniform medium, it maintains its original direction but gets progressively scattered and absorbed.
- When ultrasound waves generated by the transducer encounter an interface between tissues of different density and thus different echo-reflectivity, some of the ultrasound waves are reflected back.
- It is these reflected ultrasound waves that are detected by the transducer and analyzed by the echo-machine.
- The wavelength of sound is the ratio between velocity and frequency (Wavelength = Velocity/Frequency).

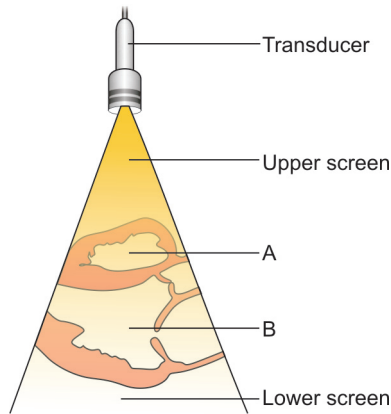


Fig. 1.3: Transducer is at the apex of visual display:
 A. Right ventricle in the upper screen
 B. Left ventricle in the lower screen

- Since wavelength and frequency are inversely related, higher the frequency of ultrasound, shorter is the wavelength. Shorter the wavelength, higher is the image resolution and lesser is the penetration.
- Therefore, high frequency probes (5.0–7.5 MHz) provide better resolution when applied for superficial structures and in children (Table 1.2).

TABLE 1.2

Features and applications of probes having different frequency

Frequency (MHz)	Penetration in tissue	Resolution of image	Study depth	Age group
2.5–3.5	Good	Less	Deep	Adults
5.0–7.5	Less	Good	Superficial	Children

- Conversely, lower the frequency of ultrasound, longer is the wavelength. Longer the wavelength, lower is the image resolution and greater is the tissue penetration.
- Therefore, low frequency probes (2.5–3.5 MHz) provide better penetration when applied for deeper structures and in adults (Table 1.2).

PRINCIPLES OF DOPPLER

- The Doppler acoustic effect is present and used by us in everyday life, although we do not realize it. Imagine an automobile sounding the horn and moving towards you, going past you and then away from you.
- The pitch of the horn sound is higher when it approaches you (higher frequency) than when it goes away from you (lower frequency).
- This means that the nature of sound depends upon the relative motion of the listener and the source of sound.
- The change of frequency (Doppler shift) depends upon the speed of the automobile and the original frequency of the horn sound.
- Ultrasound reflected back from a tissue interface gives information about the depth and echo-reflectivity of the tissue. On the other hand, Doppler utilizes ultrasound reflected back from moving red blood cells (RBCs).
- The Doppler principle is used to derive the velocity of blood flow. Flow velocity is derived from the change of frequency that occurs between transmitted (original) and reflected (observed) ultrasound signal.
- The shift of frequency (Doppler shift) is proportional to ratio of velocity of blood to speed of sound and to the original frequency.

- It is calculated from the following formula:

$$F_D = \frac{V}{C} F_o$$

F_D : Doppler shift V : Velocity of blood

F_o : Original frequency C : Speed of sound

Therefore, velocity of blood flow is:

$$V = \frac{F_D \times C}{F_o}$$

Further refinement of this formula is:

$$V = \frac{F_D \times C}{2F_o \times \cos \theta}$$

- The original frequency (F_o) is multiplied by 2 since Doppler shift occurs twice, during forward transmission as well as during backward reflection.
- Cosine theta ($\cos \theta$) is applied as a correction for the angle between the ultrasound beam and blood flow. The angle between the beam and flow should be less than 20° to ensure accurate measurement.
- $\cos \theta$ is 1 if the beam is parallel to blood flow and maximum velocity is observed. $\cos \theta$ is 0 if the beam is perpendicular to blood flow and no velocity is detected.
- It is noteworthy that for Doppler echo, maximum velocity information is obtained with the ultrasound beam aligned parallel to the direction of blood flow being studied.
- This is in sharp contrast to conventional echo, where best image quality is obtained with the ultrasound beam aligned perpendicular to the structure being studied.

- Since, the original frequency value ($2 \times F_0$) is in the denominator of the velocity equation, it is important to remember that maximum velocity information is obtained using a low frequency (2.5 MHz) transducer.
- There is a direct relationship between the peak velocity of blood flow through a stenotic valve and the pressure gradient across the valve.
- Understandably when the valve orifice is small, blood flow has to accelerate in order to eject the same stroke volume. This increase in velocity is measured by Doppler.
- The pressure gradient across the valve can be calculated using the simplified Bernaulli equation:

$$\Delta P = 4 V^2$$

P: pressure gradient (in mm Hg)

V: peak flow velocity (in m/sec)

- This equation is frequently used during Doppler evaluation of stenotic valves, regurgitant lesions and assessment of intracardiac shunts.
- The velocity information provided by Doppler complements the anatomical information provided by standard M-mode and 2-D Echo.
- Analysis of the returning Doppler signal not only provides information about flow velocity but also flow direction.
- By convention, velocities towards the transducer are displayed above the baseline (positive deflection) and velocities away from the transducer are displayed below the baseline (negative deflection) (Fig. 1.4).
- The returning Doppler signal is a spectral trace of velocity display on a time axis. The area under curve (AUC) of the spectral trace is known as the flow velocity integral (FVI) of that velocity display.

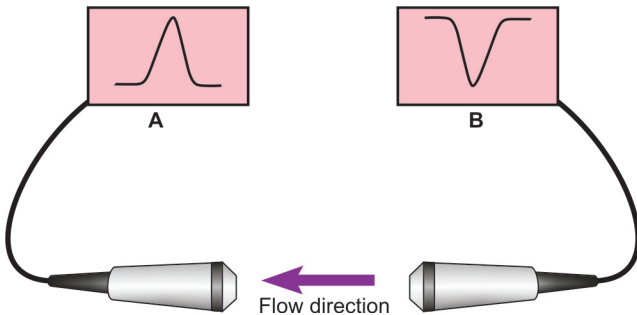


Fig. 1.4: Direction of blood flow and the polarity of deflection:
 A. Towards the transducer, positive deflection
 B. Away from transducer, negative deflection

- The value of FVI is determined by peak flow velocity and ejection time. It can be calculated by the software of most echo machines.
- Careful analysis of the spectral trace of velocity also gives densitometric information. Density relates to the number of RBCs moving at a given velocity.
- When blood flow is smooth or laminar, most RBCs travel at the same velocity, since they accelerate and decelerate simultaneously.
- The spectral trace then has a thin outline with very few RBCs travelling at other velocities (Figs 1.5A and C). This is known as low variance of velocities.
- When blood flow is turbulent as across stenotic valves, there is a wide distribution of RBCs velocities and the Doppler signal appears “filled in” (Fig. 1.5B). This is known as high variance of velocities, “spectral broadening” or “increased band width”.

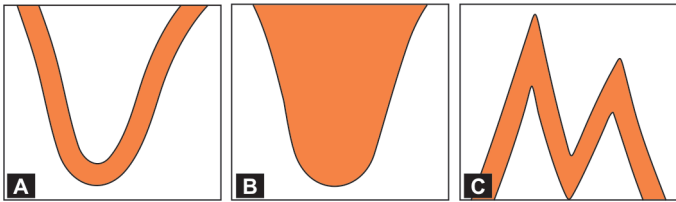


Fig. 1.5: Various patterns of blood flow seen on Doppler:

- A. Laminar flow across a normal aortic valve
- B. Turbulent flow across stenotic aortic valve
- C. Normal flow pattern across the mitral valve

- It is to be borne in mind that turbulence and spectral broadening are often associated but not synonymous with high flow velocity.
- The intensity of the Doppler signal is represented on the gray-scale as darker shades of gray (Fig. 1.6).
- Maximum number of RBCs travelling at a particular velocity cast a dark shade on the spectral trace. Few RBCs travelling at a higher velocity cast a light shade.
- This is best seen on the Doppler signal from a stenotic valve. The spectral display is most dense near the baseline reflecting most RBCs moving at a low velocity close to the valve (Fig. 1.6A).
- Few RBCs accelerating through the stenotic valve are at a high velocity (Fig. 1.6B).
- The Doppler echo modes used clinically are continuous wave (CW) Doppler and pulsed wave (PW) Doppler.
- In CW Doppler, two piezoelectric crystals are used, one to transmit continuously and the other to receive continuously, without any time gap.
- It can measure high velocities but does not discriminate between several adjacent velocity components. Therefore, CW Doppler cannot precisely locate the signal which may

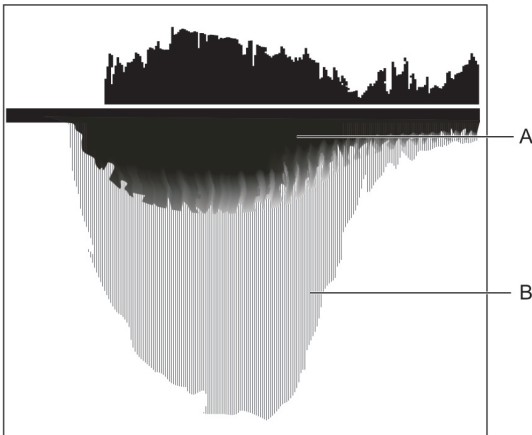


Fig. 1.6: Doppler signal across a stenotic aortic valve:
A. Most RBCs moving at low velocity
B. Few RBCs moving at high velocity

originate from anywhere along the length or breadth of the ultrasound beam.

- In PW Doppler, a single piezoelectric crystal to first emits a burst of ultrasound and then receives it after a preset time gap. This time is required in order to switch-over into the receiver mode.
- To locate the velocity, a 'sample volume' indicated by a small box or circle, is placed over the 2-D image at the region of interest. The 'sample volume' can be moved in depth along the path of PW beam indicated as a broken line, until a maximum velocity signal is obtained (Fig. 1.7).
- PW Doppler can precisely localize the site of origin of a velocity signal, unlike CW Doppler.
- Because of the time delay in receiving the reflected ultrasound signal, PW Doppler cannot accurately detect high velocities exceeding 2 m/sec.

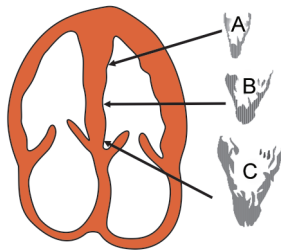


Fig. 1.7: Doppler signal from various levels of LV:
 A. LV apex
 B. Mid LV
 C. Sub-aortic

- However, PW Doppler provides a spectral tracing of better quality than does CW Doppler (Fig. 1.8).
- The single crystal of PW Doppler can emit a fresh pulse only after the previous pulse has returned. The time interval between pulse repetition is therefore the sum of the time taken by the transmitted signal to reach the target and the time taken by the returning signal to reach the transducer.

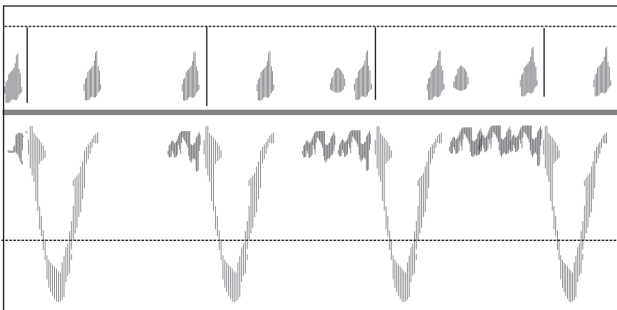


Fig. 1.8: Doppler signal from a regurgitant aortic valve showing laminar flow

- The rate at which pulses are emitted is known as the pulse repetition frequency (PRF). Obviously, greater the depth of interrogation, more is the time interval between pulse repetition and lower is the PRF.
- Pulse repetition frequency (PRF) should be greater than twice the velocity being measured. The PRF decreases as the depth of interrogation increases.
- The maximum value of Doppler frequency shift that can be accurately measured with a given pulse repetition frequency (PRF) is called the Nyquist limit.
- The inability of PW Doppler to detect high-frequency Doppler shifts is known as aliasing. Aliasing occurs when the Nyquist limited is exceeded.
- Aliasing is an artificial reversal of velocity and distortion of the reflected signal. The phenomenon of aliasing is also called “wrap around.”
- Aliasing can be tackled by one of these modifications:
 - high pulse repetition frequency
 - multigate acquisition technique
 - reduced depth of interrogation
 - shifting of display baseline.



2

Conventional Echo

The modalities of echo used clinically are:

I. Image echo

- Two-dimensional echo (2-D echo)
- Motion-mode echo (M-mode echo).

II. Doppler echo

- Continuous wave (CW) Doppler
- Pulsed wave (PW) Doppler.

Different echo modalities are not mutually exclusive but complement each other and are often used together.

All of them follow the same principle of ultrasound but differ with respect to the manner in which reflected sound waves are received and displayed.

TWO-DIMENSIONAL (2-D) ECHO

- Ultrasound reflected from a tissue interface distorts the piezoelectric crystal and generates an electrical signal. The signal produces a dot (spot) on the display screen.
- The location of the dot indicates the distance of the structure from the transducer. The brightness of the dot indicates the strength of the returning signal.

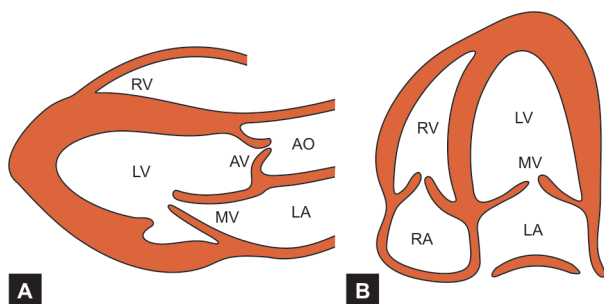


Fig. 2.1: Two-dimensional echo (2-D Echo) views:
 A. Parasternal long-axis (PLAX) view
 B. Apical four-chamber (A4CH) view

- To create a 2-D image, the ultrasound beam has to be swept across the area of interest. Ultrasound is transmitted along several (90 to 120) scan lines over a wide (45° to 90°) arc and many (20 to 30) times per second.
- The superimposition of simultaneously reflected dots, builds up a real-time image on the display screen. Production of images in quick succession creates an anatomical cross-section of structures. Any image frame can be frozen, studied on the screen or printed out on thermal paper or on X-ray film.
- 2-D echo is useful to evaluate the anatomy of the heart and the relationship between different structures (Fig. 2.1).
- Intracardiac masses and extracardiac pericardial abnormalities can be noted. The motion of the walls of ventricles and cusps of valves is visualized.
- Thickness of ventricular walls and dimensions of chambers can be measured and stroke volume, ejection fraction and cardiac output can be calculated.
- 2-D image is also used to place the 'cursor line' for M-mode echo and to position the 'sample volume' for Doppler echo.

MOTION-MODE (M-MODE) ECHO

- In the M-mode tracing, ultrasound is transmitted and received along only one scan line.
- This line is obtained by applying the cursor to the 2-D image and aligning it perpendicular to the structure being studied. The transducer is finely angulated until the cursor line is exactly perpendicular to the image.
- M-mode is displayed as a continuous tracing with two axes. The vertical axis represents distance between the moving structure and the transducer. The horizontal axis represents time.
- Since only one scan line is imaged, M-mode echo provides greater sensitivity than 2-D echo for studying the motion of moving cardiac structures.
- Motion and thickness of ventricular walls, changing size of cardiac chambers and opening and closure of valves is better displayed on M-mode (Fig. 2.2).

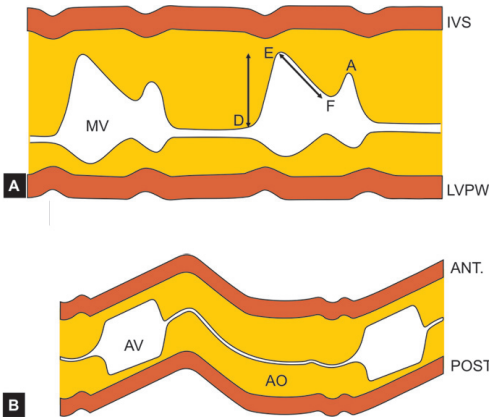


Fig. 2.2: Motion-mode echo (M-mode Echo) levels:
 A. Mitral valve (MV) level
 B. Aortic valve (AV) level

- Simultaneous ECG recording facilitates accurate timing of cardiac events. Similarly, the flow pattern on color flow mapping can be timed in relation to the cardiac cycle.

CONTINUOUS WAVE (CW) DOPPLER

- CW Doppler transmits and receives ultrasound continuously. It can measure high velocities without any upper limit and is not hindered by the phenomenon of aliasing.
- However, CW Doppler cannot precisely localize the returning signal which may originate anywhere along the length or width of the ultrasound beam (Fig. 2.3).
- This Doppler modality is used for rapid scanning of the heart in search of high velocity signals and abnormal flow patterns.
- Since the Doppler frequency shift is in the audible range, the audio signal is used to angulate and rotate the transducer in order to obtain the best visual display.

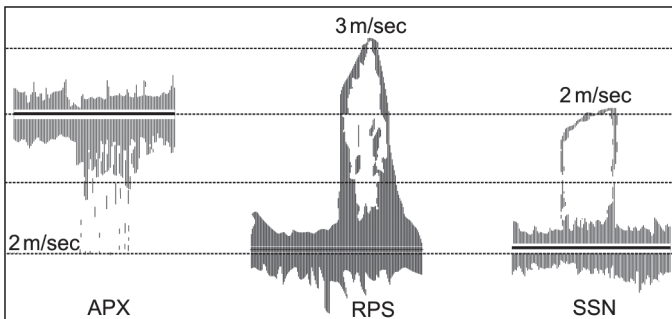


Fig. 2.3: Continuous wave (CW) Doppler signal of stenotic aortic valve from multiple views; maximum velocity is 3 m/sec
APX: apical 5 chamber view
RPS: right parasternal view
SSN: suprasternal notch

- CW Doppler display forms the basis for placement of “sample volume” to obtain PW Doppler spectral tracing.
- CW Doppler is used for grading the severity of valvular stenosis and assessing the degree of valvular regurgitation.
- An intracardiac left-to-right shunt such as a ventricular septal defect can be quantified.
- By using CW Doppler signal of the tricuspid valve, pulmonary artery pressure can be calculated.

PULSED WAVE (PW) DOPPLER

- PW Doppler transmits ultrasound in pulses and waits to receive the returning ultrasound after each pulse.
- Because of the time delay in receiving the reflected signal which limits the sampling rate, it cannot detect high velocities.
- At velocities over 2 m/sec, there occurs a reversal of flow known as the phenomenon of aliasing.
- However, PW Doppler provides a better spectral tracing than CW Doppler, which is used for calculations (Fig. 2.4).

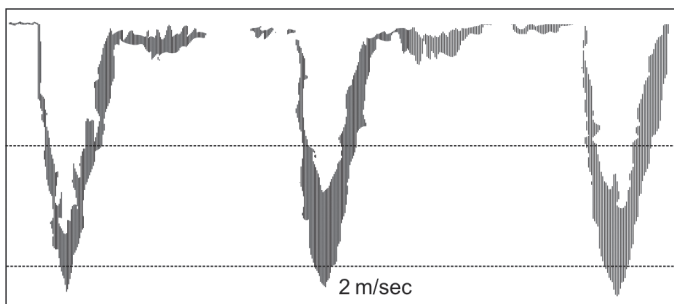


Fig. 2.4: Pulsed wave (PW) Doppler signal of a stenotic aortic valve from a single view; maximum velocity is 2 m/sec

- PW Doppler modality is used to localize velocity signals and abnormal flow patterns picked up by CW Doppler and color flow mapping, respectively.
- The mitral valve inflow signal is used for the assessment of left ventricular diastolic dysfunction.
- The aortic valve outflow signal is used for the calculation of stroke volume and cardiac output.

CLINICAL APPLICATIONS OF ECHO

2-D Echo

- Anatomy of heart and structural relationships.
- Intracardiac masses and pericardial diseases.
- Motion of ventricular walls and valvular leaflets.
- Wall thickness, chamber volume, ejection fraction.
- Calculation of stroke volume and cardiac output.
- Architecture of valve leaflets and size of orifice.
- Positioning for M-mode image and Doppler echo.

M-Mode Echo

- Cavity size, wall thickness and muscle mass.
- Excursion of ventricular walls and valve cusps.
- Timing of cardiac events with synchronous ECG.
- Timing of flow pattern with color flow mapping.

CW Doppler

- Grading the severity of valvular stenosis.
- Assessing degree of valvular regurgitation.
- Quantifying the pulmonary artery pressure.
- Scanning the heart for high velocity signal.

PW Doppler

- Assessment of left ventricular diastolic function.
- Calculation of stroke volume and cardiac output.
- Estimation of orifice area of stenotic aortic valve.
- Localization of flow pattern seen on CF mapping.
- Localization of signal picked up on CW Doppler.
- Application of spectral tracing for calculations.



3

Color Doppler Echo

PRINCIPLES OF COLOR DOPPLER

- Color Doppler echocardiography is an automated version of the pulsed-wave Doppler. It is also known as real-time Doppler imaging.
- Color Doppler provides a visual display of blood flow within the heart, in the form of a color flow map.
- The color flow map is rightly called a “non-invasive angiogram” since it simultaneously displays both anatomical as well as functional information.
- After a burst of ultrasound is reflected back along a single scan-line, as in pulsed-wave Doppler, it is analyzed by the autocorrelator of the echo-machine.
- The autocorrelator compares the frequency of the returning signal with the original frequency. It automatically assigns a color-code to the frequency difference.
- Analysis of several sample volumes down each scan-line and of several such scan-lines using multigate Doppler, creates a color-encoded map of the area being interrogated.
- The color flow map encodes information about direction as well as velocity of blood flow. When this map is superimposed on the image sector of interest, appropriate interpretation is made.

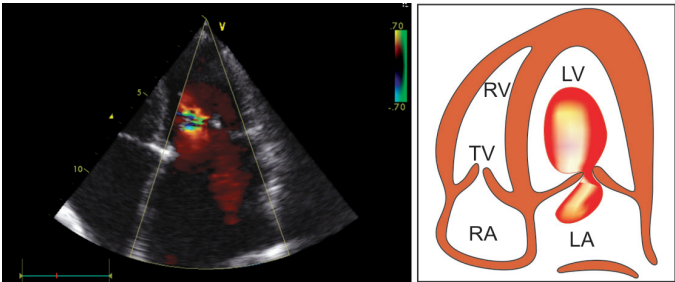


Fig. 3.1: Color flow map of a normal mitral valve from A4CH view showing a red-colored jet

- The colors assigned to blood flow towards the transducer are shades of red white colors assigned to flow away from the transducer are hues of blue (Fig. 3.1).
- This is in accordance with the BART convention:
Blue Away Red Towards
- As the velocity of blood flow increases, the shade or hue assigned to the flow gets progressively brighter. Therefore, low velocities appear dull and dark while high velocities appear bright and light.
- When blood flow at high velocity becomes turbulent, it superimposes color variance into the color flow map. This is seen as a mosaic pattern with shades of aquamarine, green and yellow (Fig. 3.2).
- This reversal of color-code, as it “wraps around” and outlines the high velocity, is the color counterpart of aliasing observed on pulsed-wave Doppler.
- The differences between a color flow map and a spectral trace obtained from pulsed-wave Doppler are summarized in Table 3.1.

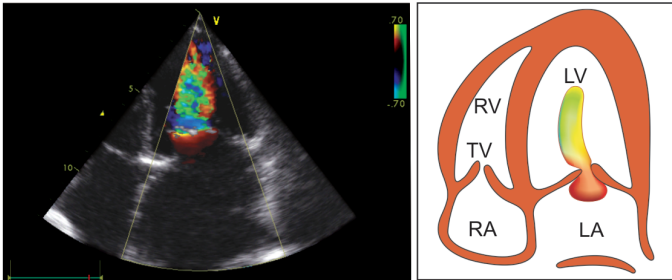


Fig. 3.2: Color flow map of a stenotic mitral valve from A4CH view showing a mosaic pattern

TABLE 3.1

Differences between spectral trace and color flow on Doppler

	<i>Spectral trace</i>	<i>Color flow</i>
Display	Scan-line	Flow-map
Information	Direction	Color
Velocity	Value	Shade
Turbulence	Aliasing	Mosaic

Technique

- The technique of color Doppler is similar to that of conventional echo and pulsed-wave Doppler. The transducer is placed in the usual parasternal or apical window as done for standard echo imaging.
- Once an anatomical image is obtained, the color is turned on. Color flow maps are automatically displayed and superimposed on the standard echo image (Fig. 3.3).

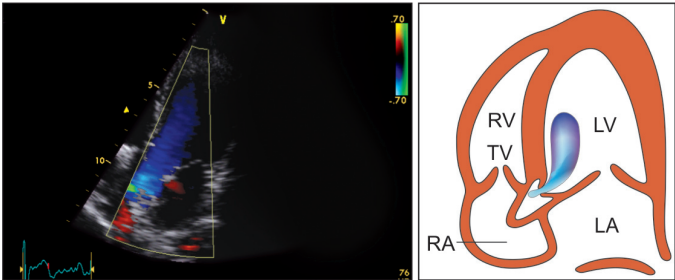


Fig. 3.3: Color flow map of ventricular outflow tract from A5CH view showing a blue jet

- When the color map has been visualized, the transducer is slightly angulated. This is done to optimize the visual display. The final image is often a trade-off between an optimal anatomical image and a good color flow map.
- The gray-scale tissue-gain setting must be just enough to provide structural reference. Setting the tissue-gain too low blurs the anatomical image. Setting the tissue-gain too high induces gray-scale artefact or “background noise” and distorts the color display (Fig. 3.4).
- The velocity-filter and color-gain settings must be optimal. Setting the filter high and gain low may miss color flow maps of low velocities. Setting the filter low and gain high may introduce color artefacts from normal structures and obscure genuine color flow maps.

Advantages

- The major advantage of color Doppler echo is the rapidity with which normal and abnormal flow patterns can be visualized and interpreted.
- The spatial orientation of color flow mapping is easier to comprehend for those not experienced in Doppler.

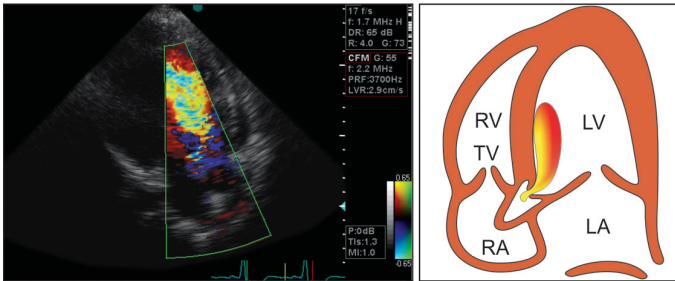


Fig. 3.4: Color flow map of a regurgitant aortic valve from A5CH view showing a mosaic jet

Conventional wave Doppler tracings have to be understood, before interpretation.

- Color Doppler improves the accuracy of sampling with pulsed-wave and continuous-wave Doppler by helping to align the Doppler beam with the color jet. This facilitates localization of valve regurgitation and intracardiac shunts.
- The phenomenon of aliasing, a disadvantage in pulsed-wave Doppler, is advantageous during color flow mapping. Introduction of color variance in the flow map is easily recognized as a mosaic pattern.

Limitations

- Like all other echo modalities, color Doppler may be limited by non-availability of a satisfactory echo window or by malalignment of the ultrasound beam with blood flow direction.
- As with pulsed-wave Doppler, color Doppler is sensitive to pulsed repetition frequency (PRF) of the transducer and the depth of the cardiac structure being interrogated.
- Color Doppler may inadvertently miss low velocities if the flow signal is weak. This occurs especially if the velocity filter setting is high and the color gain setting is low.

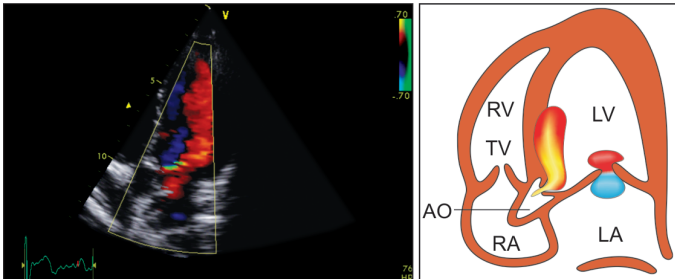


Fig. 3.5: Color flow map of the left ventricle from A5CH view showing artefacts from the IV septum and mitral leaflets

- Color Doppler may spuriously pick up artefacts from heart muscle and valve tissue which falsely get assigned a color. This occurs especially if the velocity filter setting is low and the color gain setting is high (Fig. 3.5).
- Complex cardiac lesions may produce a multitude of blood flows in a small area, in both systole and diastole. The result is a confusional riot of color, hindering rather than helping an accurate diagnosis.

APPLICATIONS OF COLOR DOPPLER

Stenotic Lesions

- Color Doppler can identify, localize and quantitate stenotic lesions of the cardiac valves. It visually displays the stenotic area and the resultant jet as distinct from normal flow.
- Stenosis of a valve produces a “candle-flame” shaped jet at the site of narrowing. The jet color assumes a mosaic pattern of aquamarine, green and yellow signifying increased velocity and turbulent flow (Fig. 3.6).
- The color Doppler signal has to be parallel to the direction of blood flow or else the degree of stenosis gets

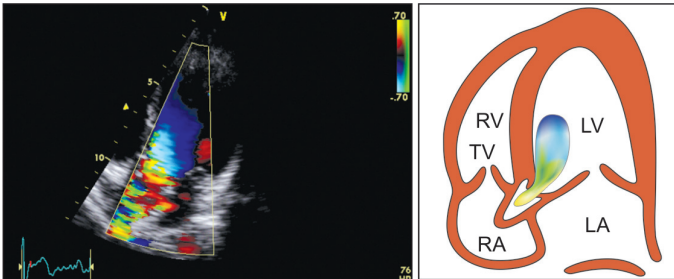


Fig. 3.6: Color flow map of stenotic aortic valve from A5CH view showing change in color to a mosaic pattern

underestimated. Angulation of the transducer to improve the Doppler signal, inadvertently skews and distorts the anatomical image.

- When there is calcification of the valve leaflets or annulus, the color flow display drops out of the image in the calcified area. Turning up the gain to image the calcified area causes blooming of both the anatomic image as well as the Doppler signal.
- It would be ideal to measure the stenotic orifice from the color Doppler view. However, this is practically difficult since anatomical measurement requires perpendicular beam orientation while the Doppler signal requires a parallel beam orientation.

Regurgitant Lesions

- Color Doppler can diagnose and estimate the severity of regurgitant lesions of the valves. It displays the regurgitant jet as a flow-map distinct from the normal flow pattern.
- A regurgitant valve produces a color flow map in the receiving chamber. For instance, mitral regurgitation results in a left atrial flow map while aortic regurgitation causes a flow map in the left ventricular outflow tract (Fig. 3.7).

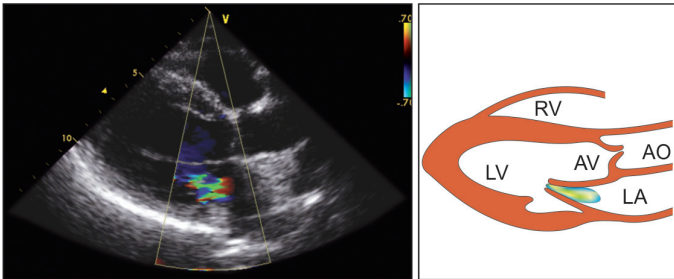


Fig. 3.7: Color flow map of a regurgitant mitral valve from PLAX view showing a jet in the left atrium

- A jet interrogated along its length produces a large flow area while scanning the same jet across reveals a smaller area. By using multiple views and windows for interrogation, the size and geometry of a pathological jet can be accurately estimated.
- It is necessary to angulate the transducer, in order to scan across the length and width of the chamber being studied. This will improve the detection of eccentric regurgitant lesions.
- Valvular regurgitation can be quantified by assessing the depth upto which color flow can be picked up. Mild regurgitation is confined to the valve plane while severe regurgitation can be mapped upto the distal portion of the receiving chamber.
- Measuring the absolute jet area and calculating the ratio of jet area to atrial size is also used to assess the degree of ventriculoatrial regurgitation.
- A ratio of less than 25% indicates mild, 25 to 50% suggests moderate and more than 50% represents severe valvular regurgitation.

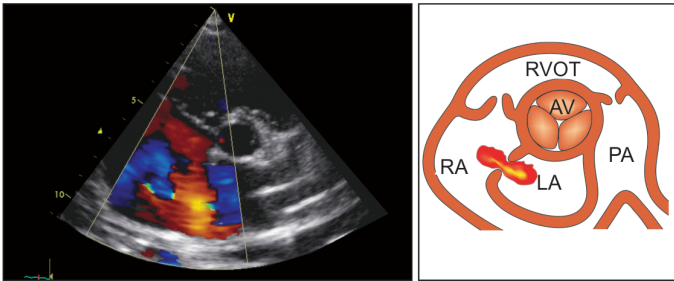


Fig. 3.8: Color flow map of an atrial septal defect from PSAX view showing a jet from the left atrium to right atrium

Intracardiac Shunts

- An atrial septal defect produces a mosaic color flow map crossing from the left atrium to the right atrium. Because of low velocity, the color map is sometimes missed (Fig. 3.8).
- A ventricular septal defect produces a mosaic color flow map extending from the left ventricle to the right ventricle across the septum. The width of the map approximates the size of the septal defect.
- A patent ductus arteriosus produces a retrograde mosaic color flow map extending from the descending aorta to the pulmonary artery.



4

The Echo Windows

TRANSTHORACIC ECHO

- Conventional echocardiography is performed from the anterior chest wall (precordium) and is known as transthoracic echo.
- Echocardiography can also be performed from the esophagus which is known as transesophageal echo.
- For transthoracic echo, the subject is asked to lie in the semirecumbent position on his or her left side with the head slightly elevated.
- The left arm is tucked under the head and the right arm lies along the right side of the body.
- This position opens the intercostal spaces through which echocardiography can be performed, while most of the heart is masked from the ultrasound beam by the ribs.
- Better images are obtained during expiration when there is least 'air-tissue' interface.
- Ultrasound is transmitted from a transducer having a frequency of 2.5 to 3.5 MHz for echo in adults.
- This frequency is used to study deep seated structures because of better penetration.

- A transducer frequency of 5.0 MHz is suitable for pediatric echo, since the heart is more superficial in children.
- Ultrasound jelly is applied on the transducer and it is placed on the chest at the site of an “echo window”.
- Most of the time, the left parasternal and apical windows are routinely used.
- The transducer has a reference line or dot on one side, in order to orient it in the correct direction, for obtaining various echo views.
- The transducer is variably positioned, in terms of location and direction, for different echo images.
- It can be tilted (superiorly or inferiorly), to bring into focus the structure of interest and rotated (clockwise or anticlockwise), to fine-tune the image.

STANDARD ECHO WINDOWS

- Standard locations on the anterior chest wall are used to place the transducer, which are called “echo windows” (Fig. 4.1). These are:
 - left parasternal
 - apical

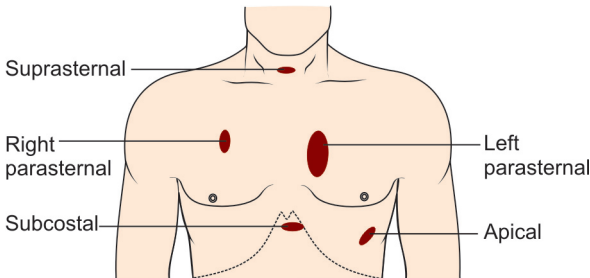


Fig. 4.1: The standard “windows” used during echocardiography

- subcostal
 - right parasternal
 - suprasternal.
- Standard windows are important for two reasons:
 - penetration of ultrasound waves from windows is good, without much masking of image or absorption of ultrasound by ribs and lungs.
 - standardized echo images can be compared with studies performed by different observers or on different occasions by the same observer.
 - Transthoracic echo may be technically difficult to perform in the following situations:
 - severe morbid obesity
 - chest wall deformity
 - pulmonary emphysema.

Parasternal Long-Axis View (PLAX View) (Fig. 4.2)

- Transducer position: left sternal edge; 2nd–4th space
- Marker dot direction: points towards right shoulder.

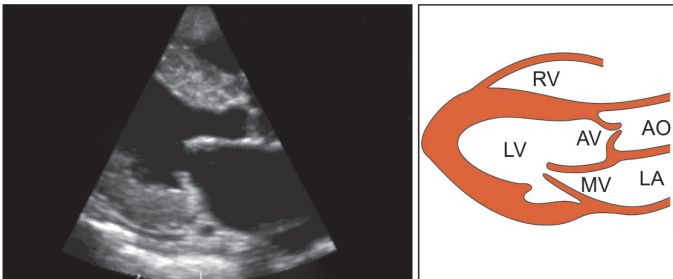


Fig. 4.2: The parasternal long-axis (PLAX) view

Structures seen:

- proximal aorta
 - aortic valve
 - left atrium
 - mitral valve
 - left ventricle
 - IV septum
 - posterior wall
 - right ventricle
 - pericardium.
- Most echo studies begin with this view. It sets the stage for subsequent echo views.

Parasternal Short-Axis Views (PSAX Views) (Fig. 4.3)

- Transducer position: left sternal edge; 2nd–4th space
- Marker dot direction: points towards left shoulder (90° clockwise from PLAX).
- By tilting the transducer on an axis between the left hip and right shoulder, short-axis cuts are obtained at different levels, from the aorta to the LV apex (Fig. 4.3).
- This angulation of the transducer from the base to apex of the heart for short-axis views is known as “bread-loafing”.

Short Axis Levels (Fig. 4.3)

1. pulmonary artery
2. aortic valve level
3. mitral valve level
4. papillary muscle
5. left ventricle.

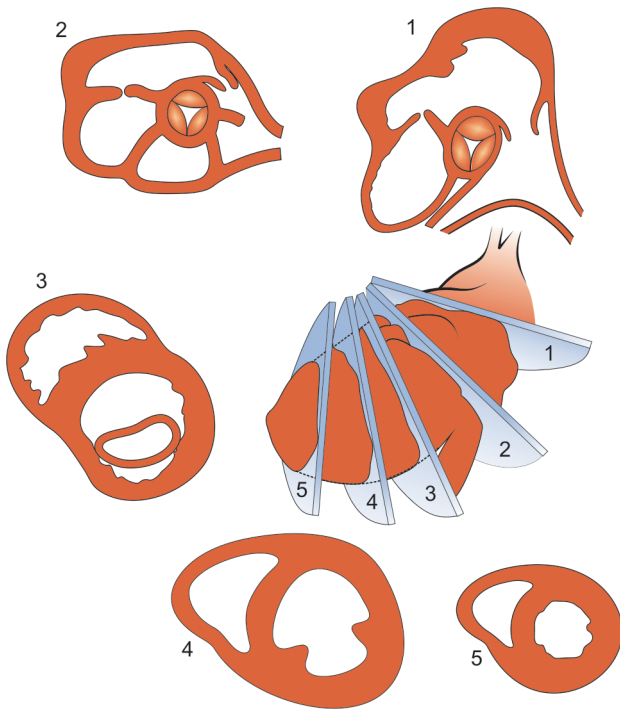


Fig. 4.3: The parasternal short-axis (PSAX) views

Pulmonary Artery (PA) Level (Fig. 4.4)

Structures seen:

- pulmonary artery
- pulmonary valve
- RV outflow tract.

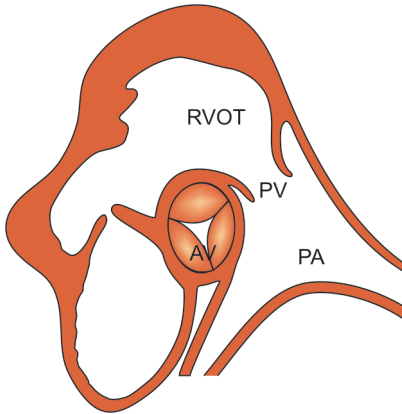


Fig. 4.4: PSAX view: pulmonary artery (PA) level

Aortic Valve (AV) Level (Fig. 4.5)

Structures seen:

- aortic valve cusps
- left atrium

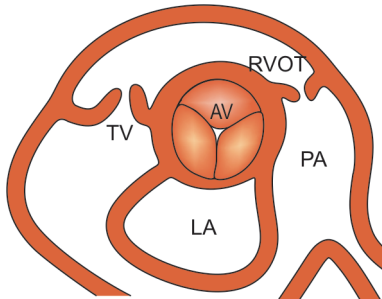


Fig. 4.5: PSAX view: aortic valve (AV) level

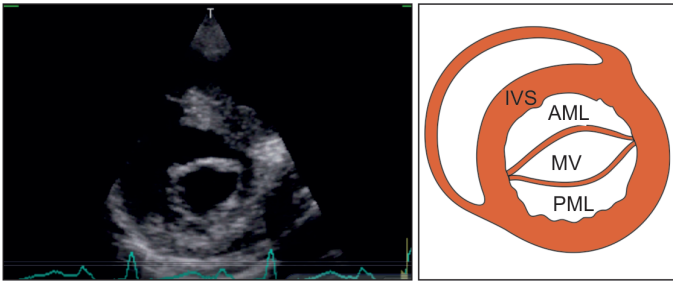


Fig. 4.6: PSAX view: mitral valve (MV) level

- interatrial septum
- tricuspid valve
- RV outflow tract.

Mitral Valve (MV) Level (Fig. 4.6)

Structures seen:

- mitral valve orifice
- mitral valve leaflets
- ventricular septum

Papillary Muscle (PM) Level (Fig. 4.7)

Structures seen:

- anterolateral PM (3°)
 - posteromedial PM (7°)
 - anterior wall (12° to 3°)
 - lateral wall (3° to 6°)
 - inferior wall (6° to 9°)
 - IV septum (9° to 12°)
- For apical views, the subject turns back rightwards from the left lateral position and lies more supine.

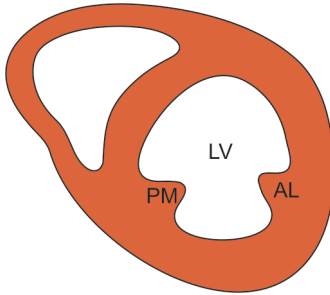


Fig. 4.7: PSAX view: papillary muscle (PM) level

Apical 4-Chamber View (A4CH View) (Fig. 4.8)

- Transducer position: apex of the heart
- Marker dot direction: points towards left shoulder.

Structures seen:

- right and left ventricle
- right and left atrium
- mitral, tricuspid valves

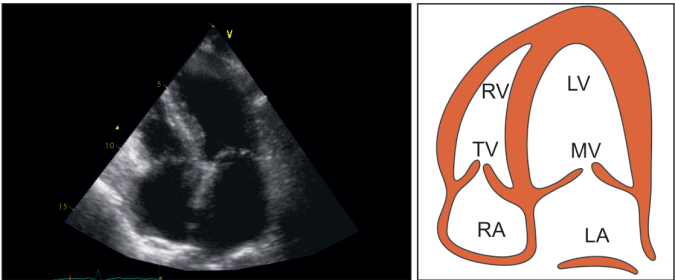


Fig. 4.8: Apical 4-chamber (A4CH) view

- IA and IV septum
- left ventricular apex
- lateral wall left ventricle
- free wall right ventricle.

Apical 5-Chamber View (A5CH view) (Fig. 4.9)

- The A5CH view is obtained after the A4CH view by slight downward tilting of the transducer. The 5th chamber added is the left ventricular outflow tract (LVOT).
- Transducer position: as in A4CH view.
- Marker dot direction: as in A4CH view.

Structures seen:

As in A4CH view. Additionally:

- LV outflow tract
- aortic valve
- proximal aorta.

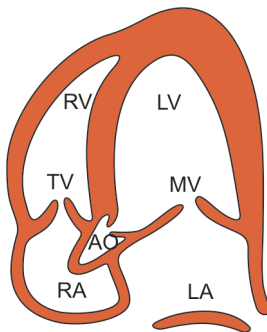


Fig. 4.9: Apical 5-chamber (A5CH) view

Subcostal View

- For subcostal view, the position of the subject is different from that used to obtain parasternal and apical views.
- The subject lies supine with the head held slightly low, feet planted on the couch and the knees slightly flexed.
- Better images are obtained with the abdomen relaxed and during the phase of inspiration.
- Transducer position: under the xiphisternum
- Marker dot position: points towards left shoulder.

Structures seen:

As in A4CH view.

- The subcostal view is particularly useful when transthoracic echo is technically difficult because of the following reasons:
 - severe morbid obesity
 - chest wall deformity
 - pulmonary emphysema.
- The following structures are better seen from the subcostal view than from the apical 4-chamber view:
 - inferior vena cava
 - descending aorta
 - interatrial septum
 - pericardial effusion.

Suprasternal View

- For suprasternal view, the subject lies supine with the neck hyperextended by placing a pillow under the shoulders. The head is rotated slightly towards the left.
- The position of arms or legs and the phase of respiration have no bearing on this echo window.
- Transducer position: suprasternal notch.
- Marker dot direction: points towards left jaw.

Structures seen:

- ascending aorta
- pulmonary artery.

Right Parasternal View

- For right parasternal view, the subject lies in the semi-recumbent position on the right side. The right arm is tucked under the head and the left arm lies along the left side of the body.
- In other words, this position is the mirror-image of that used for the left parasternal view.
- Transducer position: right sternal edge; 2nd–4th space
- Marker dot direction: points towards left shoulder.

Structures seen:

- aortic valve
- aortic root.

TRANSESOPHAGEAL ECHO

Principle

- During echocardiography, a balance has to be struck between tissue penetration and image resolution. Low frequency transducers have good penetration (less attenuation) but relatively poor resolution. On the other hand, high frequency transducers have poor penetration (more attenuation) but better resolution.
- Anatomically speaking, the esophagus in its mid-course is strategically located posterior to the heart and anterior to the descending aorta. This provides an opportunity to interrogate the heart and related mediastinal structures with a high frequency transducer positioned in the esophagus for better image resolution.
- The technique is known as transesophageal echocardiography or simply TEE.

Technique

- A miniature transducer is mounted onto a probe or gastroscope similar to the one employed for upper gastrointestinal endoscopy. The scope is advanced to various depths in the esophagus to examine cardiac and related structures. By manoeuvring the transducer and the angle of beam from controls on the handle, different views of the heart are obtained.
- This 'back-door' approach to echocardiography has both advantages and disadvantages.

Advantages

- Useful alternative to transthoracic echo if the latter is technically difficult due to obesity, chest wall deformity, emphysema or pulmonary fibrosis.
- Useful complement to transthoracic echo because of better image quality and resolution due to two reasons:
 - absence of acoustic barrier between the ultrasound beam and the rib cage, chest wall and lung tissue.
 - greater proximity to the heart and therefore the ability to use higher frequency probe with vastly improved image quality and precise spatial resolution.
- Useful supplement to transthoracic echo, which cannot examine the posterior aspect of the heart. Structures such as left atrial appendage, descending aorta and pulmonary veins can only be visualized by TEE.

Disadvantages

- It is a semi-invasive procedure which is uncomfortable to the patient, more time consuming and carries a small risk of serious complications such as oropharyngeal or esophageal trauma, cardiac arrhythmias and laryngo-bronchospasm (Table 4.1).

TABLE 4.1**Complications with TEE***Major*

- Esophageal rupture or perforation
- Laryngospasm or bronchospasm
- Sustained ventricular tachycardia

Minor

- Retching and vomiting
- Sore-throat and hoarseness
- Blood-tinged sputum
- Tachycardia or bradycardia
- Hypoxia and ischemia
- Transient BP rise or fall

- It requires short-term sedation, oxygen administration and ECG monitoring since, there are chances of hypoxia, arrhythmia and angina. Rarely, respiratory depression or allergic reactions may occur.
- TEE is contraindicated in the presence of active bleeding or coagulopathy, esophageal abnormalities, unstable cervical arthritis and poor cardiopulmonary status (Table 4.2).
- The transesophageal echo (TEE) views are significantly different from standard transthoracic echo views. Novel TEE images require a comprehensive understanding of the spatial relationship between cardiac structures.

It would be beyond the scope and against the philosophy of this book to understand and learn these views in detail. Nevertheless, the indications for TEE are duly mentioned at appropriate places, in several chapters of the book.

TABLE 4.2**Contraindications to TEE***Absolute*

- Uncooperative patient
- Poor cardiorespiratory status
- Esophageal obstruction
- Tracheoesophageal fistula
- Active bleed or coagulopathy

Relative

- Large esophageal varices
- Prior esophageal surgery
- Unstable cervical arthritis
- Atlantoaxial dislocation

FUTURE DIRECTIONS IN ECHO**Three-Dimensional Echo**

- Two-dimensional echocardiography (2-D echo) provides a 2-D view of the 3-D heart. Therefore, a series of integrated 2-D views are required to mentally construct a three-dimensional (3-D) image of the structure of the heart.
- To accurately perform this task, knowledge of the precise relationship of each 2-D image with the other is vital but not always feasible.
- For instance, while quantifying cardiac chamber volume and function with 2-D echo, one makes certain assumptions about cardiac geometry to apply specific formulae for calculations.
- As chambers get distorted in shape by infarction and remodeling, these geometric assumptions lose their accuracy as do the calculated values from formulae.
- Three-dimensional echocardiography (3-D echo) obviates the need for cognitive 3-D reconstruction of 2-D image planes

and the compulsion of making geometric assumption about the shape of cardiac structures for quantification.

- Besides its application in ventricular volumetric assessment, 3-D echo is particularly useful to study asymmetrical stenotic valve orifices, eccentric regurgitant jets picked up by color Doppler and complex structural relationships observed in congenital heart diseases.
- The 3-D echo can be viewed from various projections by rotation of the images, to enhance the appreciation of structural relationships.
- Three-dimensional echocardiography (3-D echo) has the potential to reduce the time required for complete cardiac image acquisition.
- As computer hardware and software matures and transducer technology evolves, time and labor-intensive offline image reconstruction will soon be replaced by real-time image acquisition.
- Three-D echo therefore has the potential to move from being merely a research tool to being used extensively in the clinical arena.

Myocardial Contrast Echo

- Myocardial contrast echocardiography involves the application of an ultrasonic contrast agent, to accurately delineate areas of reduced myocardial blood flow or perfusion defects related to coronary occlusion.
- The contrast agent exists as microbubbles which are produced either by electromechanical sonication or by lipid encapsulation.
- Myocardial contrast imaging has the ability to enhance qualitative as well as quantitative information pertaining to myocardial perfusion.

- In the emergency setting, contrast imaging provides incremental prognostic information in patients who have resting abnormalities in regional wall motion.
- Patients of acute coronary syndrome with both abnormal wall motion and abnormal perfusion have worse event-free survival when compared to patients with normal myocardial perfusion.
- In the acute setting, contrast imaging can identify patients with the “no-reflow” phenomenon which is characterized by lack of recovery in microvascular perfusion despite successful opening of the occluded coronary artery by intervention or thrombolysis.
- The long-term prognosis of these “no-reflow” patients is adverse and they are observed to have significant deterioration in regional and global systolic function at follow-up.
- In the chronic setting, contrast imaging can also identify viability of the perfusion bed subtended by the occluded coronary artery, when contrast injection into an adjacent coronary artery produces enhancement.
- This is clinically relevant because revascularization after myocardial infarction results in improved function only when viable myocardium is demonstrable.
- Finally, during exercise or dobutamine stress echocardiography, real-time assessment of myocardial perfusion improves the sensitivity of the test in detecting angiographically significant stenosis, compared to wall motion analysis alone.

Tissue Doppler Imaging

- During day-to-day echocardiography, left ventricular function is routinely evaluated by two-dimensional (2-D) and motion-mode (M-mode) techniques.
- However, visual evaluation of LV function using these modalities suffers from the limitations of being significantly subjective and provides only semi-quantitative data.

- Moreover, visual assessment has limited ability to detect subtle changes in LV function and in timing of wall motion, throughout entire systole and diastole.
- Tissue Doppler imaging is a more objective and highly quantitative method to accurately assess regional and global left ventricular systolic and diastolic function.
- This technique can measure a variety of myocardial functional parameters which include tissue velocity, acceleration, displacement and strain rate.
- Tissue Doppler imaging has been used as a diagnostic tool in specific situations including assessment of myocardial ischemia, evaluation of diastolic dysfunction and differentiation between restrictive cardiomyopathy and constrictive pericarditis.
- Myocardial ischemia is diagnosed by velocity imaging as reduced systolic ejection velocity and higher postsystolic shortening velocity. Findings on strain imaging are reduced systolic shortening along with systolic lengthening.
- Heart failure with preserved ejection fraction (HFPEF) accounts for a significant chunk of heart failure patients particularly in the elderly population.
- These patients have isolated or predominant diastolic heart failure allowing for the fact that ejection fraction (EF) may fail to identify mild systolic dysfunction.
- Additionally, there are patients who do not have heart failure but have impaired diastolic function such as patients with systemic hypertension and diabetes mellitus.
- The characteristic findings in diastolic dysfunction observed by tissue Doppler imaging is reduced early diastolic mitral annulus velocity, which correlates with peak LV lengthening velocity.

- This abnormality is observed across the entire range of diastolic dysfunction from impaired relaxation (reduced E/A ratio) through pseudo-normal filling (normal E/A ratio) to restrictive filling (increased E/A ratio).
- Patients with constrictive pericarditis have normal systolic function and ventricular relaxation while those with restrictive cardiomyopathy have impairment of both parameters.
- Therefore, reduced early diastolic mitral annulus velocity is more indicative of restrictive cardiomyopathy whereas there is substantial overlap in transmitral filling velocities between these patients, those with constrictive pericarditis and even normal subjects.



5

Normal Views and Values

ECHO INTERPRETATION

- The echocardiogram provides a substantial amount of structural and functional information about the heart. While still frames provide anatomical detail, dynamic images tell us about physiological function.
- Echocardiography is quite easy to understand, since many echo features are based upon simple physical facts and physiological principles.
- Nevertheless, the value of information derived from echo depends heavily upon who has performed the study. The quality of an echo is highly operator dependent and proportional to his experience and skill.
- The abnormal can only be viewed in the light of the normal. Therefore, it is important to appreciate normal echo images and to be familiar with normal dimensions.

SCANNING SEQUENCE

A suggested schematic for a systematic and detailed echocardiography study is as follows:

- Start with the parasternal long-axis view.

- Make M-mode recording at these 3 levels:
 - level of aortic valve
 - level of mitral valve
 - level of left ventricle.
- Rotate the transducer by 90° clockwise. Angulate it from the base to apex to obtain short-axis views at these 4 levels:
 - pulmonary artery level
 - aortic valve level
 - mitral valve level
 - papillary muscle level.
- Go on to the apical 4-chamber view. Measure ventricular volumes in systole and diastole (to assess LV systolic function).
- Turn on the color flow mapping for abnormal flow patterns due to valvular diseases or septal defects.
- Place the pulsed wave (PW) Doppler 'sample volume' in the LV cavity at the tips of MV leaflets in the diastolic position (to assess LV diastolic function).
- Angulate the transducer anteriorly to obtain the apical 5-chamber view. Place the 'sample volume' in the aortic valve to obtain the flow velocity integral (FVI). Calculate the stroke volume and from it the cardiac output.
- Use continuous wave (CW) Doppler to scan the apical 4-chamber view for high velocity signal, if abnormal flow is observed on color flow mapping.
- Use pulsed wave (PW) Doppler to localize an abnormal flow seen on color flow mapping or a high velocity signal picked on CW Doppler.
- Use other echo windows (subcostal, suprasternal and right parasternal) as and when indicated.
- Rotate the transducer by 45° anticlockwise and obtain the apical 2-chamber view.

WHAT IS NORMAL?

It must be borne in mind that normal value ranges of echo-derived dimensions, depend upon several factors. These factors include height, sex, age and the level of physical activity.

Normal values are higher in these subjects:

- male gender
- tall persons
- trained athletes
- elderly patients.

Therefore, correction for these factors is made by indexing cardiac dimensions to body surface area (BSA) using the formula:

$$BSA(m^2) = \sqrt{\frac{\text{height(cm)} \times \text{weight(kg)}}{3600}}$$

Normal dimensions are estimated from small populations of 'average' persons and may not apply to unusually small or tall subjects, to the elderly or to athletes.

NORMAL VARIANTS

Some findings on echo may be normal and must be carefully understood to avoid overdiagnosis of heart disease (Fig. 5.1).

Normal Structures

- Moderator band in the apical one-third of the right ventricle, parallel to the plane of the tricuspid valve.
- False tendon in the left ventricle, extending between the lateral papillary muscle and the IV septum.
- Eustachian valve in the right atrium, guarding the opening of the inferior vena cava.
- Reverberation artefact in the left atrium, from calcific mitral annulus or prosthetic aortic valve.

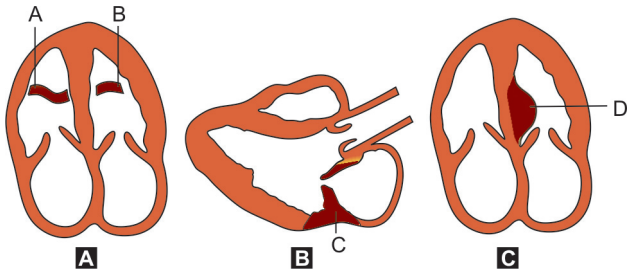


Fig. 5.1: Normal structural variants seen on echo:
 A. Moderator band in right ventricle
 B. False tendon in the left ventricle
 C. Mitral annular ring calcification
 D. Subaortic bulge of IV septum

Normal Flow Patterns

- Trivial tricuspid regurgitation is observed in many subjects.
- Minimal mitral regurgitation is observed in some subjects
- Aortic regurgitation is observed only from diseased valves.

Normal Findings in Elderly

- Mild thickening of aortic valve leaflets (misdiagnosed as aortic valve stenosis).
- Mitral annular ring calcification with regurgitation (misdiagnosed as vegetation or thrombus).
- Reduced LV compliance, A/E ratio > 1 on Doppler (misdiagnosed as LV diastolic dysfunction).
- Localized subaortic bulge of ventricular septum (misdiagnosed as septal hypertrophy or HOCM).

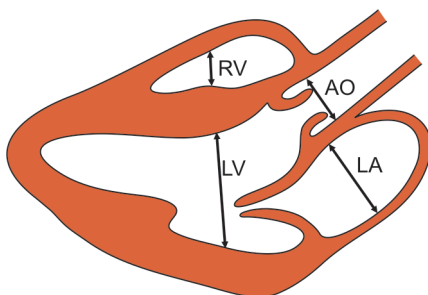


Fig. 5.2: Measurement of dimensions from PLAX view

NORMAL DIMENSIONS

- Most echo studies begin with the parasternal long-axis (PLAX) view. It sets the stage for subsequent echo views.
- Traditionally, dimensions are measured using M-mode scan which has better resolution than 2-D echo.
- However, despite this theoretical advantage, M-mode imaging may be inaccurate unless the cursor is placed perpendicular to the structure being measured. Practically speaking, this is not always possible.
- In that case, measurements can instead be made from the 2-D image of PLAX view (Fig. 5.2).
- An experienced echocardiographer can often give a reasonably good visual assessment of LV systolic function from the PLAX view without actual measurements.
- However, this rough assessment may be unreliable for serial evaluation of LV function and when LV volumes critically influence the timing of a surgical intervention.
- The PLAX view gives a good visual impression of the motion of the interventricular septum (IVS) and the left ventricular posterior wall (LVPW) (Fig. 5.3).

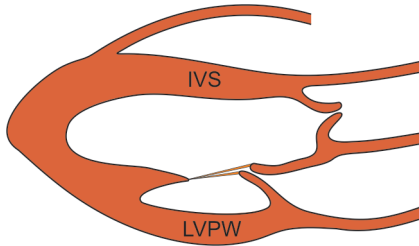


Fig. 5.3: Motion of IVS and LVPW seen on PLAX view

Parasternal Long-Axis View (PLAX View)

The PLAX view is used to measure the dimensions of the aortic annulus, sinus of Valsalva, aortic root and the anterior aortic swing (Fig. 5.4).

Aortic annulus	17–25 mm
Sinus of Valsalva	22–36 mm
Sinotubular junction	18–26 mm

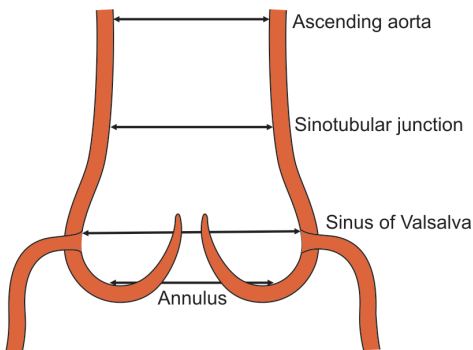


Fig. 5.4: Dimensions of proximal aorta from PLAX view

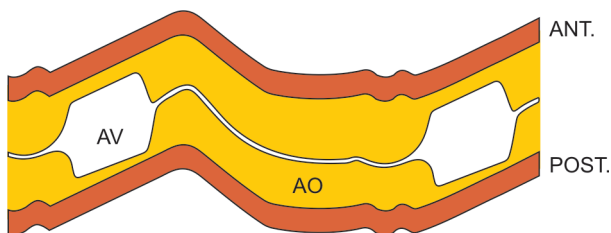


Fig. 5.5: M-mode scan PLAX view; aortic valve level

Aortic root (tubular)	20–37 mm
Anterior aortic swing	7–15 mm
Aortic valve orifice area	2.5–3.5 cm ²

M-Mode Scan PLAX View

Aortic Valve Level (Fig. 5.5)

Aortic root diameter	20–37 mm
Aortic cusp separation	15–26 mm
Left atrial diameter	19–40 mm

Mitral Valve Level (Fig. 5.6)

AML D-E excursion	20–35 mm
AML E-F slope	18–120 mm/sec
E point to septum	less than 5 mm

Note

- The diameter of the aortic root is measured between the leading edges of the anterior and posterior aortic walls.
- The diameter of the left atrium is measured between the leading edges of the anterior and posterior atrial walls.

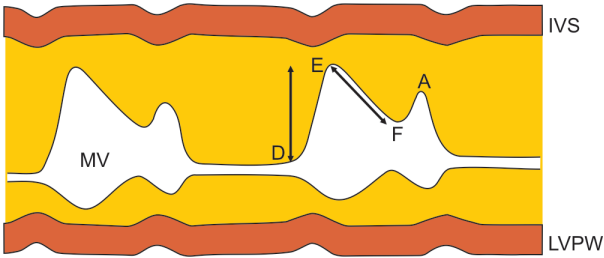


Fig. 5.6: M-mode scan PLAX view; mitral valve level

Ventricular Level (Fig. 5.7)

IV-septal thickness (diastolic)	6–12 mm
Posterior wall thickness (diastolic)	6–11 mm
IV-septal excursion (systolic)	6–9 mm
Posterior wall excursion (systolic)	9–14 mm
LV diameter end-diastolic (LVEDD)	36–52 mm
LV diameter end-systolic (LVESD)	24–42 mm
RV internal dimension	7–23 mm
RV free-wall thickness	< 5 mm
LV fractional shortening	30–45%
LV ejection fraction	50–75%

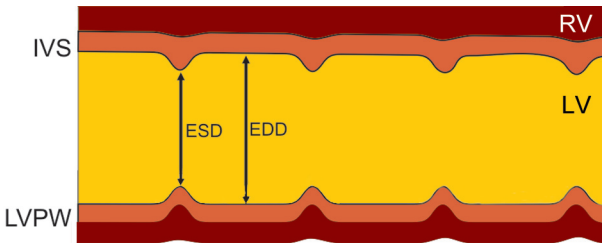


Fig. 5.7: M-mode scan PLAX view; ventricular level

Note

- The dimensions of the left ventricle are measured just below the free edge of the anterior mitral leaflet.
- This standard level is important in order to compare serial studies performed on different occasions.

Parasternal Short-Axis View (PSAX View)*Pulmonary Artery Level*

Pulmonary artery diameter	18–15 mm
Pulmonary outflow velocity	0.5–1.0 m/sec (mean 0.75 m/sec)

Aortic Valve Level

Aortic root dimension	20–37 mm
Left atrial diameter	19–40 mm

Mitral Valve Level

Mitral valve orifice	4–6 cm ²
----------------------	---------------------

Apical 4-Chamber View (A4CH View)

LV volume end-diastolic	85 ± 15 ml/m ²
LV volume end-systolic	35 ± 5 ml/m ²
Mitral inflow velocity	0.6–1.4 m/sec (mean 0.9 m/sec)
Tricuspid inflow velocity	0.3–0.7 m/sec (mean 0.5 m/sec)

Apical 5-Chamber View (A5CH View)

Aortic outflow velocity	0.9–1.8 m/sec (mean 1.3 m/sec)
Stroke volume	32–48 ml/beat/m ²
Cardiac output	2.4–4.2 L/min/m ²

NORMAL VALVES

Mitral Valve

- The mitral valve consists of 2 leaflets:
 - anterior mitral leaflet (AML).
 - posterior mitral leaflet (PML).
- Motion of both the leaflets is visualized by M-mode scanning from the PLAX view.
- The excursion of the AML can be divided into the following waves and slopes (Fig. 5.8):

E-wave : Anterior and posterior motion during entire diastole.

D-E slope : Anterior motion during rapid diastolic filling.

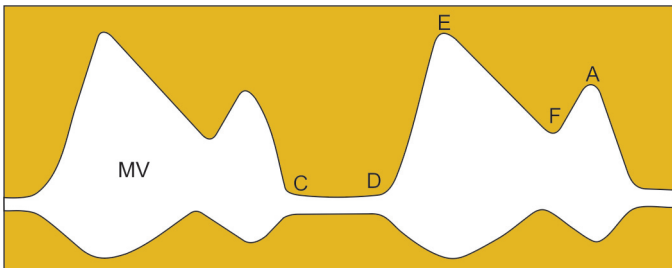


Fig. 5.8: M-mode tracing of the mitral valve

- E-F slope : Posterior motion during end-diastolic relaxation.
- A-wave : Anterior motion during atrial systolic contraction
- The amplitude of motion of the PML is less than that of the AML and in an opposite direction.

Tricuspid Valve

- The tricuspid valve consists of 3 leaflets:
 - large anterior leaflet (ATL),
 - small septal leaflet (STL)
 - tiny posterior leaflet (PTL).
- The ATL motion is visualized by M-mode scanning from the PLAX view in the right ventricle, anterior to the IV septum.
- The excursion of the ATL is very similar to that of the AML of mitral valve described above (Fig. 5.9).
- The STL is only recorded when there is dilatation of the right ventricle or clockwise rotation due to emphysema.

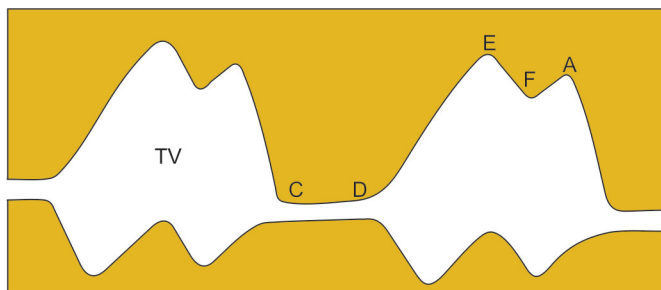


Fig. 5.9: M-mode tracing of the tricuspid valve

- The amplitude of motion of the STL is less than that of the ATL and in a direction opposite to ATL excursion.
- The PTL is not visualized on M-mode tracing.

Aortic Valve

- The aortic valve consists of 3 cusps:
 - anterior right coronary cusp (RCC)
 - posterior non-coronary cusp (NCC)
 - middle left coronary cusp (LCC).
- The RCC and NCC are visualized by M-mode scanning from the PLAX view (Fig. 5.10).
- During systole, the anterior and posterior cusps move away from each other and towards the anterior and posterior aortic walls respectively.
- This creates a box-like systolic opening of the valve, in the shape of a parallelogram.
- During diastole, the cusps oppose to form a central closure line in the aortic lumen. The closure line is equidistant from the anterior and posterior aortic walls.

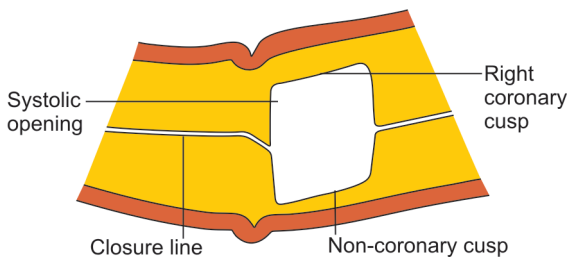


Fig. 5.10: M-mode tracing of the aortic valve

Pulmonary Valve

- The pulmonary valve consists of 3 cusps:
 - posterior (left) cusp
 - anterior cusp
 - right cusp.

The only cusp usually recorded by M-mode scanning from the PLAX view is the posterior (left) cusp (Fig. 5.11).

- The anterior and right cusps are infrequently visualized due to obliquity of the valve to the ultrasound beam.
- The excursion of the posterior pulmonary leaflet can be divided into the following slopes (Fig. 5.11):
 - B-C slope : systolic opening motion
 - C-D slope : open valve during systole
 - D-E slope : systolic closing motion
 - E-F slope : diastolic posterior motion.

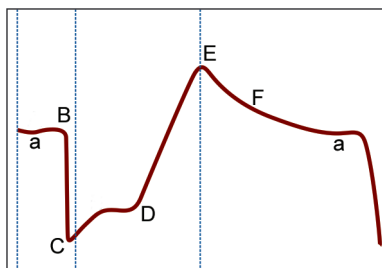


Fig. 5.11: M-mode tracing of the pulmonary valve



6

Ventricular Dysfunction

Assessment of ventricular function, particularly of the left ventricle, is the most common and the most important application of echocardiography. Presence of left ventricular dysfunction is a reliable prognostic indicator in all forms of cardiac disease. It has important therapeutic implications and many a time, clinical management is altered when an abnormality of ventricular function is detected.

Ventricular dysfunction can be classified as:

- Left ventricular systolic dysfunction
- Left ventricular diastolic dysfunction
- Right ventricular dysfunction.

LV SYSTOLIC DYSFUNCTION

In order to understand LV systolic dysfunction, it is important to know the normal indices of left ventricular function.

Normal Indices

LV wall thickness in diastole

6–12 mm interventricular septum (IVS)

6–11 mm LV posterior wall (LVPW)

LV wall excursion in systole

3–8 mm interventricular septum (IVS)

9–14 mm LV posterior wall (LVPW)

LV internal dimension

24–42 mm at end-systole (LVESD)

36–52 mm at end-diastole (LVEDD)

LV internal volume

35 ± 5 ml at end-systole (LVESV)

85 ± 15 ml at end-diastole (LVEDV)

Fractional shortening 30–45%

(% change in LV dimension)

LV ejection fraction 50–75%

(% change in LV volume)

Echo Features of LV Systolic Dysfunction

M-Mode LV Level

- During ventricular systole, the interventricular septum (IVS) and the left ventricular posterior wall (LVPW) move towards each other.
- The amplitude of this motion is reduced in the presence of LV systolic dysfunction (Fig. 6.1).
- LV internal dimension in end-systole (LVESD) and end-diastole (LVEDD) are measured on the M-mode tracing in the parasternal long-axis view (PLAX), at the level of mitral valve (MV) leaflet tips.
- Measurements are taken from the endocardial lining of the septum (IVS) to that of the posterior wall (LVPW).
- LV dimensions are increased in the presence of left ventricular systolic dysfunction.

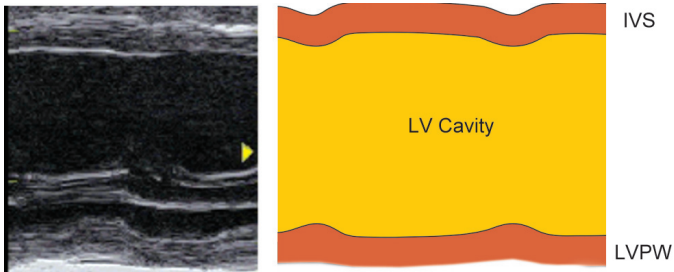


Fig. 6.1: M-mode scan of the left ventricle showing:
 A. Reduced excursion of IVS and LVPW
 B. Increased dimension of the LV cavity

- The percentage change in LV internal dimension between systole and diastole is called fractional shortening (FS).

$$FS = \frac{LVEDD - LVESD}{LVEDD} \times 100\%$$

The normal range of fractional shortening is 30–45%.

- Reduced fractional shortening is an indicator of systolic dysfunction of the left ventricle.
- However, in the presence of regional wall motion abnormality, fractional shortening does not reliably reflect the overall LV systolic performance.
- The normal volume of the left ventricle during end-diastole (LVEDV) is 85 ± 15 ml.
- A volume greater than 100 ml is indicative of LV systolic dysfunction due to myocardial disease (cardiomyopathy or myocardial infarction) or because of volume overload (mitral or aortic regurgitation).

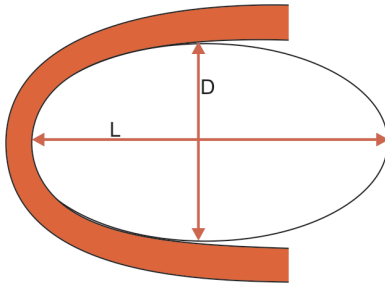


Fig. 6.2: Simulation of left ventricle cavity as an ellipsoid. Major axis (L) is twice the minor axis (D). LV volume = D^3 by the cubed equation.

- The LV volume is derived from the 'Cubed equation'
 $V = D^3$ V: volume; D: diameter
- This equation is based on the assumption that the LV cavity is ellipsoid in shape and the major axis is twice the minor axis (Fig. 6.2). But this is not always true.
- The LV volume derived from the Teicholz equation gives a more realistic and accurate measurement

$$V = \frac{7}{2.4 + D} \times D^3$$

- Measurement of LV dimensions can be unreliable if septal motion is abnormal due to old infarction, left bundle branch block or RV volume overload.
- The percentage change in LV volume between systole and diastole is called ejection fraction (EF):

$$EF = \frac{LVEDV - LVESV}{LVEDV} \times 100\%$$

The normal range of ejection fraction is 50 to 75%.

- Reduced ejection fraction is an indicator of LV systolic dysfunction. However, the ejection fraction also depends upon ventricular loading (preload and afterload).
- The normal diastolic thickness of the left ventricular walls, that is interventricular septum (IVS) and left ventricular posterior wall (LVPW), is 6 to 12 mm.
- Walls thinner than 6 mm indicate stretching due to cardiomyopathy or scarring due to myocardial infarction.
- Walls thicker than 12 mm indicate the presence of left ventricular hypertrophy.
- Normally, the walls should thicken in systole. Reduced systolic thickening of walls indicates presence of LV systolic dysfunction, either global (cardiomyopathy) or regional (myocardial infarction).

2-D Echo A4CH View

- 2-D echo can also be used to estimate LV volume in end-diastole (LVEDV) and end-systole (LVESV).
- This is done by tracing the LV endocardial borders of a systolic and a diastolic LV frame while the software of the echo machine calculates the LV volumes.
- From these volumes, the ejection fraction (EF) is calculated:

$$EF = \frac{LVEDV - LVESV}{LVEDV} \times 100\%$$

- The above method of calculating LV volume relies on manual tracing of the ventricular endocardial outline. Alternatively, LV volume can be calculated totally by the computer using the Simpson's method.

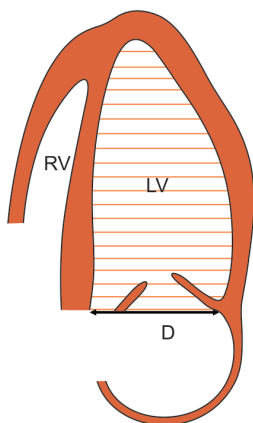


Fig. 6.3: Estimation of the left ventricular volume by Simpson's method; D is LV diameter

- By this method, the left ventricle is divided into 20 sections of equal thickness. The computer takes multiple short-axis slices at different levels (Fig. 6.3). The volume of each slice is the area multiplied by its thickness. The sum of volumes of all slices is the volume of the left ventricle.

$$\text{Area of each slice} = \pi (D/2)^2$$

D is diameter

$$\text{Thickness of slice} = 1/20 \times \text{LV}$$

LV is length

$$\text{Volume of each slice} = \text{Area} \times \text{Thickness}$$

$$\text{Left ventricle volume} = \text{Sum of all volumes}$$

- The cardiac output can also be obtained using LV volumes by the following simple calculations:

$$\text{Stroke volume (SV)} = \text{LVEDV} - \text{LVESV}$$

$$\text{Cardiac output (CO)} = \text{SV} \times \text{Heart rate (HR)}$$

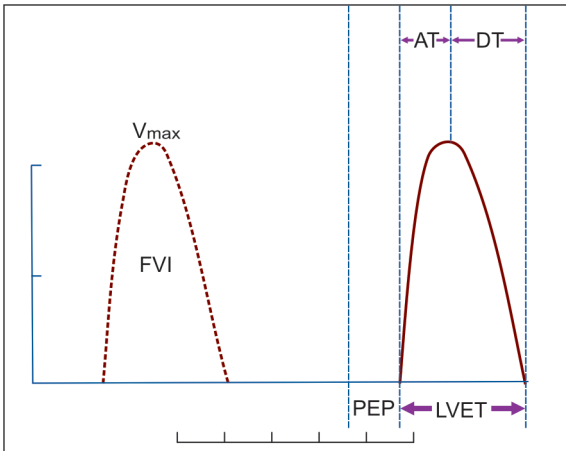


Fig. 6.4: Calculation of the cardiac output from peak aortic flow velocity (V_{max})

- | | |
|------------------------------|------------------------|
| FVI = flow velocity integral | AT = acceleration time |
| PEP = pre-ejection period | DT = deceleration time |
| LVET = LV ejection time | |

Doppler Echo

- The cardiac output as an indicator of LV systolic function can be calculated from the peak aortic flow velocity (V_{max}). This is obtained by Doppler display of aortic outflow from the apical 5 chamber (A5CH) view (Fig. 6.4).
- Continuous wave (CW) Doppler is used to measure higher velocities and pulse wave (PW) Doppler for lower velocities. PW Doppler provides a better spectral tracing.
- Before going into calculations of cardiac output, one must know the normal indices of ventricular ejection:

$$\text{Stroke volume} = 32\text{--}48 \text{ ml/beat/m}^2$$

$$\text{Cardiac output} = 2.8\text{--}4.2 \text{ L/min/m}^2$$

Doppler Calculations

Cardiac output = SV × HR

SV : stroke volume

HR : heart rate

Stroke volume = CSA × FVI

CSA: cross-sectional area

FVI : flow velocity integral

$$CSA = \pi r^2 = \pi (D/2)^2 = \frac{22}{7} \times \frac{D^2}{4} = 0.785 D^2$$

D : aortic annulus diameter (Fig. 6.5)

- The FVI is calculated by the computer software of most echo machines as the area under curve of aortic outflow velocity spectral display.

$$CO = 0.785 D^2 \times FVI \times HR$$

- Using similar calculations, the stroke volume of the right side of heart can be obtained using the peak pulmonary flow velocity (V_{max}) and diameter of the pulmonary valve.

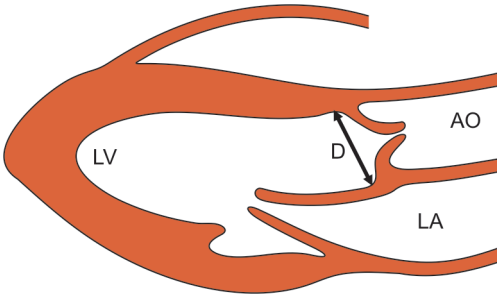


Fig. 6.5: Measurement of aortic annulus diameter (D) to calculate aortic valve area

- Thereafter, the ratio of pulmonary flow (Q_p) to systemic flow (Q_s) which is the $Q_p:Q_s$ ratio, can be calculated to quantify a cardiac shunt (see Congenital Diseases).

Pitfalls in the Diagnosis of LV Systolic Dysfunction

- LV internal dimensions are taken between endocardial surfaces of IVS and LVPW. Errors in measurement may occur if a prominent papillary muscle or a calcified mitral annulus is mistaken for the endocardial surface of LVPW.
- As a differentiating feature, only the LVPW thickens in systole. Abnormal septal motion (e.g. LBBB) makes fractional shortening difficult to measure.
- The normal range for LVEDD and LVESD varies with a number of factors including age, sex, height and body habitus. This should always be borne in mind.
- Measurement of LV dimensions can be unreliable in the presence of abnormal wall motion due to infarction and abnormal septal motion due to left bundle branch block or RV volume overload.
- Reduced LV systolic function is usually but not always associated with increased LV dimensions.
- For instance, a large akinetic segment of the LV wall following myocardial infarction may impair LV systolic function but LV dimensions may be within the normal range.
- An experienced echocardiographer can often give a reasonably good visual assessment of LV systolic function from the PLAX view, without actual measurements.
- However, this rough assessment may be unreliable for serial evaluation of LV function and when LV volumes critically influence the timing of a surgical intervention.

- There may be interobserver and even more surprisingly, intraobserver variations in the measurement of LV dimensions, LV volumes and therefore in the computing of fractional shortening and ejection fraction.
- Often these are due to variations in the frame frozen for calculations and in the delineation of the endocardial surface.
- While calculating LV volumes, certain geometrical assumptions are made about LV shape which are not always valid, particularly in a diseased heart. This often occurs in regional LV dysfunction.
- Post-infarction LV remodelling increases LV sphericity and causes alteration of the normal ellipsoid shape of the left ventricle.
- When assessing LV systolic function, one must allow for effects of volume loading and drug therapy. Fluid overload and antiarrhythmic drugs with negative inotropy may further impair LV function.
- In presence of mitral regurgitation (MR), ejection fraction (EF) may be normal despite reduced contractility of the LV. This is because the left atrium offers less resistance to ejection than does the aorta.
- Conversely, in presence of aortic stenosis (AS), ejection fraction (EF) may be low despite normal contractility of the LV. This is because the left ventricle has to overcome a high transaortic resistance during ejection.
- Therefore, after surgery (valve repair or replacement) for MR, the EF falls and after surgery for AS, the EF rises.
- The calculation of cardiac output from peak aortic flow velocity by Doppler is invalid if the aortic valve is regurgitant or stenotic, because of increased aortic flow velocity.
- The measurement of aortic valve diameter (D) at the aortic annulus is not only difficult but any inaccuracy is magnified, since the D value is squared.

Causes of LV Systolic Dysfunction

Practically, all forms of cardiac disease ultimately culminate in LV systolic dysfunction. Prominent causes are:

- Coronary artery disease
 - single large infarct
 - multiple small infarcts
 - triple vessel disease
- LV pressure overload
 - systemic hypertension
 - aortic valve stenosis
- LV volume overload
 - mitral regurgitation
 - aortic regurgitation
- Left-to-right shunt
 - ventricular septal defect
 - patent ductus arteriosus
- Primary myocardial disease
 - acute viral myocarditis
 - dilated cardiomyopathy

Clinical Significance of LV Systolic Dysfunction

- The presence of LV systolic dysfunction in any form of cardiac disease carries an adverse prognostic implication.
- Patients of coronary artery disease who have LV systolic dysfunction in addition to wall motion abnormalities have a lower survival rate and poorer outcome after a revascularization procedure like coronary bypass surgery.

- When a patient of hypertension with left ventricular hypertrophy develops LV systolic dysfunction, it indicates the onset of the decompensated stage of hypertensive heart disease.
- Volume overloading of the left ventricle due to valvular regurgitation or a left-to-right shunt will ultimately cause LV systolic dysfunction.
- Besides being a prognostic marker, onset of systolic dysfunction plays a crucial role in the timing of corrective surgery.
- Presence of LV systolic dysfunction is an important criteria for the diagnosis of dilated cardiomyopathy.
- Serial echocardiograms can not only assess the natural history of the disease but also the response to therapy.
- Subtle abnormalities of systolic function may not be obvious at rest but brought out by exertion or stress testing.
- Similarly, only minor systolic dysfunction may be observed after drug treatment of heart failure, which may have caused clinical improvement.

Acute Myocarditis

- Myocarditis is inflammation of the heart muscle caused by viral (Coxsackie B), bacterial (*Mycoplasma*) or parasitic (Lyme disease) infection.
- The echo features of myocarditis are similar to those of dilated cardiomyopathy with LV systolic and diastolic dysfunction and valvular regurgitation.
- Abnormal LV wall motion is often global but may be segmental due to patchy inflammation of the myocardium.

- The differentiating features of myocarditis are a short history of febrile illness and an ECG showing resting tachycardia with T wave inversion.
- Serial echos showing rapid improvement of LV function and regression of mitral regurgitation favor the diagnosis of myocarditis rather than dilated cardiomyopathy.

LV DIASTOLIC DYSFUNCTION

In recent years, LV diastolic dysfunction has attracted a great deal of attention. Diastolic dysfunction or the inability of LV to relax occurs in a variety of heart diseases and often predates the decline in LV systolic performance. A recently introduced terminology is heart failure with preserved ejection fraction or HFPEF.

Normal Diastole

Diastole is divided into 4 discrete periods:

- Relaxation phase: AV closure to MV opening (1)
- Early rapid filling: MV opening to end of filling (2)
- Diastasis phase: equilibration phase (3)
- Atrial systole: active atrial contraction (4)

1 and 2 comprise the phase of myocardial relaxation which is an active energy dependent process.

3 and 4 comprise the phase of myocardial distensibility which is a passive stiffness dependent process.

Therefore, there are 2 patterns of diastolic dysfunction:

- slow-relaxation pattern
- restrictive pattern

Echo Features of LV Diastolic Dysfunction

M-Mode MV Level

- Motion of the anterior mitral leaflet (AML) during normal diastole has a characteristic M-shape (E-A pattern). In the presence of LV diastolic dysfunction, AML excursion is diminished, A wave is taller than the E wave and the E : A ratio is reduced.
- These abnormalities occur due to stiffness of left ventricle and greater atrial contribution to ventricular filling.
- These signs are neither highly sensitive nor specific for the presence of diastolic dysfunction.

2-D Echo PLAX View

- 2-D echo cannot directly assess LV diastolic dysfunction. However, it can detect certain associated abnormalities such as ventricular hypertrophy, wall motion abnormality, myocardial infiltration or pericardial thickening.
- Coexistent abnormalities of systolic function may be detected along with LV diastolic dysfunction.
- The diastolic flow pattern from the left atrium to the left ventricle can be assessed by pulsed wave (PW) Doppler using the apical 4-chamber view with the sample volume in the mitral inflow tract. This provides a good quality spectral trace.
- In the normal heart, the transmitral flow pattern (Fig. 6.6A) shows two discrete waves:

E wave : passive early diastolic LV filling

A wave : active late diastolic LV filling

E : A ratio : greater than 1

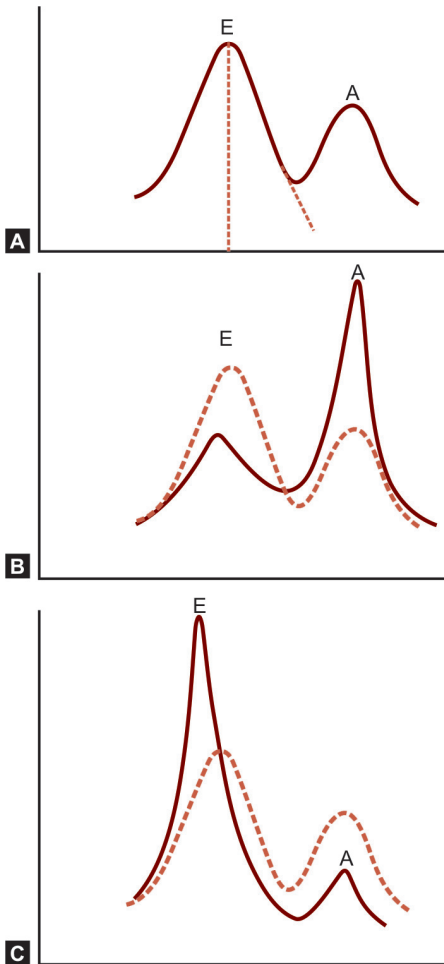


Fig. 6.6: Various patterns of mitral diastolic inflow:
A. The normal flow pattern $E > A$
B. Slow-relaxation pattern, $A > E$
C. Restrictive pattern, very tall E

- When myocardial relaxation is impaired due to LV hypertrophy or myocardial ischemia, the A wave is large and E wave is small, i.e. E : A ratio less than 1 (Fig. 6.6B). The deceleration time (DT) of the E wave is prolonged (> 220 msec).
- In persons aged > 50 years, the E : A ratio should be less than 0.5 to qualify for diastolic dysfunction since the A wave is already dominant at this age.
- This is known as the “slow-relaxation pattern” and indicates reduced LV compliance. There is increase in atrial contribution to ventricular filling.
- When myocardial distensibility is impaired due to myocardial infiltration or pericardial constriction, the E wave is very tall and A wave is small (Fig. 6.6C). The deceleration time (DT) of the E wave is short (< 150 msec).
- This is known as the “restrictive pattern” and indicates an elevated LV end-diastolic pressure (LVEDP). The entire ventricular inflow occurs rapidly in early diastole and the atrium cannot distend the ventricle any further.

Pitfalls in the Diagnosis of LV Diastolic Dysfunction

- The mitral inflow pattern of LV filling is influenced by a large number of factors besides myocardial relaxation and distensibility.
- Therefore, it is inappropriate to rely only on E : A ratio as an indicator of LV diastolic dysfunction.
- Factors that influence the mitral inflow pattern include:
 - volume loading (preload and afterload)
 - heart rate and cardiac rhythm

- left atrial systolic function
- the phase of respiration.
- Volume overloading due to mitral or aortic regurgitation attenuates the A wave since atrial contraction cannot effect forward flow if the ventricle is already maximally distended. The E wave peak is also increased.
- In the presence of tachycardia, A wave is more prominent since the diastole is shortened (greater atrial contribution). When there is bradycardia, A wave is small since diastolic filling is prolonged (lesser atrial contribution). Therefore, a tall A wave carries greater significance in the presence of bradycardia.
- The E : A ratio, as an indicator of diastolic dysfunction, is invalid in the presence of atrial fibrillation, complete heart block or a prolonged P-R interval.
- In atrial fibrillation, there is no atrial contribution to ventricular filling. In complete heart block with A-V dissociation, the E wave and A wave occur at different times. In prolonged PR interval, the E wave and A wave occur at the same time and appear as a single wave.
- In an elderly person, the A wave is dominant. If the E : A ratio is >1 or E = A with short deceleration time (DT), it indicates the presence of an elevated LV end-diastolic pressure (LVEDP). This is referred to as pseudo-normalization of MV inflow pattern.

Causes of LV Diastolic Dysfunction

LV diastolic dysfunction is observed in:

- Advanced age (> 50 years)
- Left ventricular hypertrophy
- Coronary artery disease

- Restrictive cardiomyopathy
- Myocardial infiltration
- Pericardial constriction

Clinical Significance of LV Diastolic Dysfunction

- Diastolic dysfunction occurs due to increased stiffness of the LV wall, which impairs diastolic blood flow from the left atrium to the left ventricle.
- The clinical features of left heart failure may occur in individuals with normal or near-normal LV systolic dysfunction as assessed by echo. These are often due to diastolic dysfunction.
- Diastolic dysfunction is observed in a variety of cardiac conditions. It is more sensitive than systolic dysfunction to the effects of normal aging.
- Abnormalities of diastolic function may occur in isolation, may coexist with systolic dysfunction or may be observed before major systolic impairment becomes obvious. Heart failure may be predominantly diastolic in some cases.
- LV systolic and diastolic function have to be assessed separately since their causation and more importantly their treatment is considerably different.
- Too simplistic a demarcation between diastolic and systolic dysfunction is often misleading. Systole and diastole are phases of a continuous cardiac cycle and interactions do occur between them.
- In mild systolic dysfunction with dyskinetic areas, some regions can continue contracting in diastole leading to shortening of the time available for ventricular filling. This leads to supervening diastolic dysfunction.

- Conversely, a poorly compliant left ventricle that fails to fill adequately in diastole may cause a low stroke volume in systole. This leads to additional systolic dysfunction.
- Prominent A wave can be equated to the fourth heart sound (S_4) on auscultation while a prominent E wave can be equated to the third heart sound (S_3).

RV SYSTOLIC DYSFUNCTION

Whenever echocardiography is ordered or performed, the focus is always on the left ventricle. This is because the most common cardiac conditions namely systemic hypertension, coronary artery disease and valvular pathologies affect the left ventricle. Nevertheless, the importance of the right ventricle and its role in heart disease is being increasingly recognized.

Normal Indices

RV internal dimension	7–23 mm
RV free-wall thickness	< 5 mm

Echo Features of RV Dysfunction

- Right ventricular size and function can be evaluated by M-mode scan from the PLAX view and 2-D echo using the apical and subcostal 4-chamber views.
- RV dysfunction is associated with a dilated (> 23 mm) and hypokinetic right ventricle.
- If the RV is of the same size or larger than the LV in all the echo-views, it is abnormal. An enlarged RV becomes globular and loses its normal triangular shape (Fig. 6.7).
- RV free-wall thickness > 5 mm is evidence of RV hypertrophy secondary to RV pressure overload as in pulmonary hypertension or pulmonary stenosis.

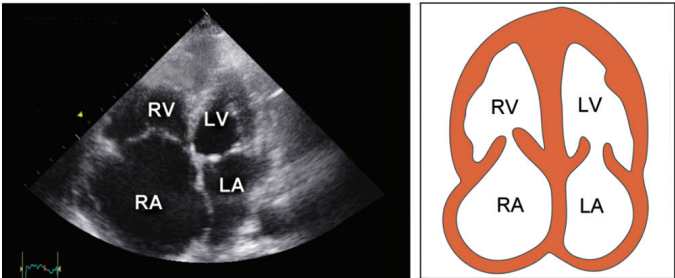


Fig. 6.7: A4CH view showing dilatation of right atrium and ventricle

- Echo may reveal the underlying cause of RV dysfunction such as a left-to-right shunt or right-sided valvular disease.
- In the presence of RV failure, the right atrium is enlarged and the inferior vena cava is dilated beyond 2 cm, which fails to constrict by at least 50 percent during inspiration (Fig. 6.8).
- RV volume overload causes paradoxical motion of the interventricular septum (IVS) on M-mode scan from the parasternal long axis (PLAX) view (Fig. 6.9).

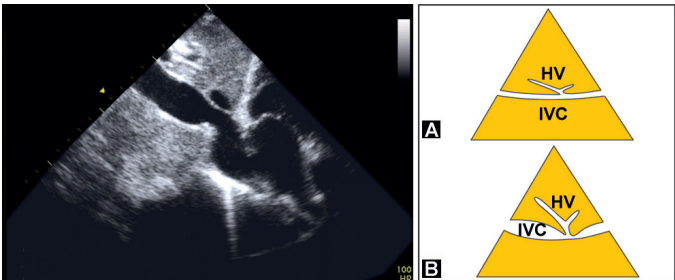


Fig. 6.8: Dimension of the inferior vena cava (IVC):

- Normal dimension
- Dilated vena cava

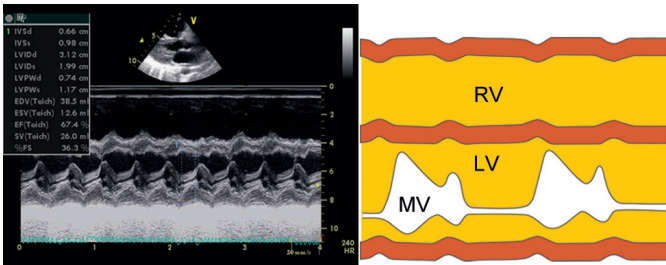


Fig. 6.9: M-mode scan of the right ventricle showing:
 A. Increased dimension of the RV cavity
 B. Paradoxical motion of the IV septum

Pitfalls in the Diagnosis of RV Dysfunction

- Echo assessment of the RV is difficult because of heavy trabeculation, its geometrical complexity and overlap with other chambers on imaging. Moreover, the RV is located directly under the sternum.
- Assessment of the RV is particularly difficult in the presence of lung hyperinflation (emphysema), pulmonary fibrosis and previous thoracic surgery. Paradoxically, study of RV function is all the more important in these patient subsets.
- RV function is sensitive not only to myocardial contractility but also to loading conditions, LV contractility and septal excursion and to intrapericardial pressure. Analysis of RV function should take all these factors into account.
- Even in the most experienced hands, satisfactory echo examination of the right ventricle is obtained in less than 50 percent of subjects.

Causes of RV Dysfunction

RV dysfunction is observed in:

- Left-to-right cardiac shunt: ASD, VSD
- Right-sided valvular disease: TR, PR

- Pulmonary hypertension: PRI, SEC
- Right ventricular infarction: INF. MI
- Right ventricular dilatation: DCMP

Clinical Significance of RV Dysfunction

- Assessment of RV dysfunction plays a critical role in certain congenital and acquired cardiac conditions where it is important for planning treatment, timing surgical intervention and for predicting prognosis.
- In congenital heart disease such as VSD, ASD or Fallot's tetralogy, assessment of RV function before and after surgery is a useful prognostic marker.
- Similarly, timing of surgery in valvular heart disease such as MS, PS or TR is determined by the presence or absence of RV dysfunction.
- The long-term prognosis of patients with chronic lung disease (COPD, ILD) depends upon RV function. RV dilatation, pulmonary hypertension and cor-pulmonale are indicators of a poor prognosis.
- Following myocardial infarction, RV dysfunction may be observed in the following situations:
 - inferior wall infarction with RV infarction.
 - anterior wall infarction with acute VSD.

RV infarction requires a different therapeutic approach than LV infarction. RV dysfunction due to post-MI VSD is an important cause of mortality (see Coronary Artery Disease).

- RV diastolic collapse is a reliable echo parameter of cardiac tamponade (see Pericardial Diseases).



7 Cardiomyopathies

The term cardiomyopathy means a disease of the heart muscle. In its strict sense, the term should only be applied to a condition that has no known underlying cause. In that case it known as an idiopathic cardiomyopathy.

However, the term has, through popular usage, been extended to include conditions wherein there is an identifiable cause. Examples of such conditions include hypertensive, ischemic, alcoholic and diabetic cardiomyopathy.

There are three main types of cardiomyopathies:

- Dilated cardiomyopathy (DCMP)
- Restrictive cardiomyopathy (RCMP)
- Hypertrophic cardiomyopathy (HOCM)

DILATED CARDIOMYOPATHY (DCMP)

Echo Features of DCMP

M-Mode and 2-D Echo

- There is dilatation of all the four cardiac chambers particularly of the left ventricle, which thereby assumes a more globular shape (Fig. 7.1).
- The left ventricular end-diastolic dimension (LVEDD) exceeds 52 mm (normal is 36 to 52 mm).

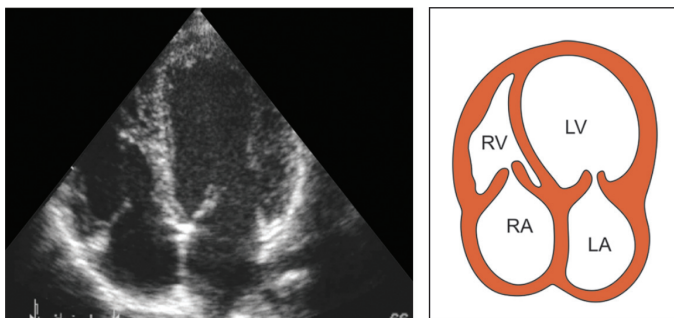

Fig. 7.1: A4CH view showing an enlarged and globular left ventricle

- Reduced LV wall thickness, reduced systolic thickening and reduced amplitude of wall motion are observed. The reduced LV wall motion is generalized or global rather than regional. This is known as global hypokinesia.
- The LV walls are thin or there may be mild hypertrophy which is inadequate for the degree of LV dilatation.
- Left atrial enlargement occurs due to stretching of the mitral annular ring which leads to functional mitral regurgitation.
- There is reduced motion of the IVS and LVPW. The ventricular dimensions (LVESD and LVEDD) are increased.
- Due to global hypokinesia, the systolic excursion of the interventricular septum and of the left ventricular posterior wall are reduced.
- For the same reason, the left ventricular diameter in end-diastole and end-systole is increased.
- Reduced fractional shortening (FS) and ejection fraction (LVEF). The ejection fraction (EF) is low but the cardiac output (CO) may be normal due to compensatory tachycardia.

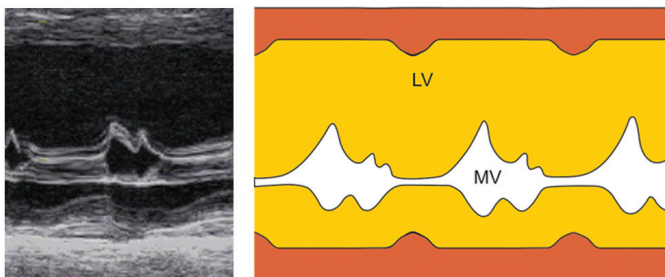


Fig. 7.2: M-mode scan of the left ventricle showing:

- increased size of left ventricular cavity
 - reduced movement of IVS and LVPW
 - increased E-point septal separation
 - reduced excursion of mitral leaflets
- Due to global hypokinesia, indices of left ventricular systolic function are reduced (see Ventricular Dysfunction).
 - Increased E-point septal separation (EPSS) (Fig. 7.2). It is the distance between the farthest posterior excursion of the septum and the E-point of the anterior mitral leaflet (AML). The normal EPSS does not exceed 5 mm.
- Note**
- The EPSS is reduced in hypertrophic obstructive cardiomyopathy (HOCM) due to systolic anterior motion (SAM) of anterior mitral leaflet (AML).
 - Measurement of EPSS lacks utility in the presence of mitral valve disease in which case free motion of the AML is already impaired.
 - Reduced anterior swing of aortic root during left atrial filling (normal >7 mm)
 - Reduced AV cusp separation in systole (normal >15 mm) with premature closure of the aortic valve (Fig. 7.3).

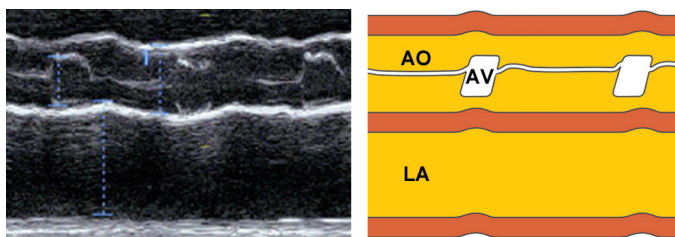


Fig. 7.3: M-mode scan of the aortic valve showing:

- reduced aortic cusp separation
 - dilatation of the left atrium
-
- Reduced MV anterior leaflet excursion in diastole (normal >20 mm) with rapid upstroke and downstroke.
 - All the above are signs of reduced cardiac output.
 - Associated non-specific findings in DCMP are:
 - small pericardial effusion
 - left ventricular thrombus.

Doppler Echo

- Functional mitral and tricuspid regurgitation (MR and TR) occur due to stretching of atrioventricular (A-V) rings, as a consequence of ventricular dilatation.

Differential Diagnosis of DCMP

It may be extremely difficult to differentiate dilated cardiomyopathy from the following conditions:

- Severe MR with LV dysfunction
- Ischemic cardiomyopathy (ICMP).

Severe MR with LV Dysfunction

- Severe organic mitral regurgitation with volume overload and LV dysfunction can mimic DCMP with functional MR due to annular stretching.

TABLE 7.1**Differences between dilated and ischemic cardiomyopathy**

	<i>DCMP</i>	<i>ICMP</i>
Hypokinesia	Global	Regional
Wall-motion and perfusion region	Unmatched	Matched
Dyskinesia	Not seen	Seen
RV involvement	Often	Rare

- Organic MR with LV dysfunction is suggested if there is one of the following features:
 - mitral leaflet thickening, prolapse or a flail leaflet
 - history of a long-standing pansystolic murmur.

Ischemic Cardiomyopathy (ICMP)

- Dilated cardiomyopathy (DCMP) can closely mimic ICMP with certain subtle differences (Table 7.1):
 - in DCMP there is global hypokinesia while in ICMP, atleast one region of the left ventricle moves normally.
 - in DCMP if there is patchy involvement, the regional wall motion abnormalities (RWMAs) do not conform to arterial distribution. On the other hand in ICMP, RWMAs conform to coronary perfusion territories.
 - right ventricle is often involved in DCMP but relatively spared in case of ICMP.
 - dyskinetic areas and aneurysms are a feature of ICMP and not seen in DCMP.

Causes of DCMP

- idiopathic
- post-viral

- alcoholic
- diabetic
- peripartum
- nutritional
- drug-induced.

Causes of Large LV in Adults

- dilated cardiomyopathy (DCMP)
- anterior myocardial infarction (AMI)
- ischemic cardiomyopathy (ICMP)
- LV volume overload (MR, AR, PDA)
- LV pressure overload (AS, HTN).

Causes of Large LV in Infants

- congenital cardiomyopathy
- coarctation of the aorta
- anomalous left coronary artery arising from pulmonary artery (ALCAPA).

RESTRICTIVE CARDIOMYOPATHY (RCMP)

Echo Features of RCMP

M-Mode and 2-D Echo

- Thickening of the LV and RV free walls and the IV septum. The thickness of LVPW and IVS in diastole exceeds 12 mm and that of the RV free wall is >5 mm.
- Bright echogenicity of endocardium with patches of speckling or mottling in the myocardium. Infiltration of amyloid into the IV septum produces a sparkling 'ground-glass' appearance.

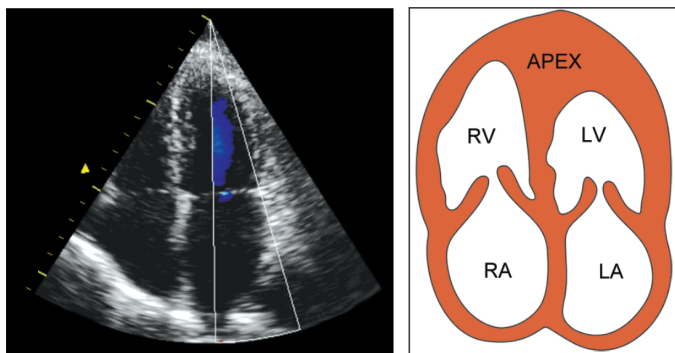


Fig. 7.4: Apical 4-chamber view showing:

- thick and bright septum
 - reduced size of ventricles
 - dilated right and left atrium
-
- Reduced internal dimensions and cavity size of LV and RV with cavity obliteration at LV and RV apex (Fig. 7.4).
 - The left ventricular end-diastolic dimension (LVEDD) is reduced to less than 35 mm (normal 36 to 52 mm).
 - Mild impairment of LV systolic function with reduced IVS and LVPW thickening and inward motion.
 - Thickening of mitral and tricuspid leaflets
 - Dilatation of the right atrium and left atrium
 - Ventricular thrombus and pericardial effusion.

Doppler Echo

- Mitral and tricuspid regurgitation (MR and TR) due to thickening of MV and TV leaflets.
- Impairment of LV and RV diastolic function with a slow relaxation pattern (A taller than E) or a restrictive pattern (very tall E) seen on MV inflow spectral tracing (Fig. 7.5).

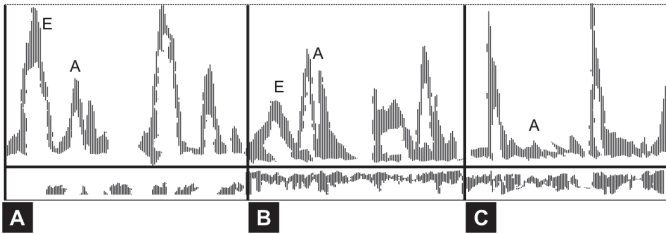


Fig. 7.5: Patterns of mitral inflow seen on PW Doppler:
 A. Normal flow pattern. $E > A$
 B. Slow-relaxation pattern. $A > E$
 C. Restrictive pattern. Very tall E

Differential Diagnosis of RCMP

- It may be difficult to differentiate a case of restrictive cardiomyopathy from constrictive pericarditis on the basis of echo findings. Often cardiac catheterization is required.
- The differentiation between the two conditions is important as it has crucial management implications. The following features are observed only seen in case of RCMP and not in constrictive pericarditis:
 - thickening of ventricular walls
 - reduction of ventricular cavity size
 - impairment of LV systolic function
 - mitral and tricuspid regurgitation
 - dilatation of right and left atrium.
- RCMP needs to be differentiated from apical cardiomyopathy, a sub-type of hypertrophic cardiomyopathy, where the hypertrophy is confined to the apices of the ventricles with obliteration of ventricular cavity.

- In both these conditions, the right and left atrium are enlarged. The only other cardiac condition in which both the atria are enlarged with normal or small ventricles is mitral stenosis with pulmonary hypertension and secondary tricuspid regurgitation.
- In dilated cardiomyopathy there is enlargement of all four chambers of the heart.

Causes of RCMP

- Idiopathic restrictive CMP
- Endomyocardial fibrosis (EMF)
- Loeffler's hypereosinophilia
- Carcinoid syndrome
- Myocardial infiltration due to:
 - amyloidosis
 - sarcoidosis
 - malignancy
 - hemochromatosis
 - glycogen storage disease.

Causes of Small LV

- Restrictive cardiomyopathy
- Hypertrophic cardiomyopathy
- Hypertensive heart disease
- Aortic valve stenosis
- Ventricular thrombus
- Intracardiac tumor
- Athlete's heart.

HYPERTROPHIC CARDIOMYOPATHY (HOCM)

Echo Features of HOCM

M-Mode and 2-D Echo

- Asymmetrical septal hypertrophy (ASH). There is hypertrophy of the interventricular septum (IVS) to a greater extent than that of the LV posterior wall (LVPW) (Fig. 7.6).
- Thickening of IV septum is confined to the base and impinges on LV outflow tract. The IVS: LVPW ratio exceeds 1.5.
- The ASH is observed in 60% cases of HOCM while 30% show symmetrical ventricular hypertrophy. In 10% cases, the hypertrophy is confined to the apices of the ventricles, i.e. apical cardiomyopathy (Fig. 7.7).
- The thickened IVS shows bright echogenicity with speckling in the myocardium due to myocardial fiber disarray.
- There is reduced IVS motion with vigorous excursion of the LV posterior wall (LVPW). The LV cavity appears small.
- Systolic anterior motion (SAM) of anterior mitral leaflet (AML). During mid-systole, the AML moves anteriorly to coapt with

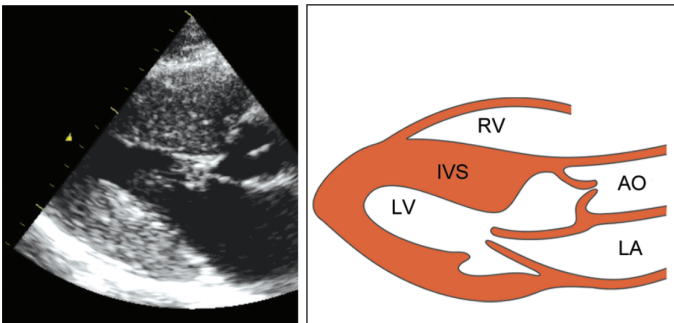


Fig. 7.6: PLAX view showing asymmetrical septal hypertrophy

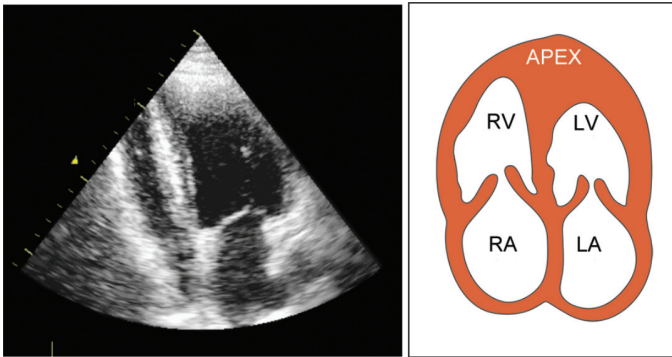


Fig. 7.7: A4CH view showing hypertrophy of the LV apex

the septum. This occurs due to Venturi effect caused by high velocity in the LV outflow tract (LVOT) (Fig. 7.8).

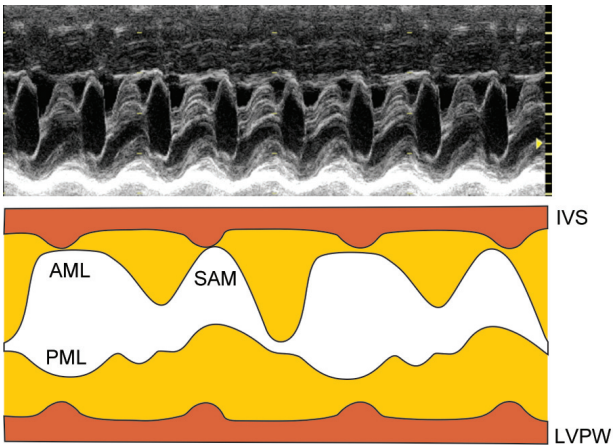


Fig. 7.8: M-mode scan of the mitral valve showing systolic anterior motion (SAM) of the anterior mitral leaflet (AML)

- Systolic anterior motion (SAM) occurs during later stage of systole when the LV cavity size becomes smaller. SAM causes dynamic LV outflow tract obstruction.
- Therefore the term hypertrophic obstructive cardiomyopathy (HOCM) is more appropriate.
- If LVOT obstruction is not demonstrable, the term used is idiopathic hypertrophic sub-aortic stenosis (IHSS).
- LVOT obstruction may be present at rest or become more pronounced following provocation. The duration of contact between the anterior mitral leaflet (AML) and the interventricular septum (IVS) correlates with the severity of LVOT obstruction.
- Provocation may be provided by prolonged standing, isovolumic exercise (e.g. hand-grip), Valsalva manoeuvre or sublingual nitrate. All these methods reduce LV size and thus increase the degree of LVOT obstruction.
- Dynamic LVOT obstruction during the later part of systole causes mid-systolic aortic valve closure and late-systolic fluttering of the aortic cusps (Fig. 7.9).

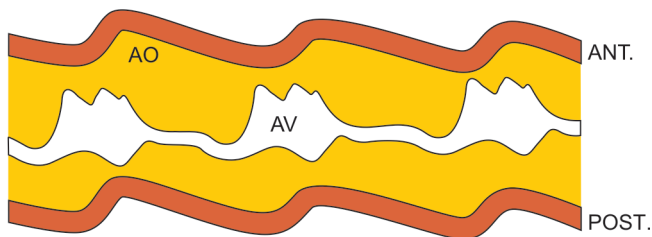


Fig. 7.9: M-mode scan of the aortic valve showing mid-systolic closure and late-systolic fluttering of aortic cusps

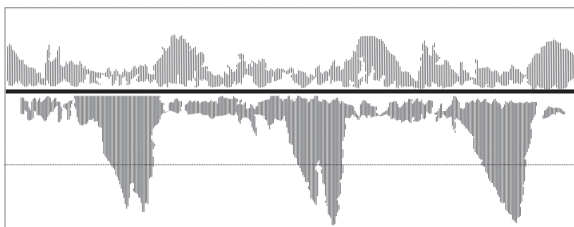


Fig. 7.10: CW Doppler showing a concave high velocity jet in LV outflow tract, proximal to the aortic valve

Doppler Echo

- On CW Doppler, there is increased peak flow velocity across the LVOT. PW Doppler with the sample volume in the LVOT shows the increased velocity to be proximal to the aortic valve.
- The high velocity jet has a characteristic concave appearance with the peak velocity (V_{max}) coinciding with peak SAM in mid-systole. Normally, it peaks in early systole (Fig. 7.10).
- There are features of LV diastolic dysfunction due to myocardial hypertrophy with an abnormal transmitral inflow spectral trace (A wave taller than E wave).
- Mitral valve regurgitation is frequently associated with LV outflow tract obstruction.

Differential Diagnosis of HOCM

- An IVS : LVPW ratio of 1.5 or greater indicates HOCM. A ratio between 1.3 and 1.5 is observed in:
 - hypertension with LVH
 - aortic stenosis with LVH
 - septal infiltration (RCMP).

- Localized subaortic bulging in the basal part of the IV septum (sigmoid septum) is a normal finding in the elderly and should not be misdiagnosed as HOCM.
- Reduced IVS motion with vigorous LVPW excursion is a feature of HOCM. Reduced IVS motion is also observed in DCMP and old myocardial infarction with the following differences:
 - in DCMP, the LVPW is also equally hypokinetic
 - in old septal MI, the LVPW shows hyperkinesia.
- Systolic anterior motion (SAM) of the anterior mitral leaflet (AML) is also observed in:
 - mitral valve prolapse (anterior buckling of AML)
 - hyperdynamic circulation (vigorous excursion)
 - pericardial effusion (pseudo-SAM) during swing.
- Mid-systolic aortic valve closure occurs in HOCM due to dynamic LVOT obstruction.
- Premature systolic AV closure is also observed in:
 - subvalvular aortic stenosis
 - MR (LV ejection into LA)
 - VSD (LV ejection into RV)
 - DCMP (reduced LV output).
- The peak flow velocity across the LVOT in HOCM can be differentiated from valvular aortic stenosis by the following features:
 - on PW Doppler, V_{\max} is proximal to the valve
 - the flow velocity has a typical concave pattern.
- LV diastolic dysfunction in HOCM can be differentiated from that due to RCMP by the presence of ASH, SAM, LVOT obstruction and early AV closure.

- The high velocity jet across LVOT in HOCM needs to be differentiated from the adjacent jet of mitral regurgitation which often coexists.
- The timing of systolic velocity and concave appearance of the jet are classical features of HOCM.

Classification of HCMP

Based upon the location of hypertrophy and presence or absence of hemodynamic effects, hypertrophic cardiomyopathy (HCMP) can be classified into these types:

- Location of hypertrophy (symmetrical/asymmetrical)
 - asymmetrical septal hypertrophy (ASH)
 - symmetrical left ventricular hypertrophy (LVH).
- Hemodynamic effects (obstructive/non-obstructive)
 - hypertrophic obstructive cardiomyopathy (HOCM)
 - idiopathic hypertrophic sub-aortic stenosis (IHSS).



8

Coronary Artery Disease

Since coronary artery disease (CAD) is the leading form of heart disease in middle and old ages, it is therefore not surprising that CAD is the most common clinical diagnosis in those on whom echo is performed.

INDICATIONS FOR ECHO IN CAD

- Detection of myocardial ischemia.
- Prediction of infarction-related artery.
- Assessment of left ventricular function.
- Detection of right ventricular infarction.
- Diagnosis of acute complications
 - acute mitral regurgitation
 - ventricular septal defect
 - ventricular aneurysm
 - pericardial effusion
 - mural thrombus
- Direct visualization of coronaries
 - proximal coronary stenosis
 - coronary artery aneurysm
 - coronary arterial fistula
 - anomalous origin of artery

- Diagnosis of simulating conditions
 - aortic stenosis (AS)
 - MV prolapse (MVP)
 - cardiomyopathy (HOCM)
- Stress echocardiography
 - if TMT is not possible, uninterpretable or equivocal.
 - to localize the site and quantify extent of ischemia.
 - assessment of myocardial stunning or hibernation.

MYOCARDIAL ISCHEMIA

- Abnormal systolic wall thickening; reduced or absent. Thickening of ischemic myocardial segment in systole is either reduced in extent or altogether absent.
- Abnormal systolic wall motion: hypokinesia, akinesia or dyskinesia. Inward motion of the ischemic myocardial segment during systole is partially reduced, entirely absent or paradoxically outwards.
- These changes are transient if ischemia is reversed by giving rest or nitrate medication. Acute myocardial infarction causes similar abnormalities which are reversible by thrombolytic therapy or primary angioplasty.
- Abnormal wall motion can be classified as in Table 8.1, with each pattern of wall motion been assigned a score.
- From the wall motion score, the wall motion index can be calculated as follows:

$$\text{Wall motion index} = \frac{\text{Sum of scores of all segments}}{\text{Number of segments studied}}$$

A wall motion index that exceeds 1.5 is abnormal.

TABLE 8.1**Ventricular systolic wall motion description and scoring**

<i>Score</i>	<i>Motion</i>	<i>Description</i>
1.	Normal motion	Full inward motion
2.	Hypokinesia	< 50% inward motion
3.	Akinesia	No inward motion
4.	Dyskinesia	Outward movement
5.	Aneurysmal	Outpouching of wall

MYOCARDIAL INFARCTION

- Abnormal systolic wall thickening; reduced or absent. Thickening of infarcted myocardial segment in systole is either reduced in extent or altogether absent.
- There may be systolic thinning to less than 6 mm or by more than 30% compared to adjacent myocardium. This occurs if the infarct is old. The normal septal thickness is 6 to 12 mm.
- The thinned infarcted myocardial segment is more echo-reflective than the adjacent myocardium, due to post-infarction fibrosis and scarring.
- Abnormal systolic wall motion: hypokinesia, akinesia or dyskinesia. Inward motion of the infarcted myocardial segment during systole is reduced, absent or paradoxically outwards respectively (Fig. 8.1).
- Dyskinetic segments and aneurysmal areas are more often due to old myocardial infarction than due to ischemia, because of prior myocardial scarring.
- Wall motion abnormalities due to infarction are not reversible by medication (nitrate) or intervention (thrombolysis or PTCA) (Fig. 8.2).

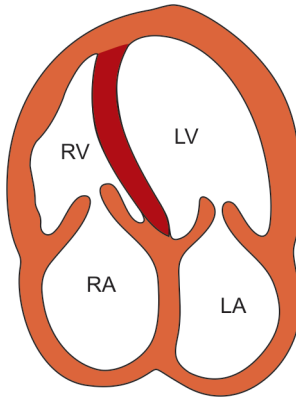


Fig. 8.1: A4CH view showing a thin and scarred IV septum that moves paradoxically outwards in systole

- The normal myocardial segment opposite the wall that shows reduced motion, exhibits compensatory hyperkinesia and exaggerated motion.
- Besides myocardial infarction, reduced wall motion is also observed in cardiomyopathy and pericardial constriction.

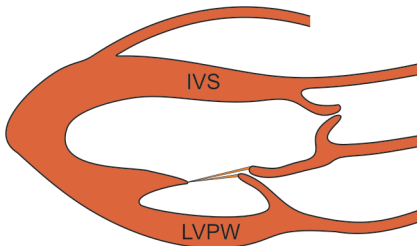


Fig. 8.2: Motion of IVS and LVPW as seen on PLAX view

TABLE 8.2**Motion of the septum (IVS) and posterior wall (LVPW)**

<i>Contractility</i>	<i>Amplitude of motion (mm)</i>	
	IVS	LVPW
Reduced	< 3	< 9
Normal	3-8	9-14
Exaggerated	> 8	> 14

Exaggerated wall motion is due to compensatory hyperkinesia and in volume overload with hyperdynamic circulation. Motion of the IV septum may be paradoxical (away from LV cavity during systole) in certain situations.

- Wall motion of the IV septum and LV posterior wall can be categorized as normal, reduced and exaggerated as shown in Table 8.2
- Wall motion of the IV septum and LV posterior wall is abnormal in the following situations:

LV Posterior Wall (LVPW) Motion

- Reduced* : LV posterior wall infarction
 Dilated cardiomyopathy
 Constrictive pericarditis
- Exaggerated* : LV volume overload
 RV volume overload
 MV paraprosthetic leak
 Septal wall infarction

Ventricular Septum (IVS) Motion

<i>Reduced</i>	:	Septal wall infarction Hypertrophic myopathy Dilated cardiomyopathy
<i>Exaggerated</i>	:	LV volume overload Hyperdynamic state Posterior wall infarction
<i>Paradoxical</i>	:	RV volume overload Constrictive pericarditis Left bundle branch block

- Segments of the left ventricle seen on echo are:
 - IV septum (Fig. 8.3)
 - LV apex (Fig. 8.4)
 - anterior wall (Fig. 8.5)
 - lateral wall (Fig. 8.6)
 - inferior wall (Fig. 8.7)

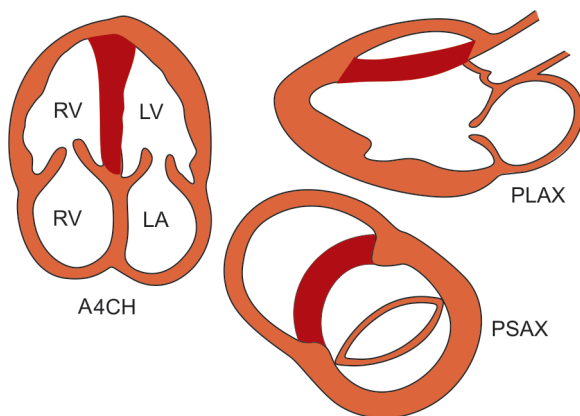


Fig. 8.3: The ventricular septum seen from various views

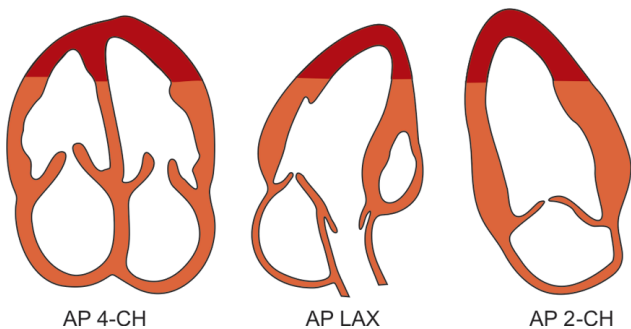


Fig. 8.4: The ventricular apex seen from various views

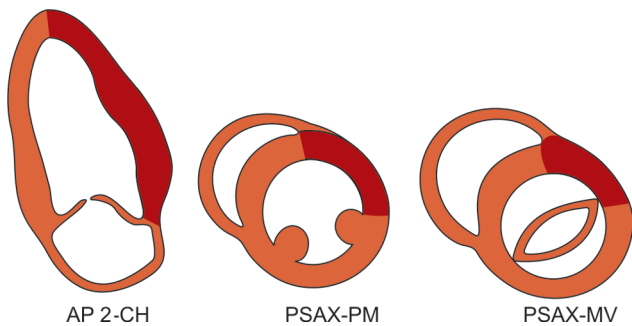


Fig. 8.5: The anterior wall seen from various views

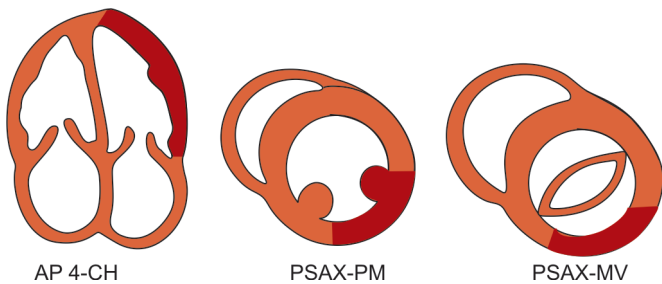


Fig. 8.6: The lateral wall seen from various views

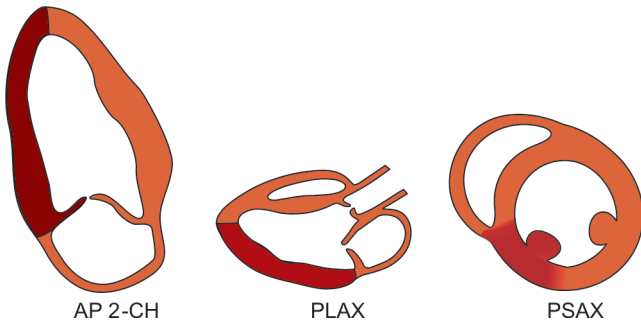


Fig. 8.7: The inferior wall seen from various views

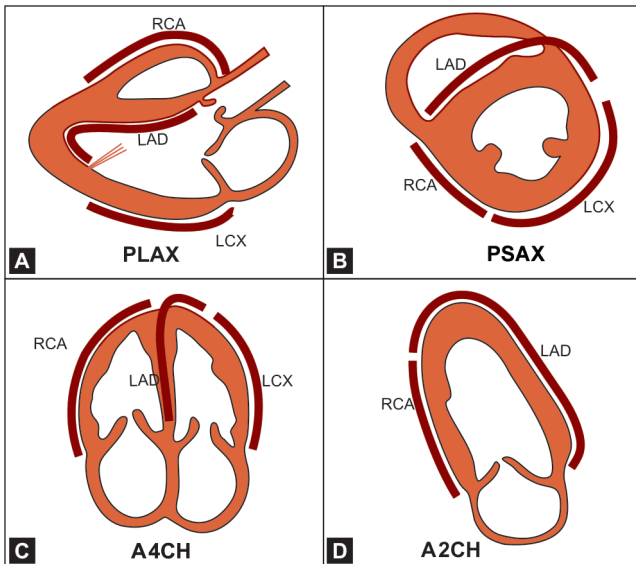


Fig. 8.8: The coronary arterial supply to different areas of the heart:

- | | |
|--------------|--------------------------------|
| A. PLAX view | LAD : Left anterior descending |
| B. PSAX view | LCX : Left circumflex artery |
| C. A4CH view | RCA : Right coronary artery |
| D. A2CH view | |

- On 2-D imaging, the left ventricle can be divided into several segments. This is useful to identify the location of ischemia or infarction and to quantify its extent.
- Each wall can be further divided into basal (proximal), middle and apical (distal) segments. Multiple views are used to study wall motion.
- From the location of regional wall motion abnormalities, it is possible to predict the coronary artery involved in the ischemic event (Fig. 8.8).

LEFT VENTRICULAR DYSFUNCTION

- Presence of coronary artery disease even without prior myocardial infarction can cause LV diastolic dysfunction (impaired myocardial relaxation).
- A single large myocardial infarction or repeated small infarcts leads to scarring of myocardium resulting in thin segments which do not thicken during systole and show reduced motion.
- This is often associated with LV systolic dysfunction. Thinning of myocardium with reduced systolic motion is also observed in dilated cardiomyopathy.
- Triple vessel coronary artery disease may lead to impairment of LV systolic dysfunction even in the absence of prior myocardial infarction (Fig. 8.9).
- This condition is referred to as ischemic cardiomyopathy (ICMP). ICMP superficially resembles a dilated cardiomyopathy (DCMP) with the following subtle differences:
 - in ICMP, at least one portion of the LV moves normally while global hypokinesia is seen in DCMP.
 - dyskinetic areas and aneurysms are a feature of ICMP and are not observed in DCMP.

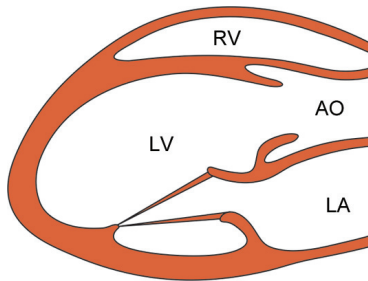


Fig. 8.9: PLAX view showing enlargement of the left ventricle in a patient of ischemic cardiomyopathy

- in ICMP but not DCMP, wall motion abnormalities conform to specific coronary arterial territories.
- the right ventricle is usually spared in ICMP but often shows abnormal motion in DCMP.
- Following temporary coronary occlusion, impairment of myocardial contractile function may remain, even after restoration of blood supply without infarction.
- This condition is termed as myocardial stunning and the myocardial tissue remains viable to regain normal function after 1 to 2 weeks.
- Similarly, recurrent episodes of acute ischemia may result in temporary myocardial dysfunction which is termed as myocardial hibernation.
- Myocardium that is stunned or hibernating does not have enough energy to contract but is still viable and able to repair wear and tear.
- A stunned or hibernating myocardium causes LV systolic or diastolic dysfunction which is potentially reversible by a revascularization procedure.
- Cardiogenic shock after acute myocardial infarction may be due to pump failure following extensive muscle damage. In this condition, echo shows severe impairment of LV systolic function.

- Alternatively, it may be due to LV free wall rupture, hemo-pericardium and cardiac tamponade.
- In acute mitral regurgitation or acute ventricular septal defect after myocardial infarction, LV systolic function remains active.

RIGHT VENTRICULAR DYSFUNCTION

- Whenever echocardiography is performed for assessment of coronary artery disease, the focus is on the left ventricle.
- Nevertheless, evaluation of the right ventricle is important, particularly after inferior wall myocardial infarction.
- In them, prognosis is worse if there is right ventricular infarction and RV dysfunction.
- The hemodynamic response of the right ventricle to myocardial infarction is different from that of the left ventricle.
- When there is RV infarction, cardiogenic shock is common and it requires a different therapeutic approach than does LV infarction (fluid challenge rather than diuresis).
- Right ventricular infarction is suspected clinically by the coexistence of hypotension (low BP) with elevated venous pressure (high JVP)
- RV infarction is associated with a dilated (> 23 mm) and hypokinetic right ventricle. There is paradoxical motion of the IV septum. The right atrium is dilated (Fig. 8.10).
- Due to RV failure, the inferior vena cava (IVC) is dilated by more than 2 cm and fails to constrict by atleast 50 percent during the phase of inspiration.
- Evaluation of RV function is also useful in assessing the prognosis of patients with ventricular septal defect (acute VSD) following myocardial infarction.
- RV dysfunction is a predictor of cardiogenic shock and mortality in these patients.

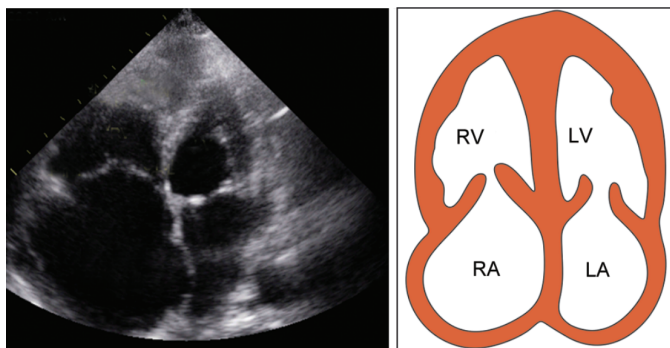


Fig. 8.10: A4CH view showing dilatation of right ventricle and atrium due to right ventricular infarction

ACUTE MITRAL REGURGITATION

- Acute MR in a setting of acute myocardial infarction occurs either due to papillary muscle rupture or because of papillary muscle dysfunction.
- Rupture of a papillary muscle causes a flail mitral valve leaflet. Since rupture of the posteromedial papillary muscle is more common than that of the anterolateral muscle, often it is the posterior mitral leaflet (PML) that is flail.
- It generally follows inferior wall infarction due to occlusion of the posterior descending branch of the right coronary artery.
- On 2-D echo, the flail leaflet exhibits an exaggerated whip-like motion (like a sail flapping in the wind). Its tip moves past the coaptation point into the left atrium and fails to coapt with the AML (Fig. 8.11).
- Superficially, it resembles the floppy leaflet of mitral valve prolapse (see Valvular Diseases).

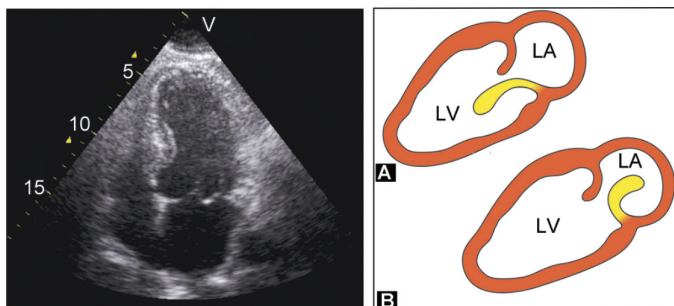


Fig. 8.11: A4CH view showing a flail posterior mitral leaflet with exaggerated motion:
 A. in left ventricle during diastole
 B. into left atrium during systole

- Papillary muscle dysfunction is due to ischemic restriction of papillary function or akinesia of the infero-basal wall that does not shorten in systole.
- As a result, the posterior MV leaflet fails to reach the plane of the MV annulus and the coaptation point of AML with PML in systole, is located distally in the left ventricle.
- On continuous wave (CW) Doppler or color flow mapping, the MR flow velocity or color jet is eccentric and directed towards the posterior left atrial wall.
- The jet area may be much less than what the actual amount of MR would indicate hence there is a risk of underestimation of MR severity.
- Unlike in the MR of valvular disease, in acute MR there is no dilatation of the left atrium and ventricle or abnormal architecture of the MV leaflets.
- In acute MR due to acute MI, LV systolic function remains preserved unlike in pump failure due to extensive MI, where there is severe impairment of LV function.

VENTRICULAR SEPTAL DEFECT

- Ventricular septal defect (acquired VSD) in a setting of acute myocardial infarction occurs due to a breach in continuity of the interventricular septum.
- It often occurs near the cardiac apex and is more common after damage to the inferior wall with right ventricular infarction.
- The discontinuity of the IV septum can be seen as an echo drop-out on 2-D echo in several views.
- The perforation expands in systole and often there is an aneurysmal bulge of the septum close to the LV apex.
- The VSD jet can be seen on color flow mapping and by tracking the pulsed wave (PW) Doppler sample volume along the right side of the septum (Fig. 8.12).
- Significant left-to-right shunting of blood across the VSD can cause RV volume overload. As in acute MR, the LV systolic function is preserved in acute VSD.

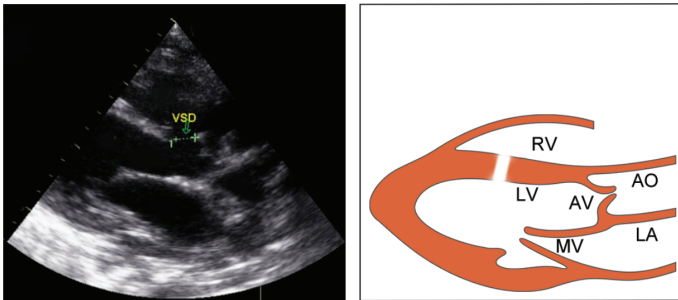


Fig. 8.12: PLAX view showing a color flow map across a ventricular septal defect

LEFT VENTRICULAR ANEURYSM

- An aneurysm is a large bulge-like deformity with a wide neck, located at or near the apex of the left ventricle. It is more common after damage to the anterior wall than after inferior wall infarction.
- The aneurysm exhibits dyskinesia of motion or outward systolic expansion and a persistent diastolic deformity (Fig. 8.13).
- The wall of the aneurysm is made of myocardium and is more echogenic than adjacent areas because of fibrous scar tissue. It does not rupture but is often associated with a pedunculated or laminated ventricular thrombus.
- A false aneurysm (pseudo-aneurysm) follows a breach in the left ventricular free wall, wherein the resulting hemopericardium clots and seals off the gap by means of pericardial adhesions.
- The neck of the pseudo-aneurysm that communicates with the left ventricle is narrower than the diameter of the aneurysm. Therefore, it appears as a globular extracardiac pouch, external to the LV cavity.

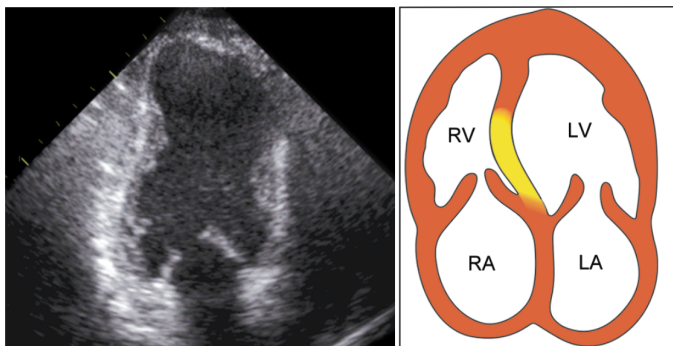


Fig. 8.13: A4CH view showing an aneurysmal bulge of the interventricular septum

TABLE 8.3**Differences between true LV aneurysm and pseudo-aneurysm**

	<i>LV aneurysm</i>	<i>Pseudo-aneurysm</i>
Shape	Wide neck	Narrow neck
Location	Apex of LV	Posterior wall
Motion	Dyskinetic	Expansile
Wall	Myocardium	Pericardium
Rupture	Unlikely	Liable
Thrombus	Laminar	Fills cavity

- A false aneurysm is located on the posterolateral LV wall and is more common after inferior wall than after anterior wall infarction. Being thin-walled, it expands in systole.
- The wall of the aneurysm is made of pericardium and it is less echogenic than adjacent areas. It is friable, liable to rupture and is often filled with a thrombus due to clotted hemopericardium.
- The differences between a true and false LV aneurysm are enumerated in Table 8.3.

VENTRICULAR MURAL THROMBUS

- A ventricular thrombus may form on a dyskinetic, infarcted and scarred myocardial segment or within a left ventricular aneurysm.
- It appears as a rounded pedunculated mass protruding into the LV cavity (Fig. 8.14) or as a flat laminated mural thrombus contiguous with the ventricular wall.
- A mobile mural thrombus may be a source of peripheral embolization (see Intracardiac Masses).

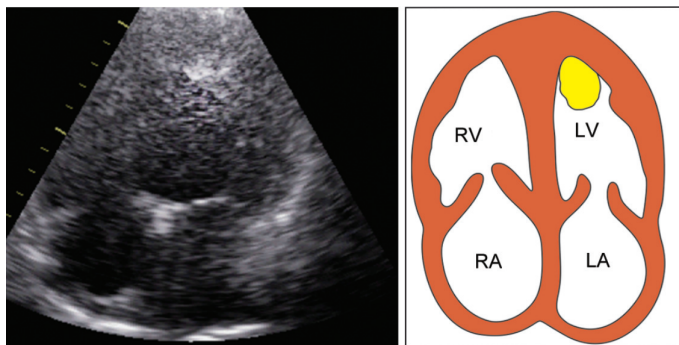


Fig. 8.14: A4CH view showing a ventricular thrombus protruding into the LV cavity

ACUTE PERICARDIAL EFFUSION

- A small amount of pericardial effusion may accumulate due to pericardial reaction after myocardial infarction.
- A rupture of the left ventricular free wall may lead to hemopericardium. This may cause cardiac tamponade which is usually fatal.
- Sometimes the hemopericardium clots, seals off the hole by adhesions and forms a pseudo-aneurysm.
- An autoimmune pericarditis with a small amount of effusion may follow acute myocardial infarction. This is known as the Dressler's syndrome.

CORONARY ARTERY ANOMALIES

- Echocardiography is not the best investigative modality to visualize the coronary arteries directly. Coronary angiography is the best investigation for this purpose.
- Sometimes, direct visualization of the coronary arteries may reveal the following abnormalities:

- coronary stenosis at the origin of the artery seen as a focal reduction in lumen or increase in reflectivity of the proximal 1.0-1.5 cm of artery.
- coronary artery aneurysm seen as a circular echo-free space in case of Kawasaki syndrome.
- coronary artery fistula seen as a pair of parallel echo lines with a wide lumen separating them.
- anomalous origin of artery seen as a dilated right coronary artery with the left coronary artery arising from pulmonary artery. This condition is known as ALCAPA (anomalous left coronary artery from pulmonary artery).

SIMULATING CONDITIONS

- The commonest form of coronary artery disease (CAD) is narrowing of the vessel lumen by atherosclerotic plaque(s). The most frequent symptom of CAD is chest pain (angina pectoris) due to myocardial ischemia.
- This anginal pain needs to be differentiated from other causes of chest pain such as esophageal disorders and musculoskeletal diseases.
- Occasionally, the chest pain is caused by cardiac conditions that simulate CAD in their clinical presentation. These conditions can be readily diagnosed by echocardiography and they include:
 - aortic valve stenosis (AS)
 - mitral valve prolapse (MVP)
 - hypertrophic CMP (HOCM)

These have been discussed elsewhere in this book.

STRESS ECHOCARDIOGRAPHY

Principle

Stress echocardiography is a non-invasive technique to demonstrate abnormalities of regional wall motion and myocardial thickness which are not present when the echo is performed at rest. In other words, it picks up the effects of ischemia which are inducible or provokable by stress.

Technique

The stress is delivered by one of the following methods:

- Physical exercise on a treadmill or bicycle as used for stress ECG testing (TMT).
- Pharmacological stress with dobutamine, an inotropic sympathomimetic agent which increases the heart rate and blood pressure and there by the oxygen demand.
- Vasodilators like adenosine and dipyridamole may be used to dilate normal coronary arteries and in the process, divert blood away from the stenotic artery.
- Electrical cardiac pacing may be employed to increase the heart rate and to simulate exercise.

Indications

- As an alternative to the stress ECG test. The situations in which stress ECHO is superior to the stress ECG test are:
 - inability to exercise on a treadmill or bicycle. (due to prior stroke, arthritis, obesity or fraility)
 - resting ECG abnormality (LBBB, LVH, digoxin)
 - equivocal or inconclusive stress ECG testing.

The sensitivity and specificity of stress echocardiography for detection of coronary disease (80% and 90% respectively), are higher than those of stress ECG (65% and 75%).

It is quite similar to that of radionuclide myocardial perfusion imaging (stress thallium). Wall motion abnormalities appear earlier than either chest pain or ST segment depression.

- To localize the site and quantify the extent of ischemia.
As mentioned earlier, the left ventricle can be divided into several segments to study wall motion abnormalities. From the pattern of abnormal motion, not only can ischemia be quantified but the occluded artery can also be predicted.

This is helpful in the following situations:

- to select patients for early coronary angiography and revascularization, e.g. a large wall motion abnormality in the LAD territory.
 - to stratify the risk of a future coronary event after acute myocardial infarction.
 - to assess the functional significance of a known stenotic lesion while planning a revascularization procedure (angioplasty or by-pass surgery).
- To assess viability of the myocardium.

Myocardium that is stunned or hibernating causes LV systolic or diastolic dysfunction which is reversible by revascularization. If hibernation is present but not revascularized, mortality is higher than if there was no viability at all.

This fact underscores the importance of detecting hibernating myocardium. Stress echo is similar in sensitivity to positron emission tomography (PET) in detecting myocardial viability.

Positive Test

The stress echo is positive with one or more of these findings:

- worsening of previous wall motion abnormality.
- appearance of a new wall motion abnormality.
- inability of the myocardial thickness to increase.

- failure to rise or actual fall in the ejection fraction.
- appearance or worsening of mitral regurgitation.

Negative Test

The stress echo is false negative in these situations:

- small ischemic area with good collateralization.
- single vessel disease without prior infarction.
- difficult echo window or operator inexperience.
- post-exercise time-lag before echo is obtained.

Limitations

The limitations of stress echo as a diagnostic modality are:

- high degree of operator dependency in interpretation.
- difficult acoustic windows in the presence of obesity or pulmonary emphysema.
- artefacts caused by hyperventilation during the immediate post-exercise period.
- difficulty in delineation of the endocardial lining causing error in volumetric measurement.
- presence of septal dyskinesia due to the coexistence of left bundle branch block.



9

Systemic Hypertension

Since systemic arterial hypertension (HTN) is a common clinical condition, echo is often performed in hypertensive subjects.

INDICATIONS FOR ECHO IN HTN

- Detection of left ventricular hypertrophy (LVH). (see Echo Features below)
- Assessment of LV systolic and diastolic function. (see Ventricular Dysfunction)
- Detection of coexisting coronary artery disease. (see Coronary Artery Disease)
- Detection of mitral and aortic valve degeneration. (see Valvular Diseases)
- Detection of aortic dilatation and coarctation. (see Diseases of Aorta)

LEFT VENTRICULAR HYPERTROPHY (LVH)

Echo Features of LVH

- Increase in thickness of the interventricular septum (IVS) and left ventricular posterior wall (LVPW).
- The normal thickness of the IVS and LVPW in diastole is 6 to 12 mm. Thickness exceeding 12 mm indicates presence of left ventricular hypertrophy (LVH) (Fig. 9.1).

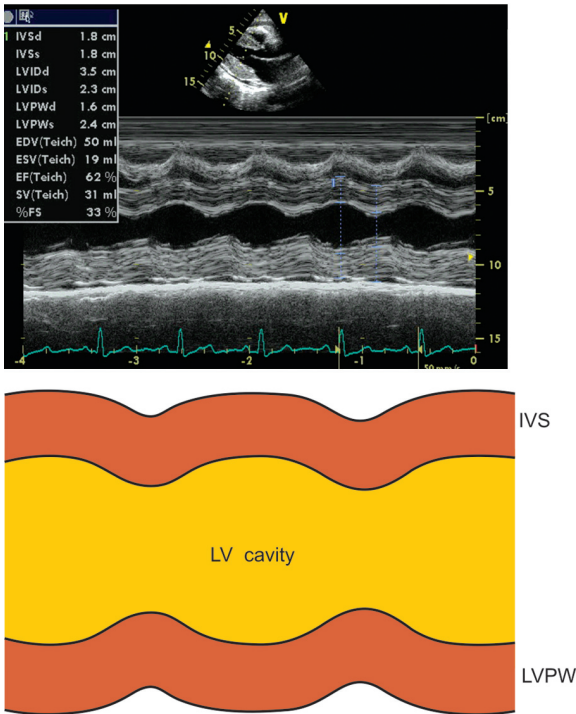


Fig. 9.1: M-mode scan of the left ventricle showing thickening of the IV septum and LV posterior wall

- Normally the ratio of IVS : LVPW thickness is 1:1. Hypertrophy of the IVS to a greater extent than that of the LVPW indicates asymmetrical septal hypertrophy (ASH).
- If there is ASH in hypertension, the IVS : LVPW ratio is usually in the range of 1.3 to 1.5.
- Small left ventricular cavity less than 36 mm in diameter during diastole. Thickening of the IVS and LVPW leads to obliteration of the LV cavity in systole.

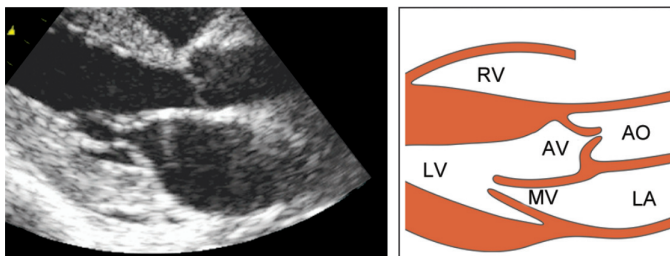


Fig. 9.2: PLAX view showing obliteration of left ventricular cavity due to thickening of the septum and posterior wall

- The normal left ventricular end-diastolic dimension (LVEDD) is 36 to 52 mm (Fig. 9.2).
- Since the LV systolic function is usually good, the amplitude of wall motion is normal.
- Thick papillary muscles with prominent trabeculae carneae are seen parallel to the LV posterior wall.
- There is an increase in the left ventricular mass. The LV mass (in grams) is calculated by the equation:

$$\text{LV mass} = 1.05 [(IVS + LVPW + LVEDD)^3 - LVEDD^3] - 14$$
 - IVS: diastolic thickness of the IV septum
 - LVPW: diastolic thickness of posterior wall
 - LVEDD: end-diastolic dimension of ventricle.
- LV mass can also be calculated by subtracting LV endocardial volume (LVV endo) from the LV epicardial volume (LVV epi) and multiplying it by the density of the myocardium which is 1.05 g/cm³ (mass = volume × density) (Fig. 9.3).

$$\text{LV mass} = [\text{LVV epi} - \text{LVV endo}] \times 1.05$$

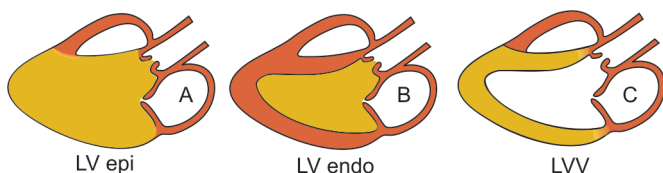


Fig. 9.3: Calculation of the LV mass from LV volume:
 LV epicardial volume (A) minus
 LV endocardial volume (B)
 is equal to LV volume (C)

- In the presence of LV hypertrophy, the LV mass exceeds 136 grams in men and 112 grams in women per meter square body surface area (m^2 BSA).
- In LV hypertrophy due to hypertension, the increase in wall thickness occurs at the expense of reduction in cavity size. This is known as concentric LVH.
- In concentric LVH, the relative wall thickness (RWT) ratio, which is LVPW thickness divided by LV radius in diastole, exceeds 0.45.

Differential Diagnosis of LVH

- The echo picture of LVH due to hypertension is simulated by LVH due to other conditions causing LV pressure overload namely aortic valve stenosis and coarctation of aorta.
- The asymmetrical septal hypertrophy (ASH) in hypertension may resemble ASH observed in case of hypertrophic cardiomyopathy (HOCM).
- However, the IVS : LVPW ratio in hypertension is generally in the range of 1.3 to 1.5 while it exceeds 1.5 in HOCM.
- Myocardial thickening with LV diastolic dysfunction is also observed in restrictive cardiomyopathy (RCMP) and myocardial infiltrative diseases.

- These can be differentiated from the effects of systemic hypertension by the lack of coexisting coronary arterial, valvular and aortic abnormalities.
- Systemic hypertension, aortic stenosis and coarctation of aorta cause LV pressure overload. Mitral and aortic regurgitation, chronic anemia and chronic renal failure cause LV volume overload.
- In conditions causing LV volume overload, there is predominant LV dilatation with a mild degree of LVH. In these conditions there is eccentric LVH which is inadequate for the degree of LV dilatation.
- The relative wall thickness (RWT) ratio, which is LVPW thickness divided by LV radius in diastole, is less than 0.45.
- In eccentric LV hypertrophy, the degree of LVH, as determined only from wall thickness, may be underestimated. However, the left ventricular muscle mass is increased.
- Therefore, LV muscle mass is a better indicator of LV hypertrophy than LV wall thickness.
- Increase in LV mass precedes increase in blood pressure. LV diastolic dysfunction precedes LV systolic dysfunction.

Clinical Significance of LVH

- Presence of LVH is the most common abnormality on echo in a hypertensive patient. Systemic hypertension is also the most important cause of LVH.
- LVH is an independent predictor of cardiovascular morbidity and 10-year mortality as a risk factor for myocardial infarction, heart failure, ventricular arrhythmias and sudden cardiac death. The predictive value of LVH in hypertension is as strong as that of multi-vessel coronary artery disease.
- LVH may be indicated on the ECG by presence of tall QRS complexes. The voltage criteria of S in V_1 or V_2 plus R in V_5 or V_6 greater than 35 mm (Sokolow criteria) is often used.

There may be an associated 'strain pattern' with ST segment depression and T wave inversion in the lateral leads.

- Echocardiography is 5 to 10 times more sensitive than an ECG in the detection of LVH. Precordial findings in LVH are visible aortic pulsations, heaving apex beat, ejection systolic murmur and a loud aortic component (A_2) of the second heart sound (S_2).
- Presence of LVH can be used as an indication for treatment of young patients having borderline or labile hypertension. In them, echo is also useful to look for coarctation of aorta.
- Serial echos may be performed annually to monitor the progress of hypertensive heart disease and to assess the regression of LVH with antihypertensive drugs.



10

Pulmonary Hypertension

Pulmonary arterial hypertension (PAH) is far less common than systemic hypertension and is often a consequence of chronic lung disease.

DETECTION OF PULMONARY HYPERTENSION

M-Mode PV Level

- The pulmonary valve leaflet shows flattening or loss of the normal presystolic 'a' wave.
- Due to high pulmonary artery pressure, right atrial contraction in pre-systole has no effect on the pulmonary valve.
- There is a mid-systolic notch due to brief closure of the valve in early systole and reopening in late systole (Fig. 10.1)
- The ratio between pre-ejection period (PEP) and right ventricular ejection time (RVET) exceeds 0.4.
- This is due to prolonged isovolumic RV contraction since the right ventricular pressure takes longer to exceed the raised pulmonary artery pressure.

2-D Echo PLAX View

- There is dilatation of the right ventricle more than 23 mm with RV hypertrophy, where the RV free wall thickness is more than 5 mm (Fig. 10.2).

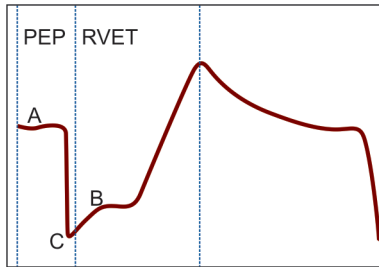


Fig. 10.1: M-mode tracing of the pulmonary leaflet showing:

- flattened 'a' wave
 - mid-systolic notch
 - prolonged pre-ejection period (PEP) prior to RV ejection time (RVET)
- Paradoxical motion of interventricular septum (IVS) is observed. The IVS moves away from the left ventricle and towards the right ventricle in systole (Fig. 10.2).
 - The IVS seems to be a part of the right ventricle which here, has a greater stroke volume than the left ventricle.

2-D Echo PSAX View

- The pulmonary artery is dilated. The diameter of the pulmonary artery exceeds the width of the aorta.
- In this view, the main pulmonary artery, with its right and left branches, gives a “pair of trousers” appearance (Fig. 10.3).
- At the level of the mitral valve, associated mitral stenosis may be diagnosed.

2-D Echo AP4CH View

- In this view, there is dilatation of the right ventricle and the right atrium. The enlarged right ventricle loses its triangular shape and becomes globular.

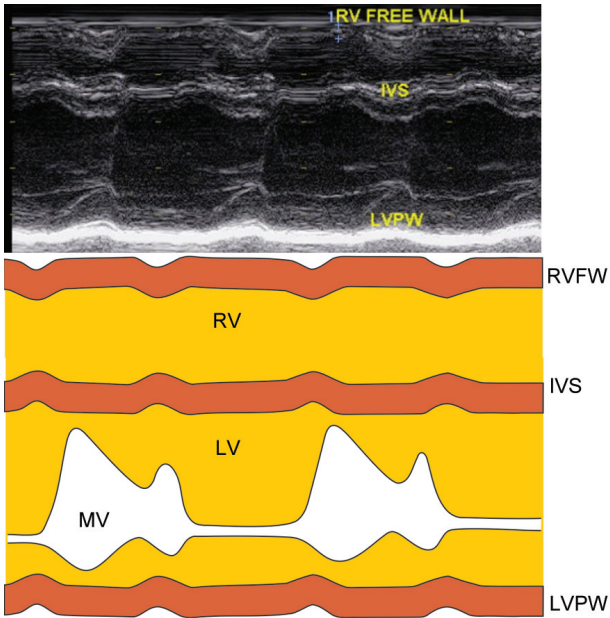


Fig. 10.2: M-mode scan of the ventricles showing:

- dilatation of the right ventricle
- paradoxical motion of septum

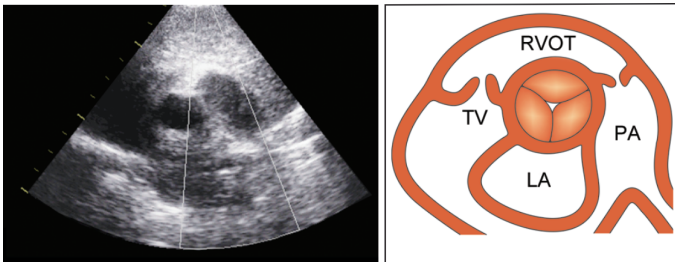


Fig. 10.3: PSAX view showing a dilated pulmonary artery

- The presence of an atrial septal defect or ventricular septal defect may be picked up.

Doppler Echo

- A jet of pulmonary regurgitation (PR) may be observed in the right ventricular outflow tract (RVOT) on color flow mapping.
- On PW Doppler, a high velocity signal is picked up just below the pulmonary valve.

ESTIMATION OF PULMONARY HYPERTENSION

- The pulmonary artery pressure can be estimated from the trans-tricuspid flow velocity (V_{max}). This is obtained by a Doppler spectral display of tricuspid regurgitant jet in the apical 4-chamber view (Fig. 10.4).

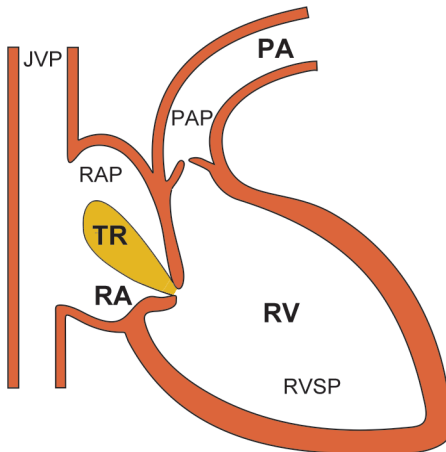


Fig. 10.4: The principle of estimating pulmonary artery pressure from the tricuspid regurgitant jet

- Pulsed wave (PW) Doppler provides a better quality spectral trace although continuous wave (CW) Doppler can pick up higher velocities.

Doppler Calculations

RV pressure (RVP) minus RA pressure (RAP) is equal to pressure gradient (PG) across the tricuspid valve.

$$RVP - RAP = PG$$

$$RVP = PG + RAP$$

$$RVP = 4 V^2 + RAP$$

RV pressure (RVP) is equal to the pulmonary artery pressure (PAP), in the absence of pulmonary stenosis.

Right arterial pressure (RAP) can be estimated from the jugular venous pressure (JVP) measured clinically.

$$RAP = \frac{5 \text{ JVP}}{1.36}$$

- 1.36 converts venous pressure in cm H₂O to mm Hg
- 5 is jugular venous pressure upto the angle of Louis

RAP can also be calculated from the inferior vena cava diameter in expiration (Fig. 10.5) and percentage collapse of IVC in inspiration, as shown in Table 10.1.

If the trans-tricuspid V_{\max} exceeds 2.5 m/sec with a RAP of 5 mm or more, the pulmonary artery pressure (PAP) is elevated above 30 mm as per the following calculations:

$$PAP = 4 \times (2.5)^2 + RAP$$

$$PAP = 4 \times 6.25 + RAP$$

$$PAP = 25 + 5 = 30 \text{ mm}$$

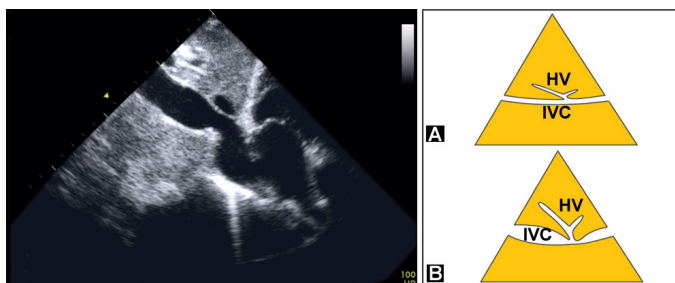


Fig. 10.5: Dilatation of the inferior vena cava (IVC) due to pulmonary arterial hypertension:
 A. Normal dimension
 B. Dilated vena cava

TABLE 10.1

Estimating right atrial pressure from the inferior vena cava

<i>IVC diameter (expiration)</i>	<i>% collapse (inspiration)</i>	<i>Right atrial pressure</i>
< 1.5 cm	100	< 5 mm
1.5–2.0 cm	> 50	5–10 mm
>2.0 cm	> 50	10–15 mm
>2.0 cm	< 50	15–20 mm

- The normal pulmonary artery systolic velocity profile on Doppler is symmetrical and bullet shaped.
- In the presence of pulmonary hypertension, the velocity profile is asymmetrical with early peaking and a short acceleration time (AT) (Fig. 10.6).
- An extremely short time to peak pulmonary velocity (AT less than 80 m/sec) is indicative of severe pulmonary hypertension (Table 10.2).

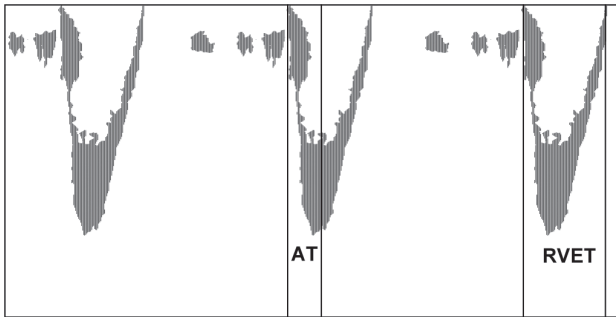


Fig. 10.6: Pulmonary artery velocity profile with early rapid peaking (short acceleration time) due to pulmonary hypertension
 AT : acceleration time
 RVET : RV ejection time

TABLE 10.2

Pulmonary artery hypertension and acceleration time

<i>PAH</i>	<i>AT (m/sec)</i>
Nil	> 120
Mild	100–120
Moderate	80–100
Severe	< 80

- The mean pulmonary artery pressure (PAP) can be calculated using the formula:

$$\text{PAP (mm Hg)} = 80 - \frac{1}{2} \text{AT (m/sec)}$$

Causes of Pulmonary Hypertension

- *Increased pulmonary flow*
 - atrial septal defect
 - ventricular septal defect
 - patent ductus arteriosus.
- *Chronic respiratory disease*
 - obstructive airway disease
 - restrictive lung disease
- *Elevated left atrial pressure*
 - mitral valve disease
 - left ventricular dysfunction
- *Pulmonary vascular disease*
 - veno-occlusive disease
 - chronic thromboembolism
- *Primary pulmonary hypertension.*

Differential Diagnosis of PAH

- Pulmonary hypertension is a cause of right ventricular pressure overload. This is characterized by RV dilatation with or without RV hypertrophy and paradoxical IVS motion.
- A similar picture is observed in pulmonary stenosis with the difference that there is thickening and doming of pulmonary leaflets and the 'a' wave is prominent. (see Valvular Diseases)
- Pulmonary hypertension also needs to be differentiated from right ventricular volume overload due to tricuspid regurgitation or a ventricular septal defect.
- The situation is similar to differentiation between effects of systemic arterial hypertension on the left ventricle from those of mitral and aortic regurgitation.

- Causes of RV volume overload are flow from:
 - left atrium : atrial septal defect (ASD)
 - right atrium : tricuspid regurgitation (TR)
 - pulmonary artery : pulmonary regurgitation (PR)
 - left ventricle : ventricular septal defect (VSD)
 - aortic root : rupture sinus of Valsalva (SOV).
- A combination of a left-to-right shunt with pulmonary hypertension is referred to as Eisenmenger reaction. The level of shunt may be an atrial septal defect (ASD), a ventricular septal defect (VSD) or a patent ductus arteriosus (PDA).
- Besides pulmonary stenosis and RV volume overload, pulmonary hypertension needs to be differentiated from other causes of paradoxical IVS motion such as:
 - constrictive pericarditis
 - post cardiac surgery
 - left bundle branch block
 - old septal infarction.
- Dilatation of the pulmonary artery observed in pulmonary hypertension is also seen in other conditions such as:
 - pulmonary stenosis (post-stenotic)
 - RV volume overload : VSD, ASD, TR.
 - idiopathic dilated pulmonary artery.

Clinical Significance of PAH

- Pulmonary hypertension can occur due to a variety of congenital cardiac, acquired valvular, chronic respiratory and pulmonary vascular diseases.
- In a left-to-right shunt, initially there is right ventricular volume overload and dilatation. With obliterative changes appearing in the pulmonary vasculature, vascular resistance rises and pulmonary hypertension develops.

- A combination of a left-to-right shunt with pulmonary hypertension is known as Eisenmenger reaction. When right-sided pressure exceeds left-sided pressure, there is a reversal of shunt from right-to-left.
- The long-term prognosis of patients with chronic respiratory ailments such as chronic obstructive pulmonary disease (COPD) and interstitial lung disease (ILD) depends upon the presence of pulmonary hypertension and cor pulmonale, which carry a poor prognosis.
- Idiopathic pulmonary hypertension in young females closely resembles rheumatic mitral valve disease with secondary pulmonary hypertension. Both these conditions may present with dyspnea, fatigue and syncope.
- Pulmonary hypertension is diagnosed clinically by visible pulmonary arterial pulsations, palpable parasternal heave, audible pulmonary ejection, murmur and a loud pulmonary component (P_2) of the second heart sound (S_2).



11

Diseases of Aorta

The proximal portion of the ascending aorta, the aortic root, is intimately related to the aortic valve and the left ventricle. The aortic root should therefore be carefully examined.

Normal Aortic Dimensions

Aortic diameter is measured at various levels (Fig. 11.1).

Aortic annulus	17-25 mm
Sinus of Valsalva	22-36 mm
Sinotubular junction	18-26 mm
Aortic root width	20-37 mm

Diameter of Aortic Annulus

The aortic annulus diameter is measured for these reasons:

- to calculate the cardiac output from the area of the aortic valve (see Ventricular Dysfunction)
- to determine the aortic valve area in aortic stenosis and to quantify aortic regurgitation from the width of the Doppler jet (see Valvular Diseases).
- to select the correct size of a prosthetic valve at the aortic position (Fig. 11.2).

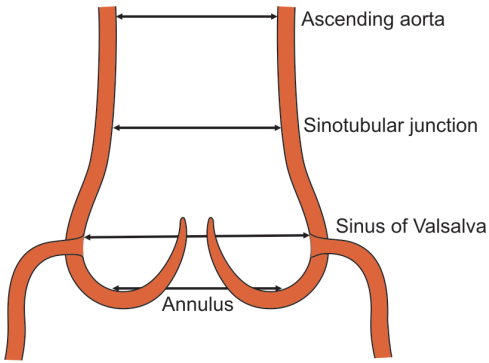


Fig. 11.1: Various dimensions of the proximal aorta

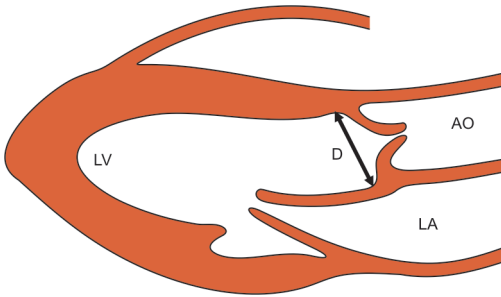


Fig. 11.2: Measurement of aortic annulus diameter from the PLAX view

Anterior Aortic Swing

- Normally the aorta swings anteriorly by 7 to 15 mm during left atrial filling in diastole.
- An anterior aortic swing lesser than 7 mm indicates a low cardiac output state and greater than 15 mm suggests a hyperdynamic circulation.

SINUS OF VALSALVA ANEURYSM

- A congenital aneurysm may involve one of the three sinuses of Valsalva at the aortic root. It is most common in the right sinus, less common in the non-coronary sinus and least common in the left sinus.
- On the long-axis view, the aneurysm appears as an outpouch, anterior to the aortic root and protruding into the right ventricular outflow tract (RVOT).
- On M-mode scan, additional echo lines are seen outside and anterior to the tracing of the aortic root.
- On the short-axis view at the aortic valve level, the aneurysm is visualized as an additional cavity anterior to the aortic valve (Fig. 11.3).

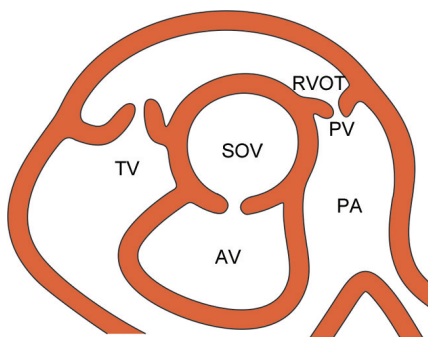


Fig. 11.3: Aneurysm of sinus of Valsalva (SOV) anterior to the aortic valve (AV) protruding into the RV outflow tract (RVOT)

- Rupture of the aneurysm into the right ventricle produces right ventricular volume overload.
- PW Doppler and color flow mapping can detect a flow signal in and out of the aneurysmal cavity, from the aorta into the right ventricle.
- Aneurysm of sinus of Valsalva or the fistula created by its rupture is best visualized on transesophageal echo.
- Abnormalities associated with an aneurysm of the sinus of Valsalva include:
 - bicuspid aortic valve
 - coarctation of aorta
 - ventricular septal defect.

DILATATION OF AORTA

- The normal diameter of the proximal aorta (aortic root), at the end of diastole, ranges from 20 to 37 mm.
- Dilatation of aorta beyond 40 mm (Fig. 11.4) is observed in:
 - Atherosclerosis Aortic unfolding (old age)
Systolic hypertension
 - Medial necrosis Marfan's syndrome
Ehlers-Danlos syndrome

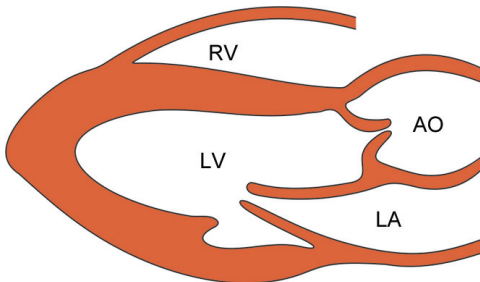


Fig. 11.4: PLAX view showing dilatation of the aortic root

- Aortitis Syphilitic (now rare)
 Tubercular arteritis
 Takayasu's disease
 - Collagenosis Reiter's syndrome
 Ankylosing spondylitis.
 - Post-stenotic Aortic stenosis.
- In aortic dilatation due to old age or hypertension, the aortic annulus and sinus of Valsalva are normal in diameter.
 - In medial necrosis, aortitis and collagen diseases, they are dilated and associated with aortic regurgitation.
 - In post-stenotic aortic dilatation, there are associated features of aortic valve stenosis.

ANEURYSM OF AORTA

- Dilatation of the aortic root beyond 60 mm is observed in aneurysmal widening of the aorta which may be saccular or fusiform. The aortic aneurysm appears as a balloon-like stretching of the aortic wall (Fig. 11.5).
- The dilated aorta compresses the left atrium and expands in systole. The aortic cusps appear distant from the aortic walls even when the valve is open in systole. There may be an associated laminated thrombus.

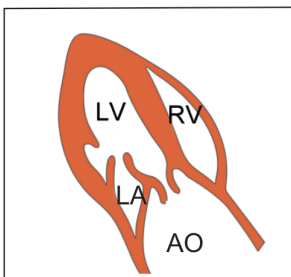
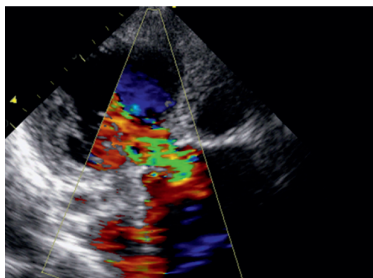


Fig. 11.5: PLAX view showing aneurysmal dilatation of the aorta

- Causes of aortic aneurysm are:
 - atherosclerosis
 - syphilitic aortitis
 - Marfan's syndrome
 - mycotic aneurysm
 - post-traumatic aneurysm.

COARCTATION OF AORTA

- In coarctation of the aorta, there is a localized congenital reduction of the descending aortic diameter.
- The narrowing is in the juxta-ductal area (near the ductus arteriosus) at the level of isthmus.
- It is proximal to the ligamentum arteriosum in pre-ductal (infantile) and distal to it in post-ductal (adult-life) coarctation.
- There is post-stenotic dilatation of the descending aorta beyond the site of narrowing.
- The effects of aortic coarctation on the left ventricle are similar to those of systemic hypertension and aortic valve stenosis.
- Left ventricular hypertrophy occurs due to LV systolic (pressure) overload.
- There is thickening of the IV septum and LV posterior wall exceeding 12 mm with good LV systolic function. (see Systemic Hypertension).
- The narrowing of the aorta is detected from the suprasternal notch. The aortic arch is more pulsatile proximal to the coarctation than distal to it (Fig. 11.6).
- On pulsed wave (PW) Doppler, with the sample-volume moving gradually down the aortic arch, high velocity flow is detected distal to the site of narrowing.

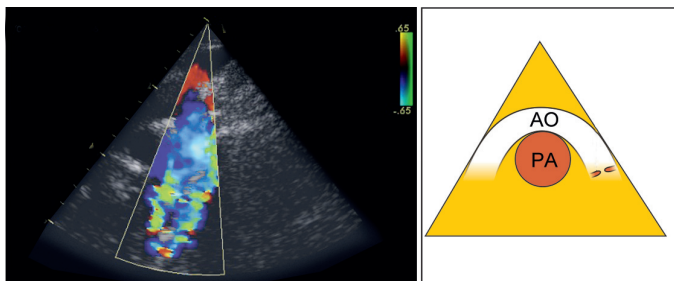


Fig. 11.6: Coarctation of the aorta observed from the suprasternal notch

- A discrete shelf-like structure is seen attached to the aortic wall, distal to the origin of the left subclavian artery.
- On pulsed wave (PW) Doppler, with the sample-volume moving gradually down the aortic arch, high velocity flow is detected distal to the narrowing site.
- On continuous wave (CW) Doppler, there is a high velocity jet away from the transducer from which the pressure gradient across the coarctation can be determined.
- On color-flow mapping, a mosaic pattern is seen in the descending aorta, as flow crosses the coarctation.
- Detection of retrograde diastolic flow in the aorta indicates a severe form of coarctation.
- Abnormalities associated with coarctation of aorta are:
 - VSD and PDA
 - bicuspid aortic valve
 - aneurysm sinus of Valsalva
- In pseudo-coarctation of the aorta, there is only tucking at the ligamentum arteriosum without luminal narrowing.
- In a condition known as hypoplastic aorta, there is diffuse narrowing of the entire aortic lumen.

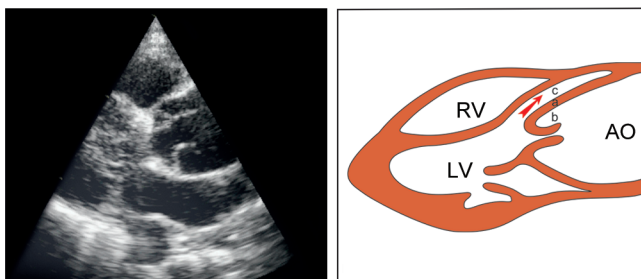


Fig. 11.7: Dissection of aorta in the anterior aortic wall. An intimal flap (a) separates the true lumen (b) from the false lumen (c)

DISSECTION OF AORTA

- Dissection of aorta is caused by cleavage of the media of the aortic wall with the adventitia and outer media forming the outer wall and the intima and inner media forming the inner wall (Fig. 11.7).
- A false lumen appears between the two walls which has one blind end while the other end communicates with the true lumen at the site of the tear.
- The intimal flap oscillates between the true and false lumens. Anterior or posterior aortic dissection causes duplication of trace-line of the involved aortic wall (Fig. 11.8).
- Classical echo features of aortic dissection are:
 - enlargement of aortic root diameter > 42 mm
 - anterior or posterior wall thickness > 15 mm
 - duplicated trace-line of the involved aortic wall
 - distance between outer and inner wall > 5 mm
 - false lumen within aortic wall with a blind end.
 - intimal flap between the true and false lumen.

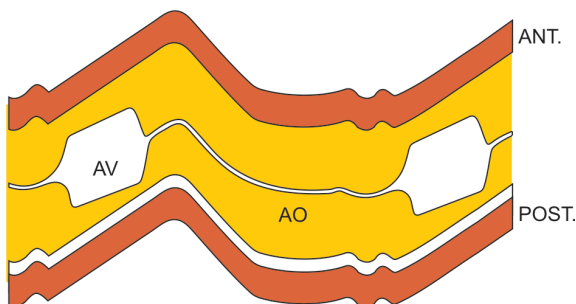


Fig. 11.8: Dissection of aorta involving the posterior aortic wall

- Associated echo features of aortic dissection are:
 - occlusion of neck vessels
 - aortic valve regurgitation
 - left ventricular dysfunction
 - myocardial infarction
 - pericardial effusion
- Causes of distortion of aortic root are:
 - intimal flap in aortic dissection
 - aneurysm of sinus of Valsalva
 - aortic root abscess in endocarditis
- Transesophageal echo is the best technique for the diagnosis of aortic dissection at any level. Dissection of the descending aorta can only be identified by this method.
- Dissection of the ascending aorta can be seen from the suprasternal notch. This view can also visualized the origin of left carotid, left subclavian and the innominate arteries.
- Aortic dissection can be classified according to its location as given in Table 11.1.

TABLE 11.1**Classification of aortic dissection according to its location**

<i>De Bakey type</i>	<i>Stanford group</i>	<i>Location of dissection</i>	<i>Incidence</i>
I	A	Ascending to descending aorta	10%
II		Confined to ascending aorta	70%
III	B	Confined to descending aorta	20%

Causes of Aortic Dissection

- Marfan's syndrome
- Coarctation of aorta
- Hypertension in pregnancy
- Trauma; accidental or surgical.

Echo Features of Marfan's Syndrome

- Aortic root dilatation
- Aneurysm of aorta
- Aortic dissection
- Aortic regurgitation
- Mitral valve prolapse.



12

Congenital Diseases

Echo is the first-line and indispensable investigation for the diagnosis of congenital heart diseases. Not only it can localize an anatomical abnormality but also provide information about the effects of the abnormality on cardiac chambers and can quantify intracardiac pressures.

In fact echocardiography has obviated the need for cardiac catheterization, especially since some congenital defects are today amenable to percutaneous catheter-guided closures. Examples of these are closure of an atrial septal defect and patent ductus arteriosus.

Although most congenital heart diseases are diagnosed and dealt with during childhood, some of them are discovered for the first time on echo during adulthood in asymptomatic subjects. Echo is also useful in the follow-up of those patients whose abnormalities have been surgically corrected during childhood.

A detailed description of complex congenital cardiac abnormalities such as transposition of great vessels, is beyond the scope of this book. We shall confine ourselves to a discussion on the following common congenital heart diseases:

- Ventricular septal defect (VSD)
- Atrial septal defect (ASD)

- Patent ductus arteriosus (PDA)
- Tetralogy of Fallot (TOF).

Certain other congenital cardiac abnormalities find mention elsewhere in this book. These are:

- Coarctation of aorta
- Bicuspid aortic valve
- Pulmonary stenosis
- Ebstein's anomaly.

VENTRICULAR SEPTAL DEFECT

In this condition, a breach in the continuity of the interventricular septum (IVS) creates a communication between the left and right ventricles.

Flow of blood from the left ventricle (higher pressure) to the right ventricle (lower pressure) constitutes a left-to-right shunt across the ventricular septal defect (VSD).

VSD may be an isolated lesion or associated with other abnormalities such as tetralogy of Fallot. Rarely, VSD may be acquired following myocardial infarction.

Various types of ventricular septal defects are:

- membranous (infracristal)
- atrioventricular defect
- infundibular (supracristal)
- muscular defect.

2-D Echo

- On 2-D Echo, the left-sided chambers (LA and LV) are dilated, due to increased venous return from the pulmonary circulation. This constitutes left ventricular volume overload.

- On careful inspection of the apical 4-chamber (A4CH) view, there is a discontinuity in the interventricular septum (IVS) with echo drop-out.
- The VSD may be small or large in size and single or multiple. The septal defect may be in the upper membranous portion (base) or in the lower muscular septum (apex).
- An infundibular (supracristal) VSD is located below the pulmonary valve (subpulmonary). An atrioventricular defect is located in the posterior portion of the septum around the tricuspid valve.
- No echo drop-out is observed if the defect is too small (< 3 mm) in size, it is eccentric in direction or if it is muscular in location, which shuts off during contraction in systole.
- Multiple and small defects give the septum a “sieve-like” or “Swiss-cheese” appearance.

Doppler Echo

- On color flow mapping, there is an abnormal flow pattern from the left to right ventricle (Fig. 12.1).

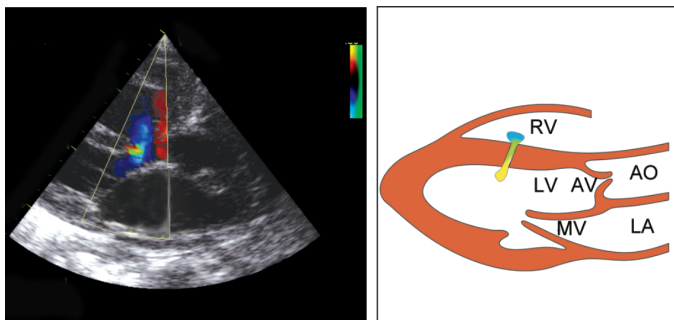


Fig. 12.1: PLAX view showing a color flow map across a ventricular septal defect

- The width of the color flow map approximates the size of the defect and helps in quantitative assessment.
- On continuous wave (CW) Doppler, a high velocity jet is identified across the septal defect. From the velocity (V) of the jet, the pressure gradient (PG) between the LV and RV can be measured (Bernoulli equation: $PG = 4 V^2$).
- High velocity jet with a high pressure gradient is suggestive of a small restrictive VSD in the muscular portion. A shunt may not be demonstrated if it is too small in size, eccentric, of low velocity or bidirectional.
- By pulsed wave (PW) Doppler, the high velocity on CW Doppler and the color flow map, can be localized. The sample volume is placed in the right ventricle alongside the septum, adjacent to the suspected area.
- With a significant volume of left-to-right shunt, there are features of right ventricular volume overload such as right ventricular dilatation beyond 23 mm and paradoxical motion of the IV septum.

Doppler Calculations

- The pulmonary artery pressure can be estimated from the transtricuspid peak flow velocity and pulmonary hypertension can be identified (see Pulmonary Hypertension).
- The quantity of left-to-right shunt can be estimated from the ratio between pulmonary and systemic stroke volume, which is the $Q_p : Q_s$ ratio.
- Q_s is aortic outflow and Q_p is pulmonary outflow. Q_p is greater than Q_s since a portion of the left ventricular output goes to the right ventricle.

ATRIAL SEPTAL DEFECT

In this condition, a breach in the continuity of the interatrial septum (IAS) creates a communication between the left and right atria.

Flow of blood from the left atrium (higher pressure) to the right atrium (lower pressure) constitutes a left-to-right shunt across the atrial septal defect (ASD).

Various types of atrial septal defects are:

- ostium secundum defect
(the most common type)
- ostium primum defect
(endocardial cushion defects)
- sinus venosus defect
(anomalous pulmonary veins)

2-D Echo

- On 2-D echo, the right-sided chambers (RA and RV) are dilated due to increased venous return from the systemic circulation as well as the left atrium. This constitutes right ventricular volume overload.
- On careful inspection of the apical 4-chamber (A4CH) view, there is a discontinuity in the interatrial septum (IAS) with an echo drop-out.
- Since the IAS is thin and parallel to the scanning beam, the reflected echo signal from the IAS is weak. Therefore, standard parasternal and apical views are not reliable for the diagnosis of ASD.
- False-positive echo drop-out may be observed even in normal individuals in the region of the foramen ovale, where the covering thin membrane may not be visualized.
- A true septal defect can be differentiated from a false echo drop-out by examining the edges of the septum at the margins of the defect. In a true defect, the edges are bright and thick (the T sign) while in a false defect the edges are thin and they fade gradually.

- The subcostal view is better for examining the IAS since it is perpendicular to the scanning beam. Transesophageal echo allows excellent visualization of the IAS and thus a more accurate diagnosis of ASD and patent foramen ovale.
- The echo drop-out is seen in the middle of the IAS in ostium secundum type of ASD and just above the mitral valve ring in ostium primum type of ASD.
- No echo drop-out is observed in sinus venosus defect with anomalous pulmonary venous drainage (APVD). However, other features of a left-to-right shunt are present.
- With a significant volume of left-to-right shunt, there are features of right ventricular volume overload such as right ventricular dilatation beyond 23 mm and paradoxical motion of the IV septum.
- The parasternal short-axis view at the aortic valve level may show the septal defect and a dilated pulmonary artery.

Doppler Echo

- Doppler study is not a good modality to pick up an ASD because the jet across the defect is of low velocity.
- For the same reason, color flow mapping can detect flow from the left to right atrium in only a minority of atrial septal defects (Fig. 12.2).

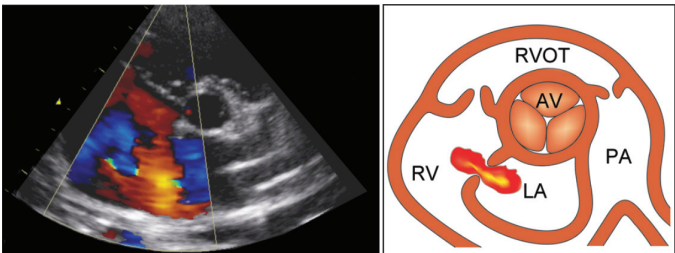


Fig. 12.2: PSAX view showing a color flow map across an atrial septal defect

- An increase in flow velocity across the tricuspid and pulmonary valves may indicate right atrial and right ventricular overload due to the left-to-right shunt.
- In ostium primum type of ASD, there may be associated mitral and tricuspid regurgitation (MR and TR).
- Endocardial cushion defects are associated with cleft leaflets of mitral and tricuspid valves.

Contrast Echo

- Because of the technical difficulties with 2-D echo and the limitations of color flow mapping and Doppler echo, a contrast echo study should be performed if an ASD is strongly suspected on clinical grounds.
- For contrast study, a small bolus of agitated saline with air bubbles, is injected into a peripheral vein. The air bubbles are seen in the right atrium (RA) and they normally enter into the right ventricle.
- The subject is then asked to perform a Valsalva manoeuvre (to increase intrathoracic pressure) when air bubbles are seen shunting from the right to left atrium across the ASD. This is known as the positive contrast effect.
- A negative contrast effect is observed when there is an area of non-contrast in the right atrium (RA), due to washout of contrast by normal blood from the left atrium (LA).

Doppler Calculations

- The pulmonary artery pressure can be estimated from the transtricuspid peak flow velocity and pulmonary hypertension can be identified (see Pulmonary Hypertension).
- A combination of ASD with pulmonary hypertension is known as Eisenmenger reaction.

- The quantity of left-to-right shunt can be estimated from the ratio between pulmonary and systemic stroke volume, which is the $Q_p : Q_s$ ratio.
- Q_s is aortic outflow and Q_p is pulmonary outflow. Q_p is greater than Q_s since a portion of the left atrial output goes to the right atrium.

PATENT DUCTUS ARTERIOSUS

The ductus arteriosus is a channel that connects the descending aorta distal to the origin of left subclavian artery to the left pulmonary artery distal to the bifurcation of main pulmonary artery. The ductus remains open during intrauterine life.

In patent ductus, the ductus fails to close physiologically within 24 hours after birth and anatomically within a week, providing a communication between the aorta and pulmonary artery.

Flow of blood from the aorta (higher pressure) to the pulmonary artery (lower pressure) constitutes a left-to-right shunt across the patent ductus arteriosus (PDA).

2-D Echo

- On 2-D echo, the left-sided chambers (LA and LV) are dilated due to increased venous return from the pulmonary circulation. This constitutes left ventricular volume overload.
- Due to dilatation of left atrium, the ratio between size of the left atrium and proximal aorta (LA : Ao ratio) exceeds 1.3.

Doppler Echo

- On color flow mapping using the PSAX view, there is a retrograde mosaic jet of flow from the left pulmonary artery to the dilated main pulmonary artery (Fig. 12.3).
- On PW Doppler with the sample-volume placed in the pulmonary artery, disturbance of blood flow is seen near the ductus, both in systole and diastole.

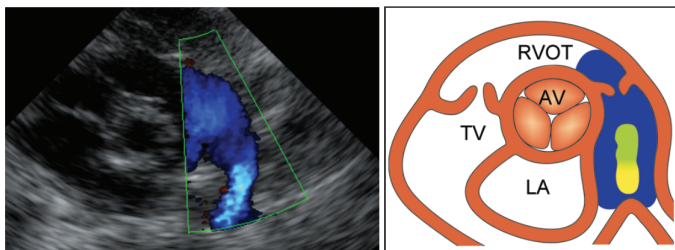


Fig. 12.3: PSAX view showing a color flow map from the left branch to main pulmonary artery

- These flow signals need to be differentiated from the adjacent jet of pulmonary regurgitation (PR) by the fact that in PDA, there is no flow in the RV outflow tract (RVOT).
- On PW Doppler, with the sample-volume moved distally, from the RV outflow tract across the valve and through the pulmonary artery, a sudden increase in systolic flow velocity is detected at or just beyond the level of the ductus.
- These flow disturbances in the pulmonary artery and ductus, on PW Doppler and CF mapping, in systole and diastole, can also be picked up from the supra-sternal window.

Doppler Calculations

- The pulmonary artery pressure can be estimated from the transtricuspid peak flow velocity and pulmonary hypertension can be identified (see Pulmonary Hypertension).
- The quantity of left-to-right shunt can be estimated from the ratio between pulmonary and systemic stroke volume, which is the $Q_p : Q_s$ ratio.
- Q_s is pulmonary outflow or tricuspid inflow before receiving blood from the aorta. Q_p is mitral inflow or aortic outflow after receiving blood from the aorta. Q_p is greater than Q_s since a portion of the aortic outflow goes to the pulmonary artery, through the ductus.

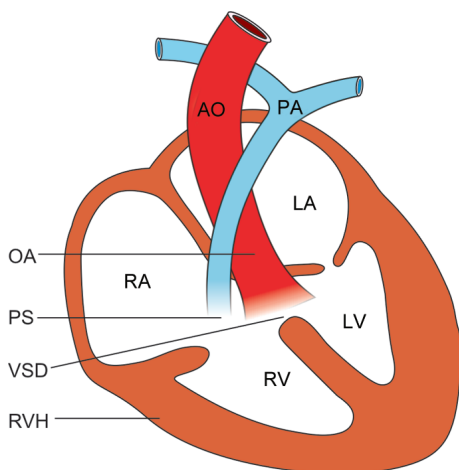


Fig. 12.4: The four components of Fallot's tetralogy

TETRALOGY OF FALLOT

Although discussion of complex congenital cardiac abnormalities is beyond the scope of this book, one condition that deserves mention is tetralogy of Fallot (Fig. 12.4).

The four components of the tetralogy are:

- *Ventricular septal defect (VSD)*

The VSD is usually membranous in location.

- *Overriding of aorta (OA)*

There is rightward displacement of the aorta which thus overrides the IV septum. This results in a discontinuity between the aorta and the IV septum (aorta-septal discontinuity). The IV septum is in line with the aortic valve closure point and not the anterior aortic wall.

- *Pulmonary stenosis (PS)*
RV outflow tract obstruction is often infundibular (subvalvular) and uncommonly valvular pulmonary stenosis.
- *Right ventricular hypertrophy (RVH)*
The right ventricular chamber undergoes hypertrophy in response to pulmonary stenosis. The RV free wall thickness is > 5 mm and there is paradoxical motion of the IV septum. Importantly, the left-sided chambers (LA and LV) are normal or smaller in size in contrast to their larger size in isolated ventricular septal defect.

2-D Echo

- The parasternal long-axis view shows:
 - rightward displaced aorta
 - aortoseptal discontinuity
 - ventricular septal defect
 - right ventricular hypertrophy
- The parasternal short-axis view shows:
 - right ventricular infundibular stenosis
 - thickening of pulmonary valve leaflets
 - hypoplasia of main pulmonary artery.

Doppler Echo

- PW Doppler can detect an increase in flow velocity in the right ventricular outflow tract. It can localize and quantify the outflow obstruction.
- Color flow mapping can reveal a mosaic flow pattern and the level of RV outflow obstruction. In addition, flow across the ventricular septal defect can be visualized.

EISENMENGER REACTION

- When there is a shunt between cardiac chambers or blood vessels, blood will flow from a region of higher pressure (left side) to a region of lower pressure (right side). This constitutes a left-to-right shunt.
- When there is significant quantity of shunting, it leads to right ventricular volume overload and RV dilatation.
- Further, when irreversible changes occur in the pulmonary vasculature, pulmonary vascular resistance rises and pulmonary arterial hypertension occurs.
- A combination of a shunt with pulmonary hypertension is referred to as Eisenmenger reaction.
- Ultimately, when right-sided pressures exceed left-sided pressures, reversal of shunt occurs. This constitutes a right-to-left shunt.
- In the presence of a cardiac shunt, the pulmonary artery pressure can be estimated from the transtricuspid peak flow velocity (V_{\max}).
- Features of right ventricular volume overload include right ventricular dilatation > 23 mm and paradoxical motion of the IV septum.
- When reversal of shunt occurs, color flow mapping shows a bidirectional shunt or a low velocity jet from the right to left side of the defect.

QUANTIFICATION OF SHUNT

- The stroke volume of the left heart and thus the cardiac output (cardiac output = stroke volume \times heart rate) can be calculated from the peak aortic flow velocity.
- This is obtained by Doppler spectral display of aortic outflow tract in the apical 5-chamber view.

- The area under curve of this velocity display is the flow velocity integral (FVI). Multiplying this FVI with the cross-sectional area (CSA) of the aortic valve yields the stroke volume (SV). Cross-sectional area (CSA) is obtained from the diameter (D) of the aortic annulus.

$$\text{Stroke volume} = \text{CSA} \times \text{FVI}$$

$$\text{CSA} = \pi (D/2)^2 = \frac{22}{7} \frac{D^2}{4} = 0.785D^2$$

$$\text{Stroke volume} = 0.785 D^2 \times \text{FVI}$$

- Using similar calculations on the peak pulmonary flow velocity (FVI) and the cross-sectional area (CSA) of the pulmonary valve, the stroke volume of the right heart can be obtained.
- If the quantum of systemic flow is Qs and the quantum of pulmonary flow is Qp, the Qp : Qs ratio is a measure of the quantity of shunt.
- A shunt is considered to be hemodynamically significant if the Qp : Qs ratio exceeds 2.0.

$$\frac{Q_p}{Q_s} = \frac{\text{FVI}_p \cdot D^2_p}{\text{FVI}_s \cdot D^2_s}$$

- In VSD, Qs is AV flow and Qp is PV or MV flow. Part of left ventricular output is lost to the right ventricle. Pulmonary outflow and mitral inflow are the same.
- In ASD, Qs is AV flow and Qp is PV or TV flow. Part of left atrial output is lost to the right atrium. Pulmonary outflow and tricuspid inflow are the same.
- In PDA, Qs is PV or TV flow before receiving blood from the ductus and Qp is MV or AV flow after receiving blood from the ductus. TV inflow and PV outflow are the same. MV inflow and AV outflow are also equal.



13

Valvular Diseases

One of the earliest applications of echocardiography was in the diagnosis of valvular diseases in general and mitral stenosis in particular.

In fact even today, after coronary artery disease and systemic hypertension, suspected disease of cardiac valves is a common indication for requesting an echo.

Often valvular disease is suspected clinically because of a murmur especially if coupled with suggestive symptoms such as dyspnea and palpitation on exertion.

A murmur is the sound produced by turbulent flow due to:

- high volume flow across a normal valve
- high velocity flow across a stenotic valve
- regurgitant flow from an incompetent valve

Sometimes a murmur is caused by an intracardiac left-to-right shunt or the narrowing of a major blood vessel. (see Congenital Diseases).

Echocardiography can confirm the site of origin of a murmur detected clinically. It can anatomically visualize a diseased valve and detect an abnormal pattern of blood flow on color flow mapping.

It can also reveal the etiology of the valvular disease, quantify its severity and assess its effect on dimensions of chambers, intracardiac pressures and on ventricular function.

MITRAL STENOSIS (MS)

Echo Features of MS

2-D Echo PLAX View

- The mitral valve leaflets are thickened due to dense fibrosis, with or without calcification.
- Due to fibrosis, their echogenicity (brightness) is increased and equals that of the pericardium.
- When there is associated calcification, echogenicity exceeds that of the pericardium and there is distal shadowing.
- Instead of a sharp image of leaflets, there is reverberation of echoes with several reflections giving a fuzzy image.
- There is limited excursion of mitral valve leaflets with restricted opening of the valve.
- Due to fusion at the free edges and anterior motion of the body of anterior mitral leaflet (AML), there is diastolic doming of the AML (Fig. 13.1).
- This is described as a “bent-knee motion” or “elbowing” of the AML and has been likened to the bulging of the sail of a boat as it fills with wind.
- There is dilatation of the left atrium (normal size 19-40 mm). The ratio between dimensions of the left atrium and aorta is increased (LA : Ao >1.3).
- There may be a left atrial thrombus especially in the presence of atrial fibrillation.

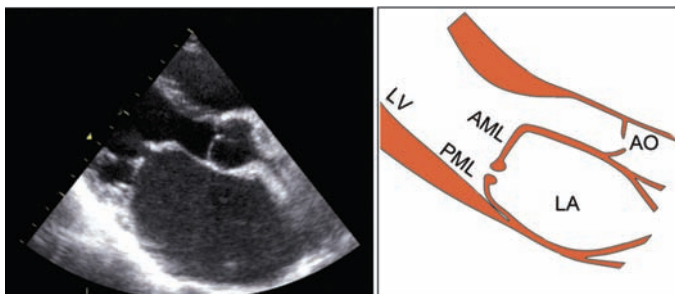


Fig. 13.1: PLAX view of a stenotic mitral valve showing:

- diastolic doming of anterior leaflet
 - thickening of the valve leaflets
 - restricted opening of the valve
 - dilatation of the left atrium
-
- Other causes of LA dilatation are:
 - mitral regurgitation (MR)
 - left ventricular failure (LVF)
 - hypertension in elderly (LVH)
 - long-standing atrial fibrillation (AF)
 - There may be thickening and increased echogenicity of the chordae tendinae if there is an associated subvalvular disease.
 - The mitral valve annulus may be thick and calcified.

M-Mode AV Level

- There is dilatation of the left atrium (normal LA size: 19-40 mm). There may be a left atrial thrombus.
- There may be thickening of aortic valve leaflets due to associated aortic stenosis.

M-Mode MV Level

- The D-E excursion of the anterior mitral leaflet (AML) is reduced to less than 20 mm (normal 20-35 mm).
- Reduced D-E excursion of AML is also observed in conditions where the cardiac output is low.
- There is loss of the normal antiparallel motion of the posterior mitral leaflet (PML) in diastole.
- This is known as paradoxical anterior motion of PML which is pulled towards the AML rather than drifting away from it.
- It occurs because of fusion between the edges of AML and PML with the PML following the larger and more mobile AML.
- There is flattening of the E-F slope (normal 80-120 mm/sec) due to slow left ventricular filling during diastole (Fig. 13.2).
- An E-F slope of 35-50 mm/sec indicates mild MS and if it is less than 35 mm/sec, severe MS is implied.
- Flattening of E-F slope is also seen with reduced left ventricular compliance and diastolic dysfunction.

M-Mode LV Level

- In pure mitral stenosis, left ventricular dimension and function are normal. If there is associated mitral regurgitation, there are features of left ventricular volume overload.
- When mitral stenosis leads to pulmonary hypertension, there is dilatation of the right ventricle (more than 23 mm) and paradoxical motion of the interventricular septum. (see Pulmonary Hypertension).

2-D Echo PSAX View

- At the aortic valve level, there may be thickening of the cusps due to associated aortic valve stenosis.

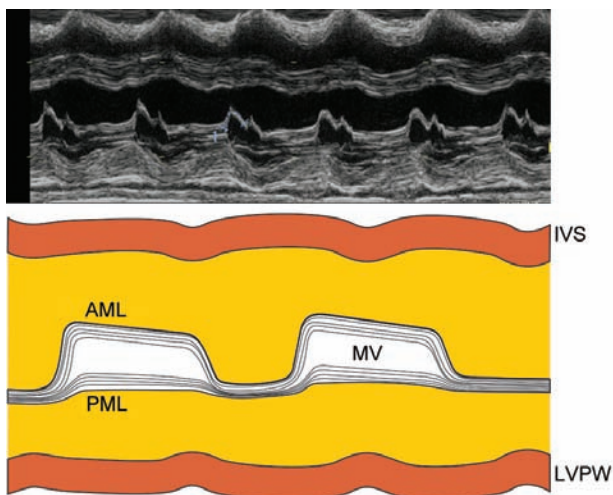


Fig. 13.2: M-mode scan of a stenotic mitral valve showing:

- reverberation of echoes from the valve
 - reduced anterior excursion of the AML
 - paradoxical anterior motion of the PML
 - flattening of the E-F slope of the AML
- The enlarged left atrium is visualized along with its appendage in this view. There may be a thrombus in the left atrium or in its appendage.
 - At the mitral valve level, there is thickening and reduced excursion of mitral leaflets. The normal 'fish-mouth like' opening of the mitral valve orifice is restricted (Fig. 13.3).
 - At this level, the mitral valve area can be measured by planimetry (tracing of the valve orifice area).
 - The normal mitral orifice area is 4-6 cm² or 3 cm² per square meter body surface area (BSA).

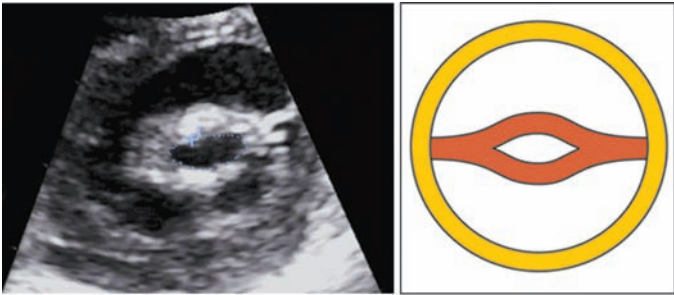


Fig. 13.3: PSAX view of a stenotic mitral valve showing reduced mitral valve orifice size

Color Flow Mapping

- On the A4CH view, there is a “candle-flame” like jet with aliasing, at the mitral valve plane (Fig. 13.4).
- The jet extends lower down beyond the MV plane and is eccentric if there is significant subvalvular disease.
- The width of the color flow jet approximates the diameter of the valve and indicates the severity of MS.

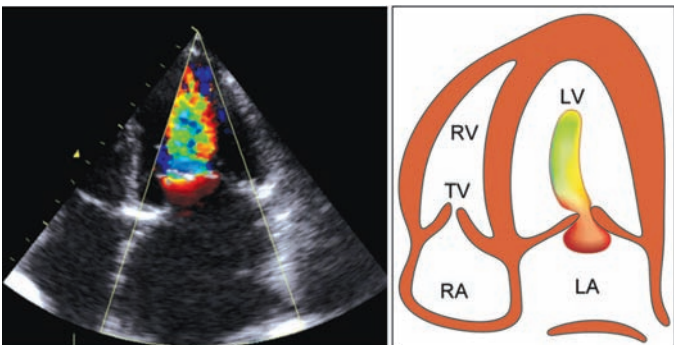


Fig. 13.4: Color flow map of a stenotic mitral valve from A4CH view showing a “candle-flame” shaped jet

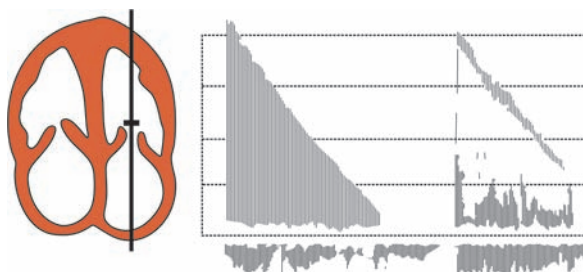


Fig. 13.5: PW Doppler of mitral valve from A4CH view showing increased diastolic flow velocity

Doppler Echo

- On PW Doppler from the A4CH view with the sample volume in LV, the MV inflow spectral trace shows an increased peak diastolic flow velocity exceeding 1 m/sec (normal velocity is 0.6-1.4 m/sec; mean 0.9 m/sec).
- There is a slow decay of the velocity with a flat slope of deceleration (Fig. 13.5). The mean pressure gradient across the valve exceeds 4 mm Hg.

Doppler Calculations

- Because of the stenosed valve, the time taken for the pressure gradient across the valve to fall, is prolonged. Greater the degree of stenosis, more is the prolongation (Fig. 13.6).
- This fact is utilized to estimate the mitral valve area from the pressure half-time. The pressure half-time is the time taken for the peak pressure gradient to fall by half.
- In view of the square relationship between pressure and velocity (Bernoulli Equation: $P = 4V^2$), the pressure half-time is the time taken for the peak velocity to fall to 0.7 of its original value (Fig. 13.7).

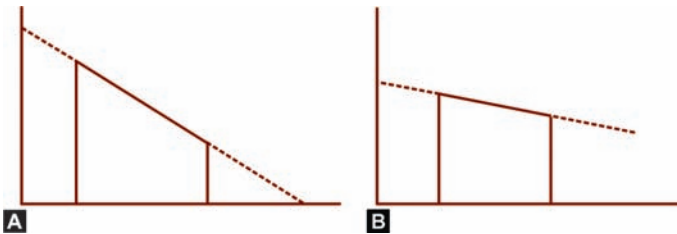


Fig. 13.6: Relationship between rate of deceleration and the severity of mitral stenosis:
 A. Steep slope: mild MS
 B. Flat slope: severe MS

Since P is related to V^2

$\frac{1}{2} P$ is related to $\frac{V^2}{2}$

$\frac{V^2}{2} = V/\sqrt{2} = V/1.4 = V \times 0.7$

MV area (cm^2) = $220/P$ half-time (millisec)
 220 is the Hatle's constant

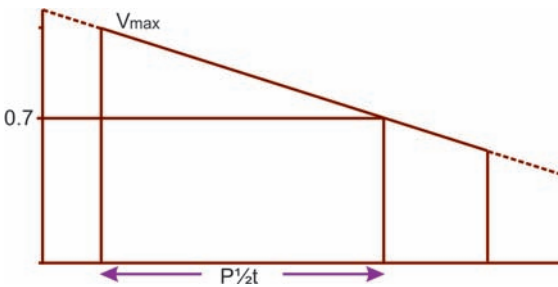


Fig. 13.7: The principle of calculating pressure half-time
 V_{max} : peak flow velocity
 $P \frac{1}{2} t$: pressure half-time

Note

- This formula should not be applied in mild mitral stenosis ($P_{1/2} < 150$ millisecond) since the $P_{1/2}$ is then related to the diastolic behavior of the left atrium.
- In the presence of atrial fibrillation, the duration of diastole varies from beat-to-beat. Therefore, a number of beats should be used for calculation and the average value of MV area should be taken.
- The pulmonary artery pressure can be estimated from the transtricuspid flow velocity (V_{max}) obtained from the Doppler spectral display added to the right atrial pressure.
- A V_{max} more than 2.5 m/sec is indicative of pulmonary hypertension (see Pulmonary Hypertension).

Pitfalls in the Diagnosis of MS

- Some of the echo features of mitral stenosis are not specific for this condition. Limited excursion of mitral valve leaflets with restricted valve opening is also observed in conditions where the cardiac output is low.
- Diastolic doming of the AML is also due to redundant leaflet tissue in mitral valve prolapse and vegetations on the free edge of AML in endocarditis.
- Reduced D-E excursion may also be due to low cardiac output and flattening of the E-F slope may occur with reduced left ventricular compliance.
- For measurement of mitral valve area by planimetry, the short axis cut must be taken at the level of leaflet edges, which is the smallest area. Taking the cut at the level of leaflet doming may falsely suggest a larger area.
- It may be difficult to trace the orifice accurately if the lumen is irregular and there are reverberation artefacts due to heavy calcification. In that case, the severity of mitral stenosis is likely to be overestimated.

- The transmitral peak velocity and pressure gradient depend upon the heart rate and stroke volume. These are over-estimated in the presence of tachycardia (shorter diastole) and a high output state (greater blood flow).
- Conversely, the velocity and pressure gradient are reduced in the presence of bradycardia and a low output state.
- Fallacies in measuring MV area by planimetry are:
 - poor visualization of MV orifice
 - heavy calcification of leaflets
 - significant subvalvular disease
 - prior commissurotomy procedure
 - low cardiac output condition.

Assessing Severity of MS

- Direct indicators of severe MS are:
 - heavily calcified leaflets
 - severe restriction of motion
- Indirect indicators of severe MS are:
 - left atrial dilatation
 - pulmonary hypertension
- The severity of MS as per mitral valve area (MVA), pressure half-time ($P_{1/2}$) and transtricuspid velocity ($TR V_{max}$) can be graded as shown in Table 13.1.

Criteria for Severe MS

Numerical criteria for severe MS are:

- | | |
|---------------------------|---------------------|
| • MV orifice area | < 1 cm ² |
| • Pressure gradient | > 10 mm Hg |
| • Pressure half-time | > 220 msec |
| • Tricuspid flow velocity | > 3 m/sec |
| • Pulmonary pressure | > 30 mm Hg |

TABLE 13.1**MS severity from pressure half-time and transtricuspid velocity**

Severity of MS	MVA (cm^2)	$P \frac{1}{2} t$ (msec)	TR Vmax (m/sec)
Mild MS	1.5–2.5	< 150	< 2.7
Moderate MS	1.0–1.5	150–220	2.7–3.0
Severe MS	< 1.0	> 220	> 3.0

Causes of Mitral Stenosis

Practically speaking, the commonest cause of MS is rheumatic heart disease.

Rare causes of mitral stenosis are:

- mitral annulus calcification (in the elderly)
- congenital mitral stenosis (parachute valve)
- connective tissue disorders (SLE, rheumatoid)
- mucopolysaccharidosis (Hurler's syndrome)

Other rare causes of mitral inflow obstruction are:

- left atrial myxoma
- left atrial thrombus
- supralvalvular ring
- cor triatriatum.

Suitability for Valvotomy in MS

Often, conventional echocardiography is performed in a known case of mitral stenosis, to assess whether the valve is suitable for balloon valvotomy. This is a specialized judgment that also requires transesophageal echo.

In general, a valve is suitable for balloon valvotomy if there is significant mitral stenosis but none of the following associated conditions:

- immobility of leaflet base
- thickening of the chordae
- commissural calcification
- more than mild MR
- left atrial thrombus.

MITRAL VALVE PROLAPSE (MVP)

Echo Features of MVP

2-D Echo PLAX View

- The mitral valve leaflets are thick and redundant (due to myxomatous degeneration) with increased echogenicity.
- There is a systolic bowing movement of part of either or both leaflets above the plane of the mitral valve annulus (Fig. 13.8).
- According to the extent of motion, mitral valve prolapse can be classified into the following types:

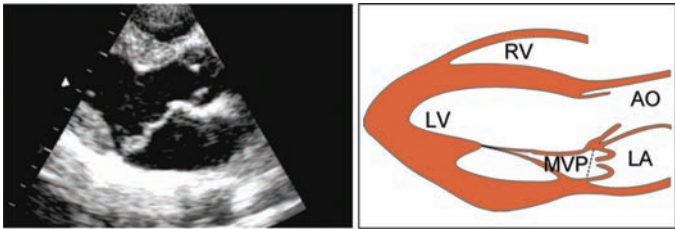


Fig. 13.8: PLAX view showing systolic bowing of both mitral leaflets into the left atrium

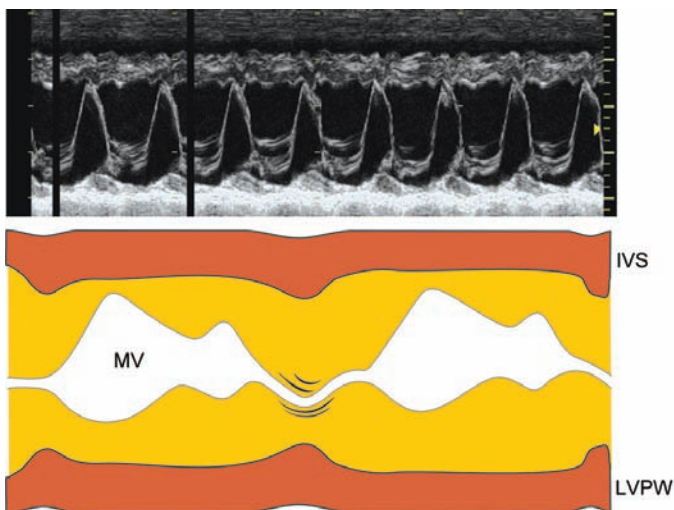


Fig. 13.9: M-mode scan of the mitral valve showing posterior systolic motion of both leaflets

Type 1: AML and PML move up to the annulus

Type 2: Large AML bows into the left atrium

Type 3: AML and PML prolapse into left atrium.

M-Mode MV Level

- There is an abrupt posterior displacement of one or both leaflets in systole. In Type 2 MVP, there is a late-systolic posterior bulge while in Type 3 MVP, there is a generalized hammock-like motion throughout systole (Fig. 13.9).
- This is preceded by anterior buckling and exaggerated excursion of the large AML into the left ventricular outflow tract (LVOT). The increased excursion is because of redundancy of the prolapsing leaflet.

2-D Echo A4CH View

- There is superior arching of the mitral valve leaflets into the left atrial cavity.
- There may be an associated tricuspid valve prolapse in case of Marfan's syndrome.

Doppler Echo

- There are features of mitral regurgitation. On color flow mapping, the regurgitant jet is often eccentric and slow in onset (midsystolic in timing).

Pitfalls in the Diagnosis of MVP

- Nodular thickening of leaflets due to myxomatous degeneration may be mistaken for vegetations in case of endocarditis (see Endocardial Diseases).
- Pseudoprolapse of the mitral valve may be observed in pericardial effusion (see Pericardial Diseases)
- Anterior buckling of the AML into the LVOT resembles systolic anterior motion (SAM) observed in hypertrophic obstructive cardiomyopathy or HOCM (see Cardiomyopathies).
- Minor 'technical mitral valve prolapse' may be observed in normal persons due to higher position of the transducer with caudal angulation.
- Conversely, a true mitral valve prolapse may be missed due to lower transducer position with cranial angulation.
- Mitral valve prolapse needs to be differentiated from a flail mitral valve leaflet caused by a ruptured papillary muscle or chordae tendinae.

Causes of MV Prolapse

- Myxomatous degeneration
- Rheumatic heart disease
- Ostium secundum ASD

- Ehlers-Danlos syndrome
- Primary pulmonary hypertension.

FLAIL MITRAL LEAFLET

Echo Features of Flail Leaflet

2-D Echo PLAX View

- The flail leaflet exhibits a free and exaggerated whip-like motion (like a sail flapping in the wind).
- The leaflet tip moves past the mitral annular plane, enters deep into the left atrium and fails to coapt with the other MV leaflet. The flail leaflet is generally the posterior mitral leaflet (Fig. 13.10).

M-Mode MV Level

- There is a coarse diastolic flutter of the flail leaflet (Fig. 13.11).
- Erratic motion of the affected leaflet causes a beat-to-beat variation of the MV diastolic pattern. The AML and PML

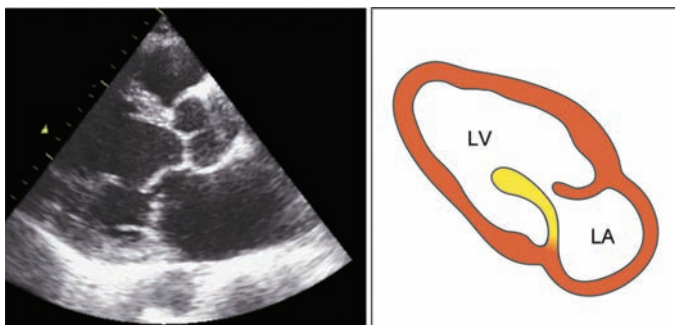


Fig. 13.10: A4CH view showing a flail posterior mitral leaflet in ventricle during diastole and atrium during systole

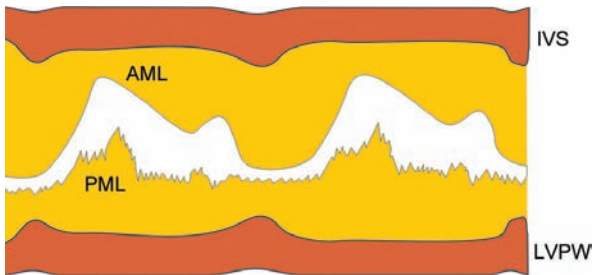


Fig. 13.11: M-mode scan of the mitral valve showing fluttering of the flail posterior leaflet

separate at the onset of diastole and come together at the onset of systole.

- On M-mode scan at the AV level, the flail leaflet produces fine lines with systolic vibration in the left atrium.

Doppler Echo

- On CW Doppler and color flow mapping, there is a jet of mitral regurgitation. The MR jet is often eccentric and directed towards the posterior left atrial wall.
- The jet area may be less than that expected for the degree of MR. Therefore, there is a risk of underestimating the degree of mitral regurgitation.

Differential Diagnosis of Flail Leaflet

- A flail mitral valve leaflet needs to be differentiated from a prolapsed mitral valve leaflet. The differences between the two conditions are given in Table 13.2.
- On M-mode scan at the MV level, multiple echoes of the flail PML may resemble those produced by a left atrial myxoma.
- The 2-D echo picture of these two conditions is however, altogether different (see Intracardiac Masses).

TABLE 13.2**Differences between flail mitral leaflet and mitral valve prolapse**

	<i>Flail leaflet</i>	<i>Prolapsed leaflet</i>
Range of motion	flaps freely	just buckles
Entry into left atrium		
extent	deep into	just enters
duration	for long time	for short time
Direction of tip	towards LA	towards LV

Causes of Flail Mitral Leaflet

- Coronary artery disease; the commonest cause of a flail leaflet is acute myocardial infarction leading to rupture of a papillary muscle or chordae tendinae.
- Rupture of the posteromedial papillary muscle with resultant flail PML usually follows inferior wall infarction. This causes acute mitral regurgitation (see Coronary Artery Disease).
- Other uncommon causes are:
 - bacterial endocarditis
 - blunt chest-wall trauma
 - connective tissue disorder.

MITRAL ANNULAR CALCIFICATION (MAC)**Echo Features of MAC***2-D Echo PLAX View*

- There is a bright and reflective echodensity in the posterior segment of the mitral valve annulus. The calcified annulus casts a dense shadow behind the valve.
- The calcification involves the base of the posterior mitral leaflet (PML) and extends into the left atrial wall and the basal portion of left ventricular posterior wall (LVPW).

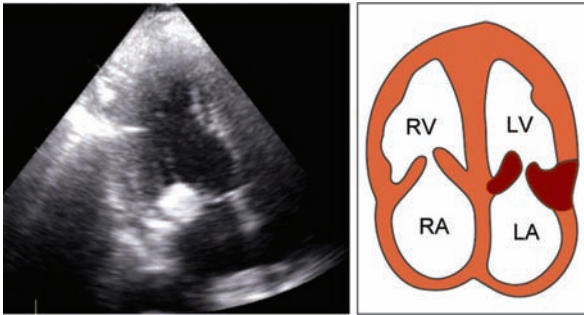


Fig. 13.12: A4CH view showing dense calcification of the mitral valve annulus

- The architecture of the PML is distorted and the leaflet is rendered immobile (Fig. 13.12).
- There may be associated calcification of the aortic annulus.

M-Mode MV Level

- There is a thick dense band of echoes behind the leaflets (AML and PML) reflected from the calcified annulus.

Doppler Echo

- Mitral annular calcification may cause mild functional mitral regurgitation (MR). Rarely, it may lead to mild mitral stenosis (MS) if it extends to involve the leaflets.

Pitfalls in the Diagnosis of MAC

- Calcified mitral annulus may be mistaken for the left ventricular posterior wall (LVPW). In that case, the LVPW is misdiagnosed as an effusion (see Pericardial Diseases).
- Mistaking a calcified mitral annulus for the LVPW can cause error in the measurement of left ventricular internal

dimensions (LVESD and LVEDD) for assessment of left ventricular function (see Ventricular Dysfunction).

- The key feature of the LVPW as opposed to a calcified mitral annulus is that the LVPW thickens in systole.
- Ulcerated excrescences on a calcific mitral annulus may produce reverberation artefacts which resemble vegetations of endocarditis (see Endocardial Diseases).

Causes of Calcific Mitral Annulus

- Mitral annular calcification with mild mitral regurgitation is one of the commonest normal findings observed when echo is performed in elderly subjects. It indicates senile degeneration within the valve.
- Mitral annular calcification is accelerated by the following clinical conditions:
 - systemic hypertension
 - diabetes mellitus
 - hypercholesterolemia
 - hyperparathyroidism

MITRAL REGURGITATION (MR)

Echo Features of MR

M-Mode LV Level

- The left ventricle is dilated and hyperkinetic due to volume overload of LV (Fig. 13.13).
- This is to maintain cardiac output since a fraction of the LV stroke volume regurgitates into the left atrium.
- Similar overloading of the left ventricle is observed in case of aortic regurgitation.
- The amplitude of motion of the IV septum and LV posterior wall is exaggerated in MR due to valvular disease.

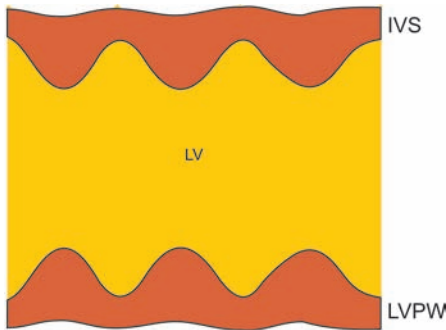


Fig. 13.13: M-mode scan of the left ventricle showing a dilated chamber and hyperkinetic motion

- In functional MR due to annular stretching, there may be global hypokinesia in cardiomyopathy or regional wall motion abnormality (RWMA) due to old myocardial infarction.

2-D Echo PLAX View

- The left atrium (LA) is dilated (normal size 19-40 mm) and shows systolic expansion. There is an increase in the LA posterior wall motion.
- Other causes of left atrial dilatation are mitral stenosis and left ventricular systolic dysfunction.
- The mitral valve architecture suggests the underlying cause of mitral regurgitation.
- There may be MV prolapse, flail MV leaflet, annular calcification or vegetations indicating endocarditis.
- Rheumatic mitral regurgitation is suggested by thickened and calcified leaflets.

M-Mode MV Level

- Mitral valve leaflets show exaggerated excursion and quick MV closure due to rapid diastolic filling.
- Accordingly, the DE excursion of the AML is increased and the E-F slope is steep (short deceleration time).
- There may be features of the underlying cause of MR such as MV prolapse (abrupt posterior motion) or flail MV leaflet (coarse cusp fluttering).
- MR of rheumatic etiology is often associated with some degree of mitral stenosis (MS).

M-Mode LV Dimensions

- The left ventricular dimensions in end-diastole and end-systole (LVESD and LVEDD) are increased. Indices of left ventricular systolic function (FS and LVEF) are normal.
- If mitral regurgitation is due to annular stretching (functional MR), left ventricular systolic function is impaired. (see Ventricular Dysfunction).
- There may be eccentric LV hypertrophy which is inadequate for the degree of LV dilatation, with an increased LV mass. (see Systemic Hypertension).

M-Mode AV Level

- Since a fraction of the stroke volume regurgitates into the left atrium, there is midsystolic closure of the aortic valve.
- Other causes of midsystolic aortic valve closure are:
 - HOCM (dynamic LVOT obstruction)
 - AS (subvalvular aortic stenosis)
 - VSD (ventricular septal defect).

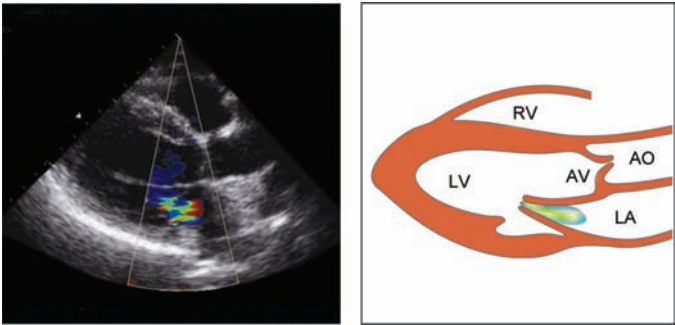


Fig. 13.14: Color flow map of a regurgitant mitral valve PLAX view showing a jet in the left atrium

Color Flow Mapping

- A regurgitant jet is seen in the left atrium on PLAX view (Fig. 13.14) and A4CH view (Fig. 13.15).

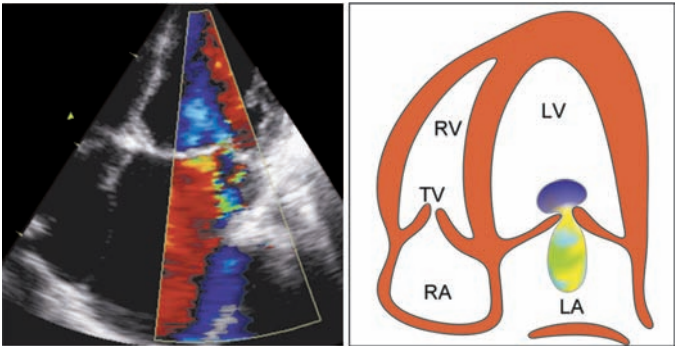


Fig. 13.15: Color flow map of a regurgitant mitral valve A4CH view showing a jet in the left atrium

TABLE 13.3**Assessment of MR severity by color flow mapping**

<i>MR severity</i>	<i>Jet area (cm²)</i>	<i>% of LA area</i>
Mild	< 4	< 25
Moderate	4–8	25–50
Severe	> 8	> 50

- The extent to which the MR jet fills the LA cavity indicates the severity of MR as shown in Table 13.3.
- A turbulent jet with a swirling movement can cause systolic flow reversal in the pulmonary veins.
- This retrograde flow along with normal venous inflow sometimes gives a variance color map.
- The width of the MR jet at the level of MV leaflet tips correlates with the degree of regurgitation. A broad color flow signal (wide jet) represents severe MR.
- The spatial profile of the MR jet does not actually reflect the regurgitant volume. The profile of MR jet depends upon the following variables:
 - size and shape of the MV orifice
 - angle of jet in relation to the valve
 - pressure difference across the MV
 - LV compliance and diastolic filling
 - size and distensibility of left atrium.
- The MR jet is eccentric or “off-centre” in:
 - mitral valve prolapse
 - flail mitral leaflet
 - paraprosthetic leak.

Doppler Echo

- On CW Doppler, scanning of the entire left atrium from the A4CH view can detect the MR jet at any angle.
- The velocity of the MR jet exceeds 2 m/sec, but the severity of MR is not related only to the velocity.
- Rather, severity of MR is more closely related to the density or intensity of the flow signal. A dense or intense signal indicates greater volume moving at high velocity.
- By CW Doppler, the pulmonary artery pressure can be estimated from the transtricuspid flow velocity (V_{max}) and the right atrial pressure.
- A V_{max} exceeding 2.5 m/sec is indicative of pulmonary hypertension (see Pulmonary Hypertension).
- On PW Doppler (Fig. 13.16), mapping progressively deeper into the left atrium (LA) till flow is not seen, can quantify the severity of MR as shown in Table 13.4.
- On PW Doppler, with the sample volume in a pulmonary vein, retrograde systolic flow (away from left atrium) may be detected.

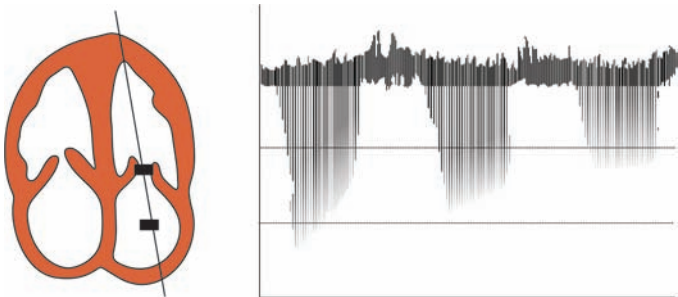


Fig. 13.16: PW Doppler of the mitral valve from A4CH view showing a MR flow signal in the left atrium

TABLE 13.4**Assessment of MR severity by PW Doppler**

<i>MR severity</i>	<i>Depth into LA</i>
Mild	< 2 cm into LA
Moderate	upto middle LA
Severe	upto distal LA

Pitfalls in the Diagnosis of MR

- The spatial profile of the MR jet depends upon several variables and, therefore, does not truly reflect the actual regurgitant volume. The MR jet may be underestimated or even altogether missed if it is eccentric.
- This error can be avoided by scanning the entire left atrium, by placing the sample volume of PW Doppler in different locations.
- In acute MR due to papillary muscle rupture after acute MI, there is not enough time for LV and LA dilatation.
- A small-volume high-velocity MR jet with normal MV architecture is observed causing an acute rise in left ventricular end-diastolic pressure (LVEDP) and rapid progression to pulmonary edema.
- It may be difficult if not impossible to differentiate organic MR with LV dysfunction from a dilated cardiomyopathy (DCMP) with functional MR.
- Features in favor of organic MR are:
 - a long-standing pansystolic murmur
 - MV leaflet prolapse, or thickening.
- In presence of MR, LV ejection fraction (LVEF) may be normal despite reduced LV contractility because the left atrium offers far less resistance to ejection than does the aorta.
- After mitral valve replacement, the LVEF is likely to decline.

Criteria for Severe MR

- Color flow jet filling 50% of left atrium
- Systolic flow reversal in pulmonary veins
- Dense flow signal on CW Doppler
- Flow up to distal LA on PW Doppler
- Left ventricular volume overload
- High pulmonary artery pressure.

Causes of Mitral Regurgitation

- Rheumatic heart disease
- Mitral annular calcification
- Mitral valve prolapse
- Coronary artery disease:
 - ischemic cardiomyopathy
 - papillary muscle dysfunction
- Congenital heart disease
 - parachute valve
 - cleft mitral leaflet
- Cardiomyopathy:
 - dilated CMP
 - restrictive CMP
 - hypertrophic CMP
- Connective tissue disease
 - systemic lupus (SLE)
 - Marfan's syndrome

Acute MR is caused by the rupture of a papillary muscle or chordae tendinae leading to a flail mitral leaflet.

Causes of acute MR are:

- myocardial infarction
- bacterial endocarditis
- chest wall trauma

TRICUSPID STENOSIS (TS)

Echo Features of TS

M-Mode and 2-D Echo

- The 2-D and M-mode features of tricuspid stenosis are similar to those of mitral stenosis. These are:
- Thickened leaflets (due to fibrosis) with or without calcification, causing multiple reverberation echoes.
- Limited excursion of leaflets with restricted valve opening and slow diastolic closure (flat E-F slope) (Fig. 13.17).
- Diastolic doming of anterior tricuspid leaflet with paradoxical anterior motion of septal leaflet.

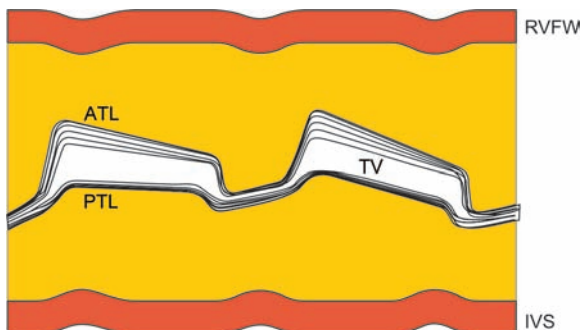


Fig. 13.17: M-mode scan of a stenotic tricuspid valve showing:

- multiple reverberation echoes
- restricted excursion of leaflets

- Unlike in mitral stenosis, the stenotic tricuspid orifice cannot be directly visualized on echo.
- The tricuspid leaflets can be visualized from the A4CH view and the PSAX view (aortic valve level) if the right ventricle is enlarged or if there is clockwise rotation of the heart.
- The tricuspid leaflets are also visualized by M-mode scanning from the PLAX view anterior to the interventricular septum, if the right ventricle is enlarged.

Doppler Echo

- On PW Doppler, in the A4CH view with the sample volume in the RV, the TV inflow spectral trace shows an increased peak diastolic flow velocity exceeding 0.5 m/sec (normal velocity is 0.3-0.7 m/sec) (Fig. 13.18).
- Detailed evaluation of the severity of tricuspid stenosis is seldom required in clinical practice.

Causes of Tricuspid Stenosis

- The commonest cause of tricuspid stenosis is rheumatic heart disease. Almost always mitral stenosis coexists. MS is at least 10 times more common than TS.




Fig. 13.18: PW Doppler of the tricuspid valve from A4CH view showing increased flow velocity

- Other rare causes of tricuspid obstruction are:
 - congenital tricuspid atresia
 - carcinoid syndrome (with TR)
 - right atrial myxoma obstructing valve
 - vegetations obstructing RV inflow
 - pericardial constriction at A-V groove.

Clinical Significance of TS

- Rheumatic disease affects the right sided valves much less commonly than it involves the mitral and aortic valves.
- Tricuspid stenosis (TS) is difficult to diagnose on clinical examination especially in presence of mitral stenosis (MS).
- It is important to establish, if the tricuspid valve is involved in rheumatic heart disease, since even a small pressure gradient is hemodynamically significant.
- If the leaflets are thick and fused at the tips, the etiology of TS is rheumatic. If the leaflets are thin, discrete and mobile, carcinoid syndrome is the most likely cause.
- Echo can provide the diagnosis of TS but cannot assess its severity, since the stenotic tricuspid orifice cannot be directly visualized.
- On PW Doppler, increased tricuspid velocity may also be observed in left-to-right shunt across an atrial septal defect. The difference is that the change in velocity is proximal to the valve in ASD and distal to it in TS.
- Absence of the tricuspid valve (tricuspid atresia) is an uncommon component of certain complex congenital heart diseases.

TRICUSPID REGURGITATION (TR)

Echo Features of TR

2-D Echo AP4CH View

- The right ventricle is dilated and hyperkinetic due to volume overload. It is of same size as or larger than left ventricle.
- When enlarged, the right ventricle becomes globular and loses its normal triangular shape.
- The right atrium is dilated and shows systolic expansion with bulging of interatrial septum towards left atrium.

2-D Echo SC4CH View

- The dilated right ventricle and right atrium can also be visualized from the subcostal 4 chamber view.
- Moreover, the inferior vena cava (IVC) and hepatic veins are dilated with further expansion in systole due to regurgitation. The liver is enlarged and pulsatile.
- Injection of contrast agent into a vein of the upper limb demonstrates reflux of contrast into the inferior vena cava during systole.

Note

- Regurgitation into the inferior vena cava (IVC) is also observed in cardiac tamponade and right ventricular dysfunction but only in diastole.
- In these conditions, the IVC is dilated beyond 2 cm and fails to constrict by at least 50 percent during inspiration.

2-D Echo PLAX View

- On M-mode scan at the ventricular level, there is dilatation of the right ventricular cavity with paradoxical motion of the interventricular septum.

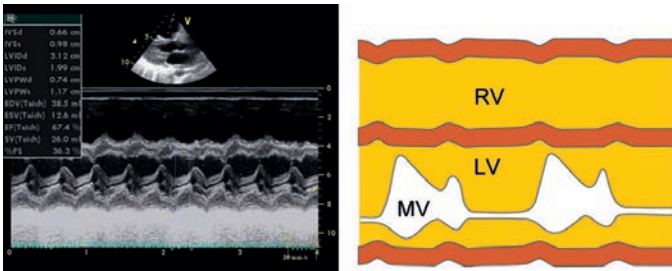


Fig. 13.19: M-mode scan of the ventricles showing:

- dilatation of the right ventricle
 - paradoxical motion of septum
- The septum moves away from the left ventricle and towards the right ventricle in systole (Fig. 13.19). There is increased amplitude of motion of the RV free wall.
 - The tricuspid valve can be visualized from the right ventricular inflow tract view, by slight medial angulation from the parasternal long axis view.
 - On M-mode scan at this level, there is exaggerated leaflet excursion and early diastolic closure due to rapid diastolic filling (short deceleration time).

2-D Echo PSAX View

- The tricuspid valve can also be visualized from the short-axis view at the aortic valve level.
- It may reveal the underlying cause of TR such as rheumatic thickening, leaflet prolapse, flail leaflet, valve vegetations or Ebstein's anomaly.

Color Flow Mapping

- A mosaic colored regurgitant jet is seen in the right atrium (RA) along the interatrial septum, in systole (Fig. 13.20).

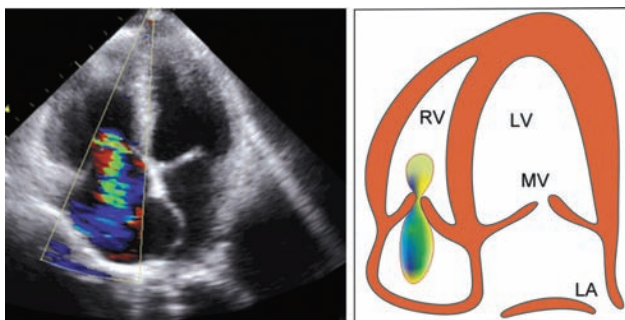


Fig. 13.20: Color flow map of a regurgitant tricuspid valve from A4CH view showing a jet in the right atrium

- The extent to which the TR jet fills the RA cavity indicates the severity of TR as shown in Table 13.5.
- The width of the TR jet correlates with the degree of regurgitation. A broad color flow signal (wide jet) represents severe TR.
- In severe TR, the regurgitant jet flows in a retrograde direction (reverse flow) into the inferior vena cava (IVC) and the hepatic veins (HV)
- Contrast echo performed by injecting a peripheral vein with a contrast agent will show microbubbles moving retrogradely towards the IVC and HV.

TABLE 13.5

Assessment of TR severity by color flow mapping

<i>TR severity</i>	<i>RA area (%)</i>
Mild	< 20
Moderate	20–34
Severe	> 35

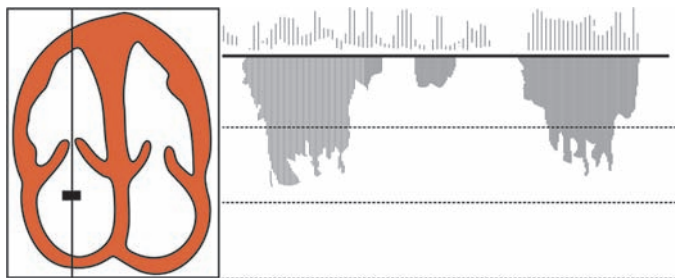


Fig. 13.21: CW Doppler of the tricuspid valve from A4CH view showing TR flow signal in the right atrium

Doppler Echo

- On CW Doppler, scanning of the entire right atrium from the A4CH view, can detect the TR jet (Fig. 13.21).
- The velocity exceeds 2 m/sec and rises further during inspiration. Severity of TR is not related to the velocity but to the density of the signal.
- A flow profile of high velocity with quick acceleration and rapid deceleration is an indicator of severe TR.
- This occurs due to rapid equalization of the RV and RA pressures, the so called “common-chamber effect”.
- On PW Doppler, mapping progressively deeper into the right atrium (RA) till flow is not seen, can quantify the severity of TR as shown in Table 13.6.
- On PW Doppler, with the sample volume in the inferior vena cava (IVC), retrograde systolic flow (from right atrium to IVC) may be detected.

Doppler Calculations

- When tricuspid regurgitation is secondary to right ventricular enlargement and dilatation of the TV annulus, (as it often is), the transtricuspid flow velocity (V_{\max}) is used to calculate the pulmonary artery pressure (Fig. 13.22).

TABLE 13.6

Assessment of TR severity by PW Doppler

TR severity	Depth into RA
Mild	< 1 cm
Moderate	1–3 cm
Severe	> 3 cm

- The following Doppler calculations are employed:
RV pressure (RVP) minus RA pressure (RAP) is equal to Pressure gradient (PG) across the tricuspid valve

$$RVP - RAP = PG$$

$$RVP = PG + RAP$$

$$PG = 4 V_{\max}^2$$

$$RVP = 4 V_{\max}^2 + RAP$$

RV pressure (RVP) is equal to Pulmonary artery pressure (PAP) in the absence of pulmonary stenosis (PS)

Therefore, $PAP = 4 V_{\max}^2 + RAP$

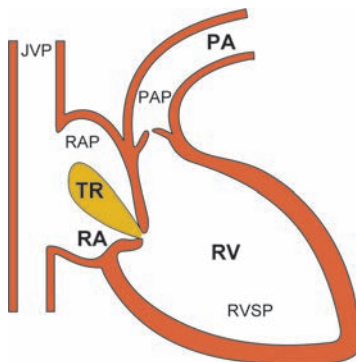


Fig. 13.22: The principle of estimating pulmonary artery pressure from the tricuspid regurgitant velocity

If the V_{\max} is 2.5 m/sec or more and RAP is more than 5 mm, the PAP exceeds 30 mm Hg as calculated below:

$$\begin{aligned}\text{Pulmonary artery pressure (PAP)} &= 4 \times (2.5)^2 + > 5 \text{ mm} \\ &= 4 \times 6.25 + > 5 \text{ mm} \\ &= 25 + > 5 \text{ mm} \\ &= > 30 \text{ mm Hg}\end{aligned}$$

Causes of Tricuspid Regurgitation

The causes of TR can be classified as primary diseases of the tricuspid valve and TR secondary to dilatation of the TV annulus.

Primary causes of TR are similar to those of mitral regurgitation. Secondary TR is due to enlargement of the right ventricle.

Primary Causes

- Rheumatic heart disease
- Tricuspid valve prolapse
- Flail tricuspid leaflet
- Right-sided endocarditis
- Papillary muscle dysfunction
- Connective tissue disorder
- Carcinoid syndrome
- Ebstein's anomaly

Secondary Causes

- Pulmonary hypertension:
 - Eisenmenger reaction
 - rheumatic mitral disease
 - chronic cor pulmonale
 - primary pulmonary hypertension

- Primary myocardial disease:
 - dilated cardiomyopathy
- Right ventricular overload
 - septal defect (ASD, VSD)

EBSTEIN ANOMALY

Echo Features of Ebstein Anomaly

2-D Echo A4CH View

- There is downward displacement of the tricuspid valve into the body of the right ventricle.
- The tricuspid valve appears to have moved from its normal position at the AV junction towards the RV apex. The mitral and tricuspid valve planes are hence offset.
- The septal TV leaflet is attached to the IV septum, 10 mm or more inferior to the anterior mitral leaflet (Fig. 13.23).

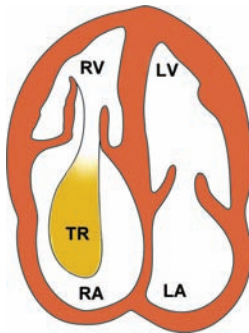


Fig. 13.23: Typical features of Ebstein anomaly:

- displaced tricuspid valve
- right atrial enlargement
- tricuspid regurgitation

- Subvalvular AS
 - Subaortic discrete membrane or ring
 - Tunnel-type diffuse muscular narrowing
 - IHSS/HOCM hypertrophic cardiomyopathy.
- Supravalvular AS
 - William's syndrome discrete membrane
 - Hour-glass AS focal narrowing

Echo Features of AS

2-D Echo PLAX View

- In valvular AS the aortic valve leaflets are thickened due to fibrosis with or without calcification.
- In rheumatic AS, the process starts in the leaflets with fusion of commissures followed by secondary calcification of the leaflets and annulus (Fig. 13.24A).
- In calcific AS, the process starts with calcification of the annulus and progresses medially to involve the valve leaflets (Fig. 13.24B).
- In bicuspid aortic valve, calcification is observed only in the late stages of the disease.
- There is reduced excursion of aortic leaflets with restricted opening of the aortic valve.
- Due to fusion at the leaflet tips and free motion of the leaflet bodies, there is systolic doming. This is a characteristic feature of rheumatic AS.
- Leaflet excursion is normal in a bicuspid aortic valve unless it is heavily calcified.
- In valvular AS, there is poststenotic dilatation of the proximal aorta or aortic root (normal diameter 20–37 mm).

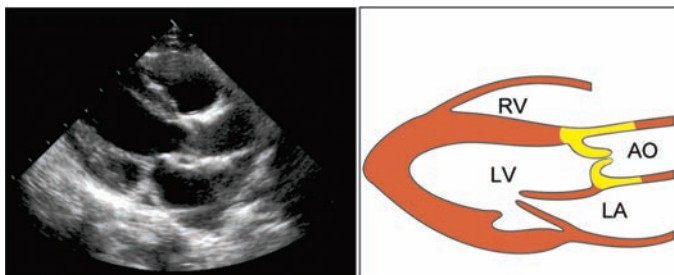


Fig. 13.24A: PLAX view showing calcification of aortic valve leaflets

- This is due to the high velocity jet through the narrow and distorted valve, impinging on the wall of the ascending aorta.
- In supra-valvular AS, a thin linear echo (discrete membrane) extends inwards from the aortic wall.
- With an hour-glass AS, there is a gradual decrease in aortic root diameter during above downwards angulation of the transducer.
- In membranous subaortic AS, there is a linear echo (discrete membrane) in the LV outflow tract, between the IV septum and the AML of the mitral valve.

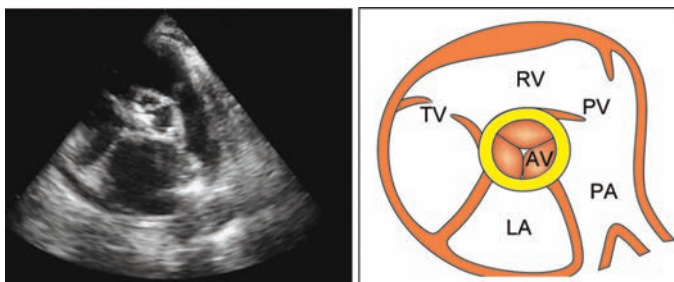


Fig. 13.24B: PSAX view showing calcification of aortic valve annulus

- The linear echo is proximal and parallel to the aortic valve sometimes with a T-artefact at its free edge.
- In tunnel-type subaortic AS, the left ventricular outflow tract (LVOT) is narrower than the aortic root.
- In long-standing AS, there is often left ventricular hypertrophy (LVH) due to left ventricular pressure overload.
- There is thickening of the IV septum and LV posterior wall which exceeds 12 mm. This leads to a small LV cavity with good LV systolic function.
- In LVH, the left ventricular mass exceeds 136 grams/m² in males and 112 grams/m² in females.
- In later stages of AS, especially with associated aortic regurgitation (AR), there is LV dilatation with LV systolic dysfunction (see Ventricular Dysfunction).
- This clinical course of LV hypertrophy followed by LV dilatation is also observed in systemic hypertension and coarctation of aorta (see Systemic Hypertension).

2-D Echo PSAX View

- On short-axis view at aortic valve level, there is leaflet thickening, reduced excursion and a small AV lumen.
- A bicuspid valve can be identified from this view. It results from failure of two of the aortic cusps to separate during embryological development.
- Therefore, there are 2 cusps and 2 commissures while the 3rd commissure (between the right and left cusps) is replaced by a raphe of tissue.
- There is distortion of the triradiate anatomy of aortic valve cusps. Normally, they give an appearance resembling the “Mercedes-Benz” symbol (Fig. 13.25).

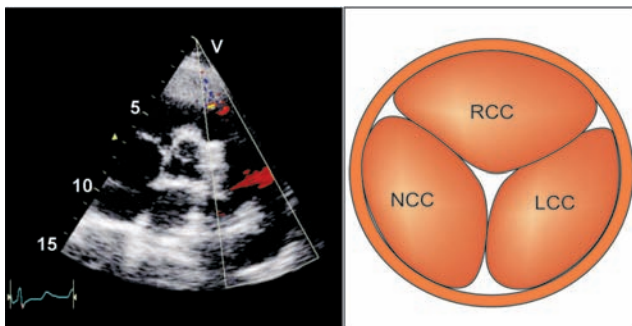


Fig. 13.25: PSAX view showing triradiate anatomy of the aortic valve:
 RCC : right coronary cusp
 LCC : left coronary cusp
 NCC : non-coronary cusp

M-Mode AV Level

- Normally, on M-mode scan from PLAX view at the aortic valve level, the aortic cusps form a central closure line in diastole.
- In systole, they open to form a box-like opening or parallelogram shape. The normal maximum aortic cusp separation in systole is 15 to 26 mm or 75% of aortic root diameter.
- In AS, the closure line and box-like opening are replaced by multiple thick dense echoes in the aortic root throughout the cardiac cycle. Individual cusps and their motion are hard to recognize (Fig. 13.26).
- Due to restricted leaflet excursion, the size of the box-like opening of the AV is reduced to less than 15 mm. The severity of AS can be gauged from the size of AV opening as shown in Table 13.7.
- AV leaflet separation less than 8 mm makes severe AS very likely and more than 11 mm makes it very unlikely.

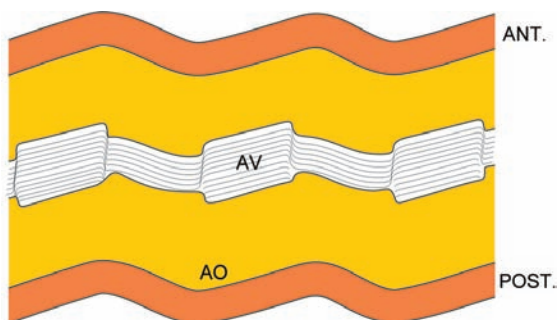


Fig. 13.26: M-mode scan of aortic valve showing multiple dense echoes within the aortic root

TABLE 13.7

Assessment of AS severity from the degree of AV opening

<i>AS severity</i>	<i>AV opening</i>
Mild	13–15 mm
Moderate	8–12 mm
Severe	< 8 mm

- In subvalvular AS, there is early mid-systolic closure of the aortic valve, particularly of the right coronary cusp, with fluttering of the cusp during rest of systole (Fig. 13.27).
- The subvalvular high velocity draws the cusps into a semiclosed position by the Venturi effect.
- The closure line of the aortic valve in diastole is normally equidistant from the anterior and posterior aortic walls. In bicuspid aortic valve, the closure line is eccentric or off-center and closer to one of the two aortic walls (Fig. 13.28).

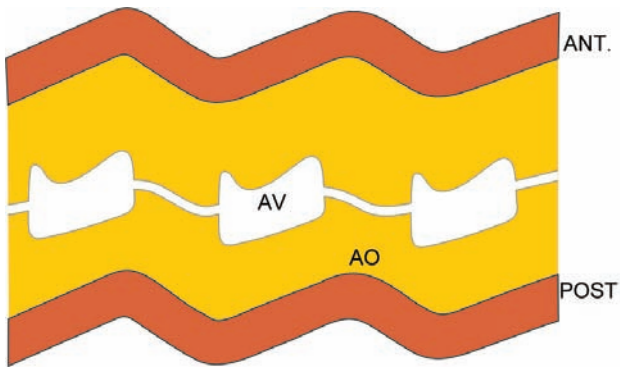


Fig. 13.27: M-mode scan of the aortic valve showing mid-systolic closure

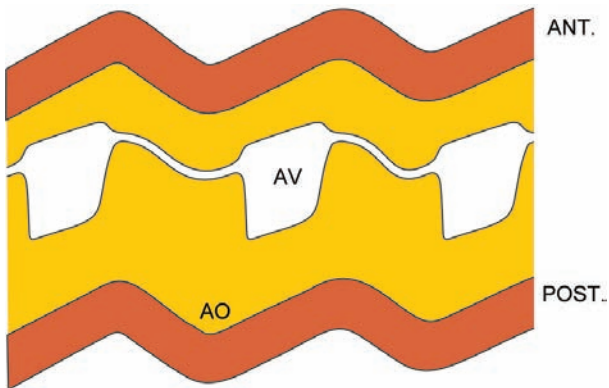


Fig. 13.28: M-mode scan of the aortic valve showing eccentric diastolic closure

- Eccentricity of the closure line is expressed as the aortic eccentricity index. An aortic eccentricity index greater than 1.5 is abnormal.

$$\text{Aortic eccentricity index} = \frac{\text{aortic root diameter} \times 0.5}{\text{distance between closure line and near aortic wall}}$$

Color Flow Mapping

- In the A5CH view, there is a mosaic flow jet in the proximal aorta just above the valve (Fig. 13.29). The width of the jet approximates the size of the AV orifice.
- The location of the jet is proximal or distal to the aortic valve, in subvalvular and supra- valvular AS respectively.

Doppler Echo

- The normal peak aortic systolic outflow velocity ranges from 0.9 to 1.8 m/sec with a mean of 1.3 m/ sec. In AS, the velocity exceeds 2 m/sec (Fig. 13.30).

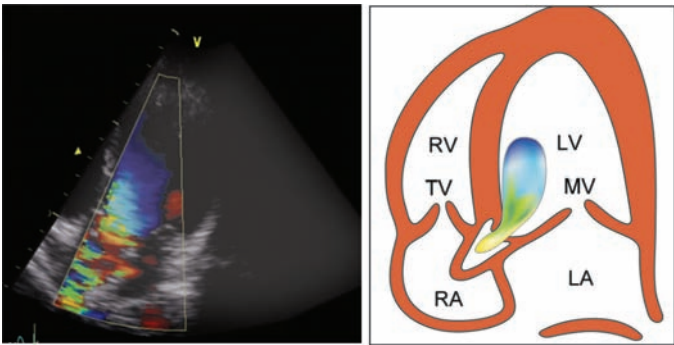


Fig. 13.29: Color flow map of stenotic aortic valve from A5CH view showing a jet in the proximal aorta

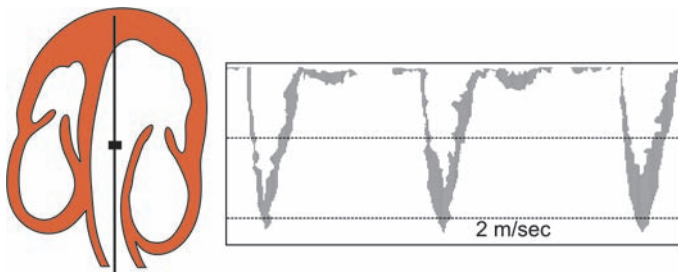


Fig. 13.30: PW Doppler of the aortic valve from A5CH view showing increased systolic flow velocity

- It can be picked up from the apical view, the right parasternal view and the suprasternal window (Fig. 13.31).
- The peak systolic velocity may be underestimated if the blood flow is eccentric. The color flow map may be used to place the sample volume of PW Doppler.

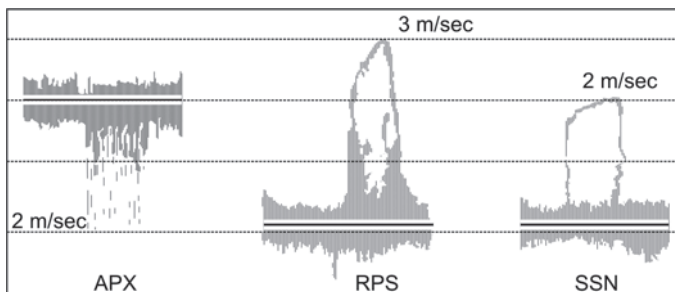


Fig. 13.31: CW Doppler of the aortic valve from multiple views showing a peak systolic velocity of 3 m/sec
 APX: apical 5-chamber view
 RPS: right parasternal view
 SSN: suprasternal notch

- Multiple windows need to be examined to obtain parallelism between the Doppler beam and aortic flow and thus to estimate true peak aortic velocity (Fig. 13.31).
- The peak velocity is obtained below or above the aortic valve level, in subvalvular and supra-avalvular AS respectively.
- Timing of peak systolic velocity is an indicator of severity of AS. Early systolic peak is observed in mild AS, concomitant AR and also in HOCM. Mid-systolic peak is observed in severe aortic stenosis.
- The peak instantaneous transvalvular pressure gradient can be estimated by the following calculations:

$$\begin{aligned}\text{Peak PG} &= 4V_{\max}^2 - 4V_{\text{LVOT}}^2 \\ &= 4(V_{\max}^2 - V_{\text{LVOT}}^2)\end{aligned}$$

V_{\max} : peak AV velocity by CW Doppler

V_{LVOT} : peak LVOT velocity by PW Doppler

- V_{LVOT} can be ignored if it is less than 1 as in moderate to severe AS since V_{LVOT} occurs later in systole.
- V_{LVOT} should be taken into account in mild AS and in the presence of AR or else a falsely high pressure gradient may be calculated.
- This peak instantaneous pressure gradient is different from the peak-to-peak pressure gradient during catheterization.
- The severity of AS correlates with peak aortic velocity and transvalvular pressure gradient as shown in Table 13.8.

Doppler Calculations

- The transaortic pressure gradient depends upon variables including heart rate, stroke volume and the parallelism obtained between the Doppler beam and blood flow.
- Therefore, it may not be a true indicator of the severity of valvular stenosis. Calculation of the aortic valve orifice area using the continuity equation is therefore more accurate.

TABLE 13.8**AS severity from the peak velocity and pressure gradient**

AS severity	Peak velocity (m/sec)	Pressure gradient (mm Hg)
Mild	1-2	< 20
Moderate	2-4	20-64
Severe	> 4	> 64

- The continuity equation relies on the simple principle that the volume of blood leaving the LV is equal to the volume of blood crossing the AV (Fig. 13.32).

- The aortic valve area is calculated as follows:

$$V_{\max} \text{ AV} \times \text{AV area} = V_{\max} \text{ LVOT} \times \text{LVOT area}$$

$$\text{AV area} = \frac{V_{\max} \text{ LVOT}}{V_{\max} \text{ AV}} \times \text{LVOT area}$$

$$\text{LVOT area} = \pi (D/2)^2 = \frac{22}{7} \times \frac{D^2}{4} = 0.786 \times D^2$$

$$\text{Therefore, AV area} = \frac{V_{\max} \text{ LVOT}}{V_{\max} \text{ AV}} \times 0.786 \times D^2$$

- The severity of AS correlates with the aortic valve area as shown in Table 13.9.

Pitfalls in the Diagnosis of AS

- Once the aortic valve is heavily calcified, it is difficult to visualize the leaflets separately. In that case, it is not possible to differentiate between a tricuspid and bicuspid aortic valve as also between rheumatic and calcific AS.

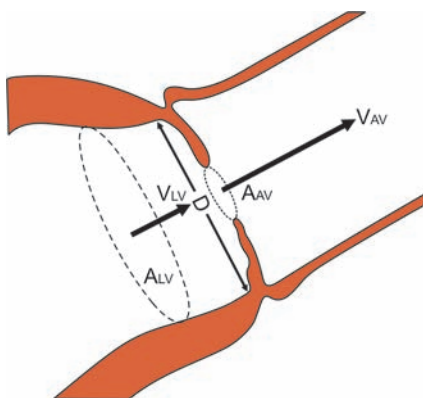


Fig. 13.32: The principle of calculating aortic valve area from the continuity equation

TABLE 13.9

Assessment of AS severity from the valve area

Severity of AS	AV area (cm ²)
Mild	1.5–2.5
Moderate	0.75–1.5
Severe	< 0.75

- In a condition known as aortic sclerosis, there is calcification of the aortic valve without any restriction of valve opening or leaflet excursion. These elderly patients present with an ejection systolic murmur. Systemic hypertension and diabetes mellitus are often associated.
- Abnormalities of leaflets such as thickening, doming, fixity and calcification are not observed in supravalvular or subvalvular types of AS. Clinically, an ejection click and systolic thrill are only observed in valvular AS.

- The development of left ventricular hypertrophy (LVH) in AS is similar to that observed in other conditions causing LV pressure overload. These conditions are systemic arterial hypertension as well as coarctation of aorta (see Systemic Hypertension).
- Reduction in size of the box-like opening of the aortic valve is a feature of moderate to severe AS. It is also observed in other conditions of low cardiac output.
- Reverberation of echoes from a heavily calcified valve may cause an apparent increase in cusp thickness. In that case, the severity of AS is likely to be overestimated.
- Besides subvalvular AS, mid-systolic closure of the aortic valve is observed in HOCM (hypertrophic cardiomyopathy) with dynamic outflow tract (LVOT) obstruction.
- It is also seen in moderate to severe mitral regurgitation (MR) and ventricular septal defect (VSD) where part of the LV stroke volume enters the left atrium and right ventricle respectively.
- Besides in bicuspid aortic valve, an eccentric diastolic closure line may also be observed with a tricuspid aortic valve when there is a subaortic VSD and prolapse of the right coronary cusp into the LVOT.
- In subvalvular and supra-avalvular AS, on color flow mapping and on CW Doppler, the color jet and pressure gradient are observed below and above the aortic valve level respectively.
- The transaortic peak velocity and thus the pressure gradient depends upon the degree of parallelism obtained between the Doppler beam and the aortic flow. These may be underestimated if the Doppler beam is not in line with the flow or if the velocity jet is eccentric in direction.
- In the presence of AS, LV ejection fraction (LVEF) may be low despite normal LV contractility. This is because the left ventricle has to overcome a high resistance during ejection. After aortic valve replacement, the LVEF is expected to rise.

- The severity of AS is not related to the loudness of the ejection systolic murmur. Turbulent flow across a mildly stenosed valve can cause a loud murmur while marked restriction to blood flow across a severely stenosed valve can cause a soft murmur.

Indications for Intervention in AS

A stenotic aortic valve needs to be replaced by a prosthetic valve in the following situations:

- Severe AS (PG > 64 mm Hg; AV area < 0.75 cm²)
- Moderate AS but with symptoms (angina or syncope)
- Moderate AS without symptoms but high activity level
- Moderate AS with other cardiac surgery (e.g. CABG)
- Moderate to severe AS with LV systolic dysfunction.

AORTIC REGURGITATION (AR)

Causes of AR

Valvular AR

- Rheumatic heart disease
- Bacterial endocarditis
- Congenital heart disease
 - bicuspid aortic valve
 - subvalvular stenosis
- Connective tissue disease
 - Rheumatoid arthritis
 - Systemic lupus (SLE)

Aortic Root Dilatation

- Systemic hypertension
- Cystic medial necrosis
 - Marfan's syndrome
 - Ehlers-Danlos syndrome
- Granulomatous aortitis
 - Tubercular
 - Syphilitic (rare)
- Inflammatory disease
 - Reiter's syndrome
 - Ankylosing spondylitis.

Acute AR

- Aortic dissection
- Chest wall trauma
- Bacterial endocarditis

Echo Features of AR

M-Mode LV Level

- The left ventricle is dilated and hyperkinetic due to volume overload. The motion of the IV septum as well as the LV posterior wall is exaggerated (Fig. 13.33).
- Similar diastolic overloading of the left ventricle is observed in case of mitral regurgitation.

2-D Echo PLAX View

- The aortic root is dilated (normal size 20-37 mm) more so if the cause of AR is disease of the aortic root rather than aortic valvular disease.

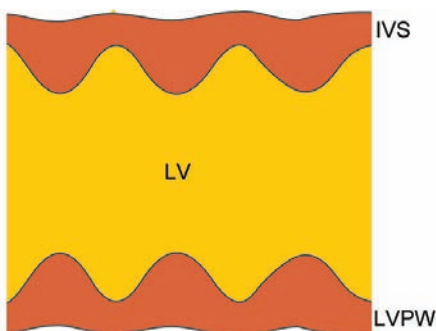


Fig. 13.33: M-mode scan of the left ventricle showing a dilated chamber and hyperkinetic motion

- An intimal flap in the proximal aorta confirms aortic dissection as the cause of aortic regurgitation.
- The aortic valve architecture suggests the underlying cause of aortic regurgitation.
- There may be a bicuspid aortic valve or vegetations on leaflets in case of endocarditis.
- Rheumatic AR is suggested by thickened and fibrosed leaflets, non-coaptation of AV cusps and associated disease of the mitral valve.

M-Mode AV Level

- There is dilatation of the aortic root.
- The diastolic closure line is eccentric or off-center in case of bicuspid aortic valve
- AR of rheumatic etiology is often associated with some degree of aortic stenosis (AS).
- There may be thick dense echoes in the aortic root obscuring the clear outline of cusps.

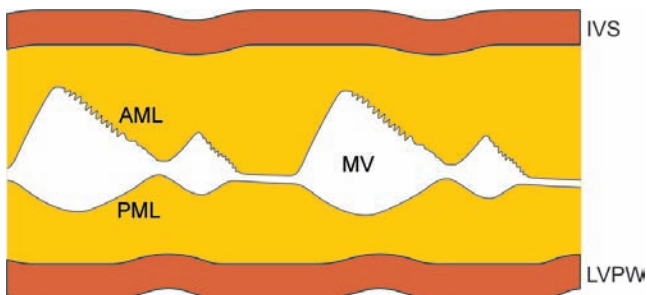


Fig. 13.34: M-mode scan of the mitral valve showing diastolic flutter of anterior mitral leaflet

- Fluttering of an AV cusp in diastole is observed if it has ruptured due to infective endocarditis. Vegetations may be seen as thick echoes on the leaflet.
- The left atrium may be dilated due to associated disease of the mitral valve.

M-Mode MV Level

- There is fluttering of the anterior mitral leaflet (AML) in diastole, which is sandwiched between the aortic regurgitant flow and the stream of left atrial emptying (Fig. 13.34).
- This forms the basis of the Austin-Flint murmur auscultated in case of AR.

Note

- There may also be fluttering of the interventricular septum (IVS), depending upon the direction of the regurgitant jet.
- Diastolic flutter of AML is not observed if there is mitral stenosis (thick AML), acute AR (early mitral valve closure) or severe AR (short diastole).

- Premature closure of the mitral valve (MV) occurs due to rapid completion of diastole especially in acute or severe AR. It indicates an elevated left ventricular end-diastolic pressure (LVEDP).

M-Mode LV Dimensions

- The left ventricular dimensions in end-diastole and end-systole (LVESD and LVEDD) are increased.
- Indices of left ventricular function (fractional shortening and ejection fraction) suggest good LV function in early stages of the disease.
- Later on, there may be severe LV dilatation and systolic dysfunction (see Ventricular Dysfunction).
- There is eccentric LV hypertrophy which is inadequate for the degree of LV dilatation (see Systemic Hypertension).
- Symptomatic and progressive LV dilatation with diameter exceeding 55 mm is an indication for surgical intervention.
- There may be diastolic fluttering of the interventricular septum (IVS) if the regurgitant jet is directed towards the septum and not the anterior mitral leaflet (AML).

Color Flow Mapping

- A regurgitant jet is seen entering the left ventricular cavity on PLAX view (Fig. 13.35A) and A5CH view (Fig. 13.35B).
- The width of the AR jet in the left ventricular outflow tract (LVOT) just below the aortic valve indicates the severity of AR as shown in Table 13.10.
- The extent of AR jet entry into the LV cavity also indicates the severity of AR as shown in Table 13.11.

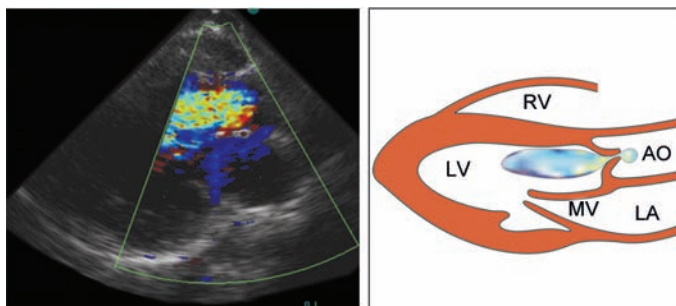


Fig. 13.35A: Color flow map of the aortic valve showing a regurgitant jet on PLAX view

TABLE 13.10

Assessment of AR severity from the width of jet

<i>AR severity</i>	<i>Jet : LVOT ratio (%)</i>
Trivial	< 24
Mild	25–46
Moderate	47–64
Severe	> 64

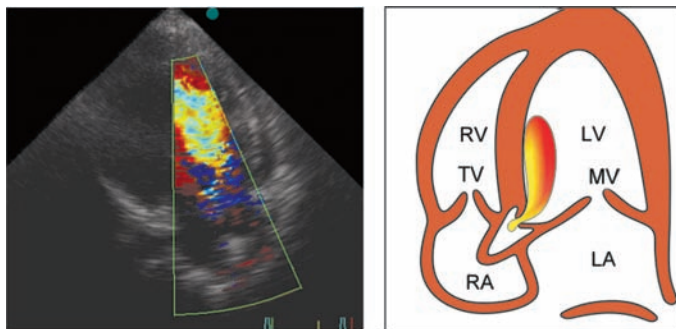


Fig. 13.35B: Color flow map of the aortic valve showing a regurgitant jet on A5CH view

TABLE 13.11**Assessment of AR severity from the depth of jet**

AR severity	Depth of jet
+1	in LVOT
+2	tip of AML
+3	mid of LV
+4	apex of LV

Doppler Echo

- On PW Doppler using the A5CH view, with the sample volume just proximal to the aortic valve, the AR signal can be detected (Fig. 13.36).
- Since the signal is towards the transducer, it is above the baseline. However, because the AR velocity usually exceeds 2 m/sec, aliasing occurs.
- In that case, CW Doppler is more useful as it can measure a higher velocity without aliasing and the signal is only above the baseline.

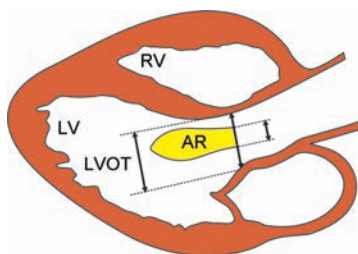


Fig. 13.36: The ratio between width of AR jet and LVOT diameter indicates the severity of aortic regurgitation

TABLE 13.12**Assessment of AR severity by PW Doppler**

<i>AR severity</i>	<i>Depth into LV</i>
Mild	within LVOT
Moderate	upto mid LV
Severe	upto LV apex

- On PW Doppler, mapping progressively deeper into the left ventricle till flow is not seen can quantify the severity of AR as shown in Table 13.12.
- On PW Doppler, with the sample volume in the aortic arch from the suprasternal window, diastolic flow reversal of high velocity and long duration indicates severe AR.
- CW Doppler can detect the high velocity AR signal without the phenomenon of aliasing.
- However, severity of AR is not only related to the velocity but also to the density or intensity of the flow signal. A dense or intense signal indicates that greater volume of blood is moving at high velocity.

Doppler Calculations

- The severity of AR can be gauged from the rate of deceleration of the AR velocity profile. A rapid deceleration rate (steep fall) indicates rapid equalization of the pressure difference between the aorta and the LV cavity and therefore severe AR. In other words, steeper the slope, more severe is the AR.
- Deceleration rate is expressed in meters/second per second or m/sec^2 (Fig. 13.37).
- Another way to express this principle is by measuring the time taken for the peak pressure gradient across the aortic valve to drop to half of its original value, which is the pressure

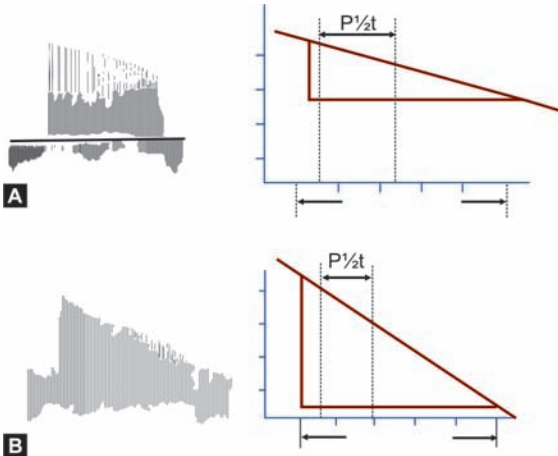


Fig. 13.37: Relationship between rate of deceleration and severity of aortic regurgitation:
 A. Gradual slope: mild AR
 B. Steep slope: severe AR

half-time. The quicker the equalization of the pressure difference between the aorta and LV (short pressure half-time), more severe is the AR.

- Pressure half-time is expressed in milliseconds (millisec).
- The severity of AR correlates with the deceleration rate and pressure half-time as shown in Table 13.13.

Pitfalls in the Diagnosis of AR

- M-mode and 2-D echo cannot directly diagnose AR but can indicate the cause and the effects of AR on the aortic root and left ventricle.
- They can pick up aortic root dilatation, aortic valve abnormalities and left ventricular dilatation.

TABLE 13.13**Assessment of AR severity by deceleration rate**

<i>AR severity</i>	<i>Deceleration rate (m/sec²)</i>	<i>Pressure half-time (millisec)</i>
Mild	< 2	> 400
Moderate	2–3	300–400
Severe	> 3	< 300

- Color flow mapping and Doppler echo can not only detect AR but also assess its severity.
- The diagnosis of AR may be straightforward but assessment of its severity is complex and requires several echo criteria.
- Even then, distinguishing mild from moderate AR may be particularly difficult while severe AR is readily picked up.
- The AR jet may be underestimated or even altogether missed if it is eccentric.
- This error can be avoided by scanning the entire left ventricular outflow tract by PW Doppler at different depths.
- The width and length of the AR jet provides quantitative information about the severity of AR.
- This is not a fool proof method since the narrow jet of mild AR may extend deep into the LV while a broad jet of severe AR may not extend far if it is eccentric.
- In acute AR due to dissection, endocarditis or trauma, there is not enough time for left ventricular dilatation to develop.
- A small-volume high-velocity AR jet is observed with an acute rise of left ventricular end-diastolic pressure (LVEDP) and pulmonary edema.
- The AR jet may be difficult to differentiate from the jet of mitral stenosis, particularly in the A5CH view. The matter is

further complicated by the fact that AR and MS often coexist in rheumatic heart disease.

- On PW Doppler, the 2 jets can be differentiated by mapping the LV outflow tract and MV area separately. AR shows a high velocity (> 2 m/sec) signal throughout diastole while MS shows a low velocity (< 2 m/sec) signal only in mid-diastole.

Criteria for Severe AR

- Color flow jet width: LVOT width $>50\%$
- Diastolic flow reversal in the aortic arch
- Rapid velocity decay ($P\frac{1}{2} t < 300$ msec).
- Dense flow signal on CW Doppler
- Flow up to LV apex on PW Doppler
- Left ventricular volume overload

Indications for Intervention in AR

A regurgitant aortic valve needs surgical repair or replacement in the following situations:

- Moderate to severe AR with severe symptoms (effort intolerance)
- Asymptomatic severe AR with LV dysfunction (LVEF $< 50\%$)
- Asymptomatic severe AR with LV dilatation (LVESD > 55 mm)
- Acute AR with hemodynamic compromise (aortic dissection)

PULMONARY STENOSIS (PS)

Causes of PS

Valvular PS

- Congenital PS
 - isolated PS (common)
 - rubella syndrome
- Acquired PS
 - rheumatic disease (rare)
 - carcinoid syndrome

Subvalvular PS

- isolated PS (rare)
- with Fallot's tetralogy

Supravalvular PS

- Noonan's syndrome
- with supra-aortic AS

Echo Features of PS

2-D Echo PSAX View

- In valvular PS, the pulmonary valve leaflets are thickened and they may be calcified. There is systolic doming of leaflets with reduced excursion and restricted opening of the pulmonary valve.
- There may be poststenotic dilatation of the pulmonary artery. This is because of the high velocity jet through the narrow valve, impinging on the wall of the pulmonary artery.
- In subvalvular PS, the right ventricular outflow tract (RVOT) appears narrower than the pulmonary root. Alternatively, a

discrete muscular band is seen in the RVOT. The pulmonary valve leaflets are not thick and there is no poststenotic pulmonary artery dilatation.

- In supra-avalvular PS, a discrete shelf-like band may be seen in the pulmonary artery. Alternatively, a long stenotic tunnel-like area is observed distal to the pulmonary valve.

M-Mode PV Level

- In valvular PS, besides thickening of the PV cusps, there is a prominent 'a' wave on the pulmonary valve trace. This occurs because of doming of the pulmonary leaflets.
- In subvalvular (infundibular) PS, there is premature closure of the PV in mid-systole with fluttering of the PV leaflets during rest of systole.
- In supra-avalvular PS, scanning at the PV level does not reveal any abnormality.

2-D Echo PLAX View

- The effect of PS on the right ventricle is the same, irrespective of the site of obstruction whether it is valvular, subvalvular or supra-avalvular. There is right ventricular pressure overload.
- This causes RV free wall thickness more than 5 mm with or without RV dilatation beyond 23 mm and paradoxical motion of the septum (IVS).

Color Flow Mapping

- There is a color flow jet in the proximal pulmonary artery in valvular PS. The width of the jet approximates the size of the PV orifice (Fig. 13.38).
- The location of jet is just below or just above the valve in subvalvular and supra-avalvular PS respectively.

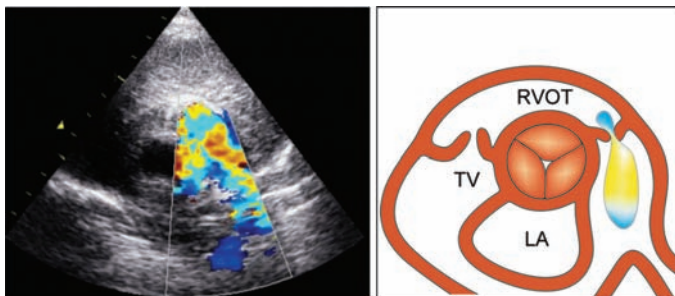


Fig. 13.38: Color flow map of a stenotic pulmonary valve from PSAX view showing a jet in the pulmonary artery

Doppler Echo

- The normal peak pulmonary systolic outflow velocity ranges from 0.5 to 1.0 m/sec with a mean of 0.75 m/sec. In PS it exceeds 1 m/sec (Fig. 13.39).
- In valvular PS, the peak velocity indicates the pressure gradient across the pulmonary valve.
- In subvalvular or supravulvular PS, the peak velocity is obtained below or above the PV respectively, according to the site of narrowing.

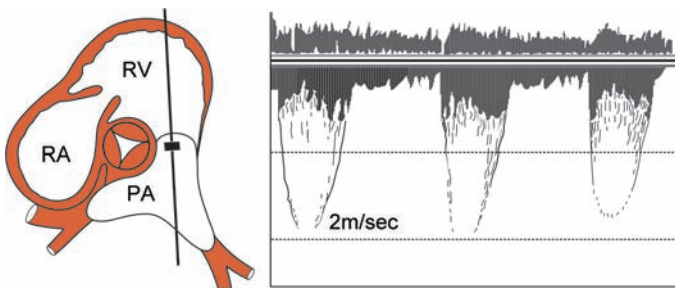


Fig. 13.39: PW Doppler of a stenotic pulmonary valve from PSAX view showing increased systolic velocity

TABLE 13.14**Assessment of PS severity from pressure gradient**

<i>PS severity</i>	<i>Valve area (cm²)</i>	<i>Pressure gradient (mm Hg)</i>
Mild	> 1.0	< 25
Moderate	0.5–1.0	25–40
Severe	< 0.5	> 40

Assessing Severity of PS

- The severity of PS correlates with the pressure gradient and estimated valve area as shown in Table 13.14.

PULMONARY REGURGITATION (PR)**Causes of PR***Primary Causes*

- PR is rarely due to primary causes
 - rheumatic heart disease
 - right-sided endocarditis
 - carcinoid syndrome

Congenital Causes

- PR is sometimes congenital in origin
 - pulmonary atresia
 - subvalvular PS.

Iatrogenic Causes

- PR is occasionally induced during intervention
 - surgery
 - valvotomy
 - angiography

Secondary Cause

- PR is most commonly secondary in nature
 - pulmonary hypertension

Echo Features of PR

2-D Echo PLAX View

- The right ventricle is dilated and hyperkinetic due to volume overload. The motion of the RV free wall is exaggerated.
- The dimension of the RV often exceeds 23 mm. There is paradoxical motion of the interventricular septum (IVS).

2-D Echo PSAX View

- The pulmonary artery is dilated and its diameter exceeds that of the aorta (20-37 mm).
- The PV leaflets are thick and immobile in rheumatic heart disease and carcinoid syndrome. Vegetations are observed in case of endocarditis.
- In PV atresia, the pulmonary cusps are replaced by a ridge of embryonic valve tissue.

M-Mode PV Level

- In valvular PS along with PR, there is a prominent 'a' wave on the pulmonary valve trace.
- In subvalvular PS along with PR, there is systolic fluttering of the pulmonary valve leaflets
- In PR due to pulmonary hypertension, the 'a' wave on the valve trace is reduced in size or absent.

Color Flow Mapping

- A regurgitant jet is visualized in the RV outflow tract (RVOT) just below the pulmonary valve (PV) (Fig. 13.40).

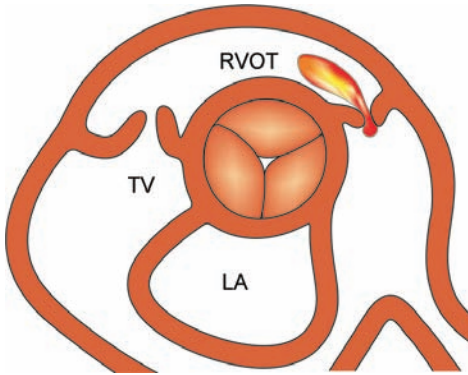


Fig. 13.40: Color flow map of the pulmonary valve from PSAX view showing a regurgitant jet in the RV outflow tract

- The ratio of diastolic reverse flow to systolic forward flow at the PV level indicates the severity of PR (Table 13.15).
- Severity of PR is also indicated by the extent to which the PR jet enters the right ventricle.
- Aliasing (mosaic pattern) of the color flow map indicates turbulent flow with high velocity and severe PR.

TABLE 13.15

Assessment of PR severity from regurgitant fraction

<i>PR severity</i>	<i>PR fraction</i>
Mild	< 40
Moderate	40–55
Severe	> 55

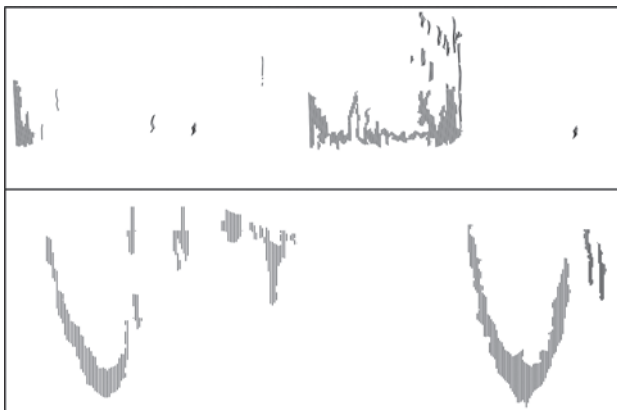


Fig. 13.41: CW Doppler of pulmonary valve from PSAX view showing a “bullet-shaped” signal in the RV outflow tract

Doppler Echo

- On CW Doppler, a dense and intense flow signal is detected in the right ventricular outflow tract (RVOT).
- A short deceleration time (rapid pressure decline) with a steep slope of the CW Doppler signal correlates with the severity of PR (Fig. 13.41).
- CW Doppler may inadvertently detect nearby coronary sinus flow due to its inability to precisely localize the flow signal.
- On PW Doppler, mapping progressively deeper into the right ventricle, till flow is not seen, can quantify the severity of PR.
- A jet extending lower down from the pulmonary valve indicates severe pulmonary regurgitation.



14

Pericardial Diseases

Clinically important diseases of the pericardium are:

- Pericardial effusion
- Cardiac tamponade
- Constrictive pericarditis.

PERICARDIAL EFFUSION

The pericardium is a sac-like structure surrounding the heart. It consists of two layers with a potential space between them.

The pericardial space between the visceral and parietal layers of the pericardium normally contains less than 50 ml fluid. Excessive accumulation of fluid in this space is known as pericardial effusion.

Echo Features of Pericardial Effusion

Pericardial effusion creates an echo-free space posteriorly between the left ventricular posterior wall and the pericardium as well as anteriorly between the right ventricular free wall and the anterior chest wall.

Posterior accumulation of fluid precedes collection of fluid in the anterior space (Fig. 14.1).

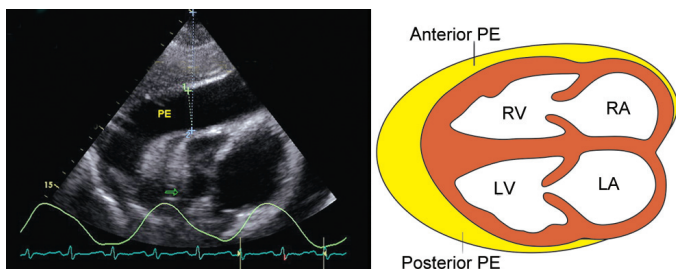


Fig. 14.1: An echo-free space around the heart is seen in pericardial effusion

Quantification of Pericardial Effusion

M-Mode Scan

The quantity of pericardial fluid can be gauged from the width of the echo-free space on M-mode scan from the PLAX view. This is shown in Table 14.1.

2-D Echo

A 2-D image of the 4-chamber view is frozen and two tracings are taken by planimetry:

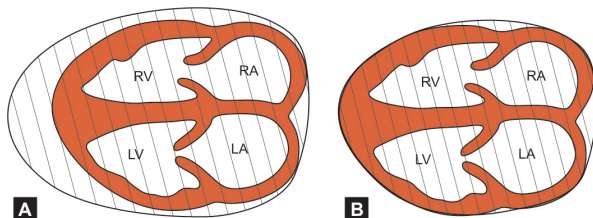


Fig. 14.2: Calculating the quantity of pericardial effusion;
 Volume of effusion = Volume A – Volume B

TABLE 14.1

Estimating the quantity of pericardial effusion from the width of echo-free space

<i>Amount</i>	<i>Volume</i>	<i>Posterior space</i>	<i>Anterior space</i>
Small	< 200 ml	< 1 cm	—
Moderate	200–500 ml	1–2 cm	< 1 cm
Large	> 500 ml	> 2 cm	> 1 cm

A: Around the pericardium [Volume of heart + effusion]

B: Around the heart [Volume of the heart alone]

Volume of the pericardial effusion is equal to Volume A minus Volume B (Fig. 14.2).

Causes of Pericardial Effusion

- Infection : viral, bacterial and tubercular
- Malignancy : metastasis, direct spread
- Trauma : accidental, surgical
- Auto-immune : rheumatoid arthritis, SLE
- Metabolic : uremia, myxoedema
- Toxic : drug-induced, radiation
- Injury : post-myocardial infarction

Assessing the Cause of Effusion

- Transudate : sonolucent echo-free fluid
- Sanguinous : high echo-density of fluid
- Tubercular : fibrinous strands in effusion
- Malignant : echo-dense areas deforming smoothness of pericardium

Pitfalls in the Diagnosis of Effusion

False Negative

A pericardial effusion may be missed on echo if:

- It is loculated and out of path of the beam.
- The echo-machine is on a high-gain setting.
- The cardiac image is large and extends beyond the far border of the screen.

False Positive

A pericardial effusion may be falsely diagnosed if:

- There is an echo-free space behind the posterior wall due to one of these structures:
 - an enlarged left atrium
 - descending thoracic aorta
 - aneurysm of posterior wall
 - pericardial cyst or fat pad.

Note

- Calcified mitral annulus or prominent papillary muscle is mistaken for the left ventricular posterior wall and the latter resembles a pericardial effusion.
- As a differentiating feature, only the left ventricular posterior wall would thicken in systole.

Differentiation from Thickened Pericardium

If the pericardium is thickened or there is an organized exudate, it can be differentiated from an effusion by these features:

- Increasing gain-settings of the machine reveals multiple linear pericardial echoes.
- The thickened pericardium retains its parallelity to the epicardial surface of the heart.
- Width of the thickened pericardium remains the same irrespective of the stage in cardiac cycle, phase of respiration and body posture.

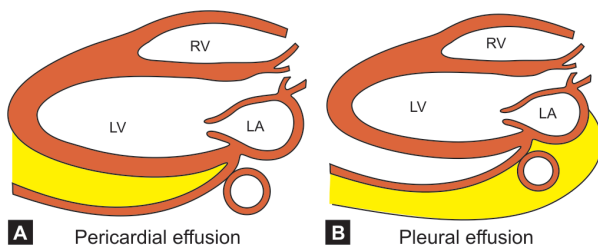


Fig. 14.3: Differences between pericardial effusion (A) and pleural effusion (B)

Differentiation from Pleural Effusion

A pericardial effusion sometimes need to be differentiated from a left pleural effusion (Fig. 14.3).

Unlike in case of pleural effusion, the echo-free space due to pericardial effusion:

- is never more than 4 cm in width
- terminates abruptly at the A-V groove
- does not extend behind descending aorta.

Note

- If a pericardial effusion coexists with a pleural effusion, a linear echo (thick pericardium) separates the two.

CARDIAC TAMPONADE

Cardiac tamponade is a serious clinical situation in which ventricular filling and cardiac output are impaired. These hemodynamic changes are due to an external pressure exerted on the heart by a large pericardial effusion.

Tamponade results from a large effusion or rapid accumulation of a small effusion. A large effusion can accumulate gradually without causing tamponade if the pericardial sac gets adequate time to stretch.

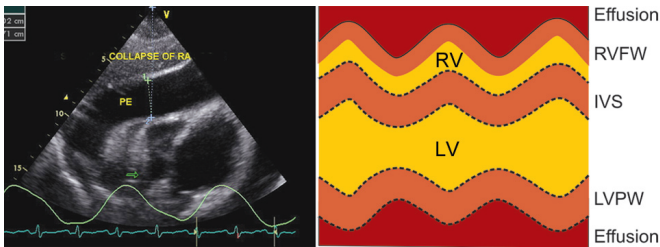


Fig. 14.4: M-mode scan of the ventricles showing diastolic collapse of the right ventricle

Echo Features of Cardiac Tamponade

M-Mode Scan

- Large volume of pericardial effusion (see above)
- Diastolic collapse of the right atrium and right ventricle are observed on M-mode. The right ventricular free wall moves towards (normally moves away) the interventricular septum in diastole, obliterating the right ventricular cavity (Fig. 14.4).

Note

- duration and degree of right atrial and ventricular collapse correlates with the severity of tamponade.
- collapse may be absent if there is right ventricular hypertrophy or volume overload since the thick or distended right ventricle will not collapse.
- right ventricular collapse is also not observed if there are pericardial adhesions.

2-D Echo

- Swinging heart with the anterior and posterior walls moving in the same direction during most of cardiac cycle.

- The heart swings because of undulation of chambers caused by displacement of fluid within the confines of a stretched pericardial sac. Increase in volume of one chamber leads to decrease in volume of the other.
- Anterior mitral leaflet shows pseudo-SAM and pseudo-MVP.
 - Pseudo-systolic anterior motion (SAM) occurs during anterior swing of the heart while pseudo-mitral valve prolapse (MVP) occurs during posterior swing of the heart.

Doppler Echo

- Exaggerated respiratory variation of the transvalvular velocity.
 - Normally during inspiration, the flow velocity across the tricuspid valve increases and flow velocity across the mitral valve decreases. These changes are minimal and normally do not exceed 15%. In tamponade these respiratory variations are exaggerated and exceed 25%.

Echo and Pericardiocentesis

- Echo helps in safe performance of therapeutic echo-guided needle aspiration of pericardial fluid.
- The procedure is known as pericardiocentesis. The site of fluid collection is accurately localized.
- Relief of tamponade is a life-saving procedure the success of which can be gauged by post-procedure repeat echo to visualize the residual fluid.
- After pericardiocentesis, RV diastolic collapse reverses sooner while RA collapse persists longer.
- Therefore, RA diastolic collapse is a more sensitive indicator of impending cardiac tamponade.

CONSTRICTIVE PERICARDITIS

In pericardial constriction, the pericardium becomes fibrotic, thick, rigid and often calcific. Constrictive pericarditis limits the expansion of the ventricles and thus impairs diastolic filling.

Echo Features of Constrictive Pericarditis

M-Mode Scan

- On M-mode, the thickened pericardium appears as a dark thick echo line or as multiple discrete parallel lines.
- Findings depend upon the gain-setting of the echo machine.
- Low gain-setting underestimates while high gain-setting overestimates thickening of the pericardium.
- Calcification of the pericardium, either localized or generalized, casts a bright reflection similar to that of bone.

2-D Echo

- There is abrupt anterior motion of interventricular septum (IVS) in diastole followed by paradoxical systolic motion.
- Rapid early diastolic descent of left ventricular posterior wall (LVPW) with flat motion in mid and late diastole.
- The left ventricle expands throughout diastole. In pericardial constriction, the LV expands only in the first part of diastole.
- This subtle sign may be picked-up by recording the echo study and then reviewing the left ventricle frame by frame.
- This diastolic filling pattern is seen as the dip and plateau pattern (square-root sign) on the left ventricular pressure trace.
- On examining the jugular venous pulse (JVP), this pattern is observed as a prominent 'y' descent.

USG Abdomen

- The inferior vena cava is dilated without an inspiratory reduction in diameter, due to high venous pressure.
- On abdominal sonography, there is hepatomegaly, dilatation of hepatic veins, splenomegaly and ascites.

Doppler Echo

- On Doppler echo, the mitral valve inflow trace shows of a restrictive pattern diastolic left ventricular filling.
- There is increase in early diastolic velocity with rapid deceleration resulting in a tall E wave and a very small A wave (Fig. 14.5).
- There is exaggerated respiratory variation of mitral valve (MV) and tricuspid valve (TV) inflow velocity.
- MV E wave amplitude decreases by more than 25% in inspiration and TV E wave decreases by more than 25% during expiration.

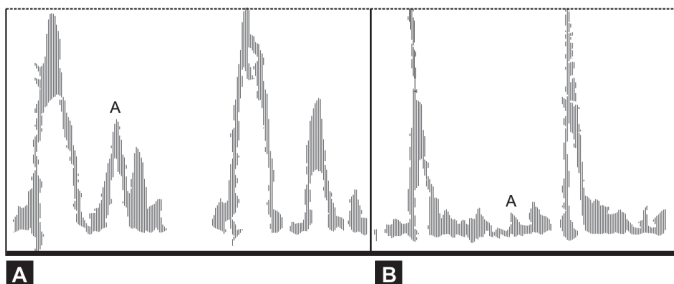


Fig. 14.5: Mitral inflow spectral space on PW Doppler showing:
A. Normal E wave, normal A wave
B. Tall E wave, very small A wave

Differentiation from Restrictive Cardiomyopathy

It is particularly difficult to distinguish constrictive pericarditis from restrictive cardiomyopathy or a restrictive myocardial dysfunction due to infiltration (see Cardiomyopathies).

Direct pressure measurements at cardiac catheterization are required to clinch the diagnosis. Differentiation between these two clinical conditions is crucial since it has important management implications.

Nevertheless, subtle differences between the two conditions exist which are enumerated in Table 14.2.

TABLE 14.2

Differences between constrictive pericarditis and restrictive cardiomyopathy

	<i>Constrictive pericarditis</i>	<i>Restrictive cardiomyopathy</i>
Pericardium	Thick	Normal
Myocardium	Normal	Thick
Ventricles	Normal	Obliterated
Atria	Normal	Dilated
LV function	Normal	Impaired
MV and TV	Normal	Regurgitation
MV inflow	Abrupt halt	Slow relaxation



15

Endocardial Diseases

Endocarditis is inflammation of the inner surface of the heart, including the lining of heart valves.

Inflammatory and/or infected material accumulates to cause discrete lesions called vegetations.

Vegetations are made-up of a mixture of necrotic material, fibrin, platelets and leukocytes.

CLASSIFICATION OF ENDOCARDITIS

Infective

- Bacterial : *Streptococcus*
Staphylococcus
G-negative bacilli
- Fungal : *Aspergillus*
Candida
- Others : *Coxiella*
Chlamydia

Non-infective

- Malignant disease : marantic endocarditis
- Collagen disorder : verrucose endocarditis
(Libman-Sack's)
- Rheumatic fever : rheumatic pancarditis.

PREDISPOSING CARDIAC LESIONS

Common Lesions

- Valvular heart disease
 - Native valve : bicuspid aortic valve
mitral valve prolapse
 - Rheumatic valve : mitral regurgitation
: aortic regurgitation
 - Prosthetic valve : bioprosthetic valve
mechanical valve
 - Tricuspid valve : IV substance abuse
CVP line insertion
- Congenital heart disease
 - Ventricular septal defect
 - Patent ductus arteriosus
 - Coarctation of the aorta

Note

- Infection at the site of patent ductus or aortic coarctation is actually endoarteritis and not endocarditis.

Uncommon Lesions

- Pulmonary stenosis
- Atrial septal defect
- HOCM/IHSS
- A-V fistula.

Note

- Although vegetations are usually attached to cardiac valves, the IV septum (VSD), left atrium (MR) and LV outflow tract (HOCM) are exceptions.

INDICATIONS FOR SERIAL ECHOES

- Detection of cardiac vegetations
- Demonstration of local complications
- Diagnosis of a predisposing lesion
- Evaluation of response to treatment
- Proper timing of surgical intervention.

ECHO FEATURES OF ENDOCARDITIS

Detection

- On M-mode scan, thick, dense and irregular multiple echo lines are seen on one or more valve leaflets (Fig. 15.1).
- On 2-D echo, vegetations are detected as mobile, irregular echo-reflective masses attached to a valve cusp or a cardiac lesion and prolapsing into one of the chambers.
- As a rule, vegetations move in concert with the leaflet and in unison with blood flow.
- They do not impair valve excursion and are usually seen in one phase of the cardiac cycle, either systole or diastole.

Site

- The site of vegetations depends upon the underlying predisposing cardiac lesion.

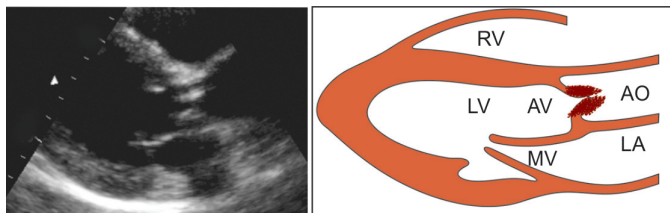


Fig. 15.1: PLAX view showing vegetations on aortic valve leaflets

- Since they move in unison with blood flow, they are seen in the left atrium in MR, in the LV outflow tract in AR and on the right ventricular side of a VSD.

Size

- The size of vegetations varies from 2 mm to 2 cm. Vegetations smaller than 2 mm are difficult to visualize.
- Transesophageal echo has vastly improved the detection of vegetations.
- Large vegetations are particularly associated with fungal and tricuspid valve endocarditis.
- Vegetations shrink as they heal although rapid shrinkage suggests embolization.
- Mitral valve vegetations are larger than the aortic valve vegetations (Fig. 15.2).

Shape

- Fresh vegetations are irregular and lumpy but they smoothen as they heal (Table 15.1).
- They may be sessile (nodular thickening) or pedunculated.

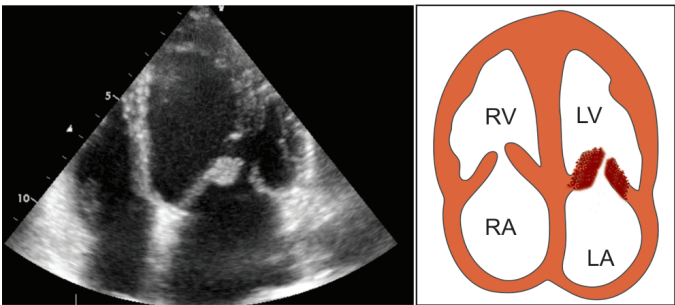


Fig. 15.2: A4CH view showing vegetations on mitral valve leaflets

TABLE 15.1**Differences between fresh and healed vegetations**

	<i>Fresh</i>	<i>Healed</i>
Size	Large	Small
Shape	Irregular	Smooth
Mobility	Mobile	Immobile
Echogenicity	Isoechoic	Hyperechoic

Echogenicity

- Fresh vegetations are isoechoic with the leaflet and they get brighter (hyperechoic) as they heal (Table 15.1).

Mobility

- High mobility is observed in large and pedunculated vegetations while mobility is low in small and sessile vegetations.
- Mitral vegetations are more mobile than aortic vegetations (Table 15.2) and mobility declines as healing occurs.

TABLE 15.2**Differences between mitral and aortic vegetations**

	<i>Mitral</i>	<i>Aortic</i>
Size	Large	Small
Site	In LA	In LVOT
Mobility	Mobile	Immobile
Seen in	Systole	Diastole

Differentiation from Other Masses

- It may be sometimes difficult to differentiate vegetations from other valvular abnormalities. These are:
 - myxomatous changes in a floppy valve
 - thrombus formation on a prosthetic valve
 - calcified nodules on a thick rheumatic valve.
- It may also be difficult to diagnose vegetations in the presence of reverberation and masking artefacts caused by:
 - calcified valve annulus
 - mechanical prosthetic valve.
- A rapid change in echo findings on serial echocardiograms with suggestive signs and symptoms favors the diagnosis of endocarditis.

Role of Echo in Endocarditis

- Endocarditis is a clinical diagnosis made on the basis of history, clinical examination, hematological investigations, blood cultures and echocardiography.
- Absence of vegetations on echo does not exclude the diagnosis of endocarditis that has been strongly suspected on clinical grounds.
- It is not possible to distinguish between infective and noninfective vegetations by echocardiography alone.
- Cardiac involvement in a collagen disorder or malignant disease in the absence of infective features is suggestive of verrucose or marantic endocarditis.
- Patients of endocarditis without demonstrable vegetations on echo carry a better prognosis.
- Large vegetations indicate poor prognosis with a greater likelihood of complications and need for surgical intervention.

Duke Criteria for Endocarditis

Major Criteria

- Persistently positive blood cultures with an organism known to cause endocarditis.
- Echo-wise definite vegetation or abscess or new prosthetic dehiscence or native valve regurgitation.

Minor Criteria

- Predisposing heart condition or IV drug abuse.
 - Fever with constitutional symptoms, e.g. myalgias, arthralgias, malaise.
 - Vascular phenomena, e.g. emboli, septic infarcts, mycotic aneurysm.
 - Immunologic events, e.g. glomerulonephritis, vasculitis, retinal lesion.
 - Echo consistent with vegetation but no new abnormality detected.
 - Positive blood culture, but not major criteria
- Either 2 major criteria or 1 major criteria with 3 minor criteria are required for the diagnosis of endocarditis.

Detection of Local Complications

- Endocarditis can lead to valve destruction, valvular regurgitation, appearance of a new murmur or change in a pre-existing cardiac murmur.
- This occurs due to prolapse, perforation or rupture of a valve leaflet, as the endocarditis spreads.
- There can be an abscess around a valve annulus or in the interventricular septum with conduction block.
- An aortic root abscess can result in rupture of the sinus of Valsalva or obstruct the coronary ostia.

- Abscess formation can be visualized as an echo-free space in the paravalvular area.
- A large vegetation as in case of fungal endocarditis can obstruct the aortic valve.
- Heart failure may occur due to associated myocarditis, pericardial effusion or acute valvular regurgitation.

Evaluation of Response to Treatment

- Healed vegetations differ from fresh ones by being smaller, smoother and hyperechoic.
- Shrinkage of vegetations alone does not indicate cure while rapid shrinkage suggests embolization.
- Increase in vegetation size indicates persistence of infection and ineffective antimicrobial therapy.
- The risk of embolization persists for up to 6 months after bacteriological cure.
- How often serial echos should be done while the patient is receiving antibiotics is a matter of debate.
- It is difficult to justify frequent echos unless this will clearly alter clinical decisions in management.
- However, repeat echo should be definitely carried out if there is deterioration in the patient's clinical condition.

Timing of a Surgical Intervention

The decision to intervene with a surgical procedure in endocarditis is taken in the following situations:

- Fungal endocarditis
- Failure of antibiotic therapy
- Prosthetic valve endocarditis
- Sinus of Valsalva aneurysm

- Large vegetation with embolization
- Large vegetation with valve obstruction
- Abscess in aortic root or IV septum
- Valve destruction and regurgitation
- Worsening congestive heart failure.

Indications for Transesophageal Echo

A transthoracic echo needs to be supplemented with a transesophageal echo in the following situations:

- Normal transthoracic echo with high clinical suspicion
- Poor thoracic window
- Aortic root abscess formation
- Leaflet perforation or rupture
- Aneurysm sinus of Valsalva
- Prosthetic valve endocarditis.



16

Intracardiac Masses

CARDIAC TUMORS

Classification of Tumors

Secondary Tumors (majority)

- Metastatic : lung (commonest)
breast, kidney, liver
melanoma, leukemia.

Primary Tumors (minority)

- Benign : myxoma (commonest)
rhabdomyoma, fibroelastoma
fibroma, lipoma, angioma.
- Malignant : angiosarcoma (commonest)
rhabdomyosarcoma
fibrosarcoma, liposarcoma.

Echo Features of Tumors

- 2-D echo shows cardiac tumors as echogenic masses within a cavity of the heart. It tells about the site, size, number, mobility and attachment of tumors to the chamber wall.
- Additional information provided by echo includes obstruction of a valve by the tumor, ventricular dysfunction due to myocardial infiltration and malignant pericardial effusion.

Role of Echo in Tumors

- Echo is still the most important diagnostic tool for the detection of cardiac tumors.
- Although it gives an indication of the nature of tumor, it cannot differentiate between benign and malignant tumors.
- As with all echo studies, multiple views should be obtained to delineate the tumor morphology in detail.
- Transesophageal echocardiography (TEE) is more sensitive in detecting tumors than transthoracic echo, particularly for small masses. Location of the tumor and tissue characteristics are better identified by TEE.
- Information about the site, size, mobility, number and attachment of tumors is particularly helpful while planning a surgical intervention.
- Secondary echo findings include left ventricular dysfunction due to myocardial infiltration and effusion due to pericardial involvement.
- Vast majority of cardiac tumors are secondary tumors and all of them are malignant since they have already metastasized via the blood-stream or lymphatic system. They occur in about 10% of all fatal malignancies.
- The lungs are the most common primary site (30% of cases) because of their close proximity to the heart and direct invasion of the tumor.
- Myxoma in the left atrium is by far the most common primary cardiac tumor and it is worth discussing.

LEFT ATRIAL MYXOMA

Clinical Features of LA Myxoma

- Myxoma is a gelatinous and friable cardiac tumor of connective tissue origin.
- It is mostly solitary and occurs three times more often in the left atrium than in the right atrium.

- Myxomas can be found at any age and in either sex but are more commonly observed in middle-aged females.
- Although benign in the neoplastic sense, myxoma is far from being benign in its clinical effects.
- The effects of myxoma are related to:
 - local effects like valvular obstruction which causes dyspnea and can even be fatal when sudden.
 - distal embolism due to bits of friable tissue breaking away from the main tumor mass.
 - constitutional features such as fever, arthralgias, anemia and weight loss with an elevated ESR.

Echo Features of LA Myxoma

- On 2-D echo, the myxoma is seen as a mass in the left atrial cavity measuring 2 to 8 cm in size. It is usually pedunculated, rarely sessile and attached to the margin of foramen ovale on the inter-atrial septum.
- The myxoma is a lobulated mass with a variable echodensity. The center is echolucent due to necrosis and the periphery is echodense due to calcification.
- Most myxomas are mobile and prolapse into the mitral valve orifice in diastole (Fig. 16.1). An atrial myxoma is non-prolapsing if it is either sessile or very large in size.

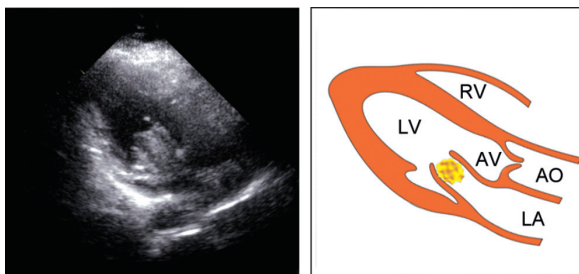


Fig. 16.1: PLAX view showing a left atrial myxoma prolapsing into the mitral valve orifice

Differentiation from Mitral Stenosis

- On M-mode scan, atrial myxoma produces cloudy echoes in the mitral inflow tract in diastole and in the left atrium in systole. Characteristically, an echo-free zone is seen within the valve in early diastole, as the valve opening precedes prolapse of the myxoma (Fig. 16.2). This echo-free zone is not observed in mitral stenosis.
- Since the myxoma causes mitral inflow obstruction, there is flattening of the EF slope of anterior mitral leaflet (AML) as in mitral stenosis. However, unlike in mitral stenosis, there is no thickening or doming of the AML or paradoxical motion of the posterior mitral leaflet (PML).
- On Doppler echo, the myxoma produces a high velocity signal as does mitral stenosis. The difference in the signal due to myxoma is that it is irregular due to multiple jets around the obstructing tumor.

Note

Since the extent of prolapse of the myxoma into the MV inflow changes with posture, the 2-D, M-mode and Doppler findings vary with the body position.

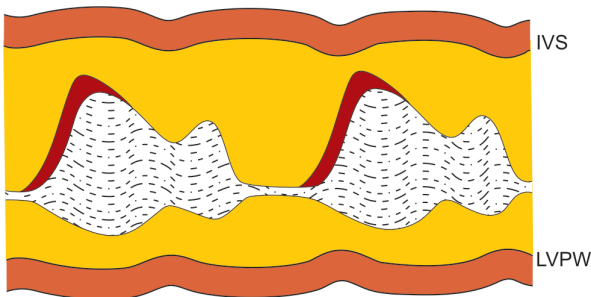


Fig. 16.2: M-mode scan of the mitral valve showing:

- cloudy echoes in diastole
- an early echo-free zone

Differentiation from LA Thrombus

- A left atrial myxoma needs to be differentiated from a thrombus at this site.
- Unlike a myxoma, a LA thrombus is close to the LA posterior wall, not pedunculated and it stays in the atrial cavity.
- It is rounded in shape with a more echogenic center (old thrombus) and the mitral valve is often diseased.
- The differences between a left atrial thrombus and a myxoma are enumerated in Table 16.1.

TABLE 16.1

Differences between LA thrombus and LA myxoma

	<i>LA thrombus</i>	<i>LA myxoma</i>
Site	Posterior wall	Atrial septum
Shape	Rounded	Lobulated
Attachment	Free-floating	Pedunculated
Echogenicity	Echogenic	Echolucent
Prolapse in MV	Rare	Often
Mitral valve	Diseased	Normal

Differentiation from Other Conditions

- On the basis of 2-D echo, myxoma needs to be differentiated from a left atrial thrombus.
- On M-mode, myxoma resembles mitral stenosis from which it can be differentiated by subtle features.
- When the myxoma prolapses into mitral valve inflow, it can produce the auscultatory findings of mitral stenosis.
- The constitutional features of myxoma such as fever, arthralgia and anemia need to be differentiated from symptoms due to other clinical conditions.
- These diseases include bacterial endocarditis, collagen disorder and occult malignancy.

ATRIAL THROMBUS

Left Atrial Thrombus

- Requisites : diseased mitral valve
large left atrium
atrial arrhythmia.
- Predisposing conditions : mitral stenosis
prosthetic valve
atrial fibrillation.
- Locations : posterior atrial wall
free-floating in atrium
(ball-valve thrombus)
left atrial appendage.
- Other LA masses : left atrial myxoma
dilated coronary sinus
flail mitral leaflet
reverberation artefact
(calcific mitral annulus).
- Linear LA structures : cor triatrium
supravalvular ring
anomalous pulmonary veins.

Right Atrial Thrombus

- Requisites : indwelling venous line
spread along vena cava.
- Predisposing conditions : Swan-Ganz catheter
renal-cell carcinoma.
- Appearance : popcorn on string.

- Other RA masses : right atrial myxoma
metastatic tumor
Chiari network
(congenital remnant)
Eustachian valve
(guarding IVC orifice).
- Linear RA structures : Swan-Ganz catheter
pacemaker lead.

Echo Features of Atrial Thrombus

- On 2-D imaging, an atrial thrombus appears as a bright, well-defined rounded mass arising from the posterior atrial wall or floating freely (Fig. 16.3).
- A thrombus in the left atrial appendage is more readily identified on transesophageal echocardiography (TEE).
- A left atrial thrombus needs to be differentiated from a myxoma at this site by the features mentioned in Table 16.1.

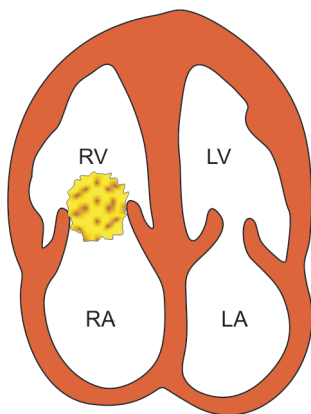


Fig. 16.3: A4CH view showing a mass in the right atrium prolapsing through the tricuspid valve

A thrombus is rounded, freely mobile with an echogenic center while a myxoma is lobulated, pedunculated with an echolucent center.

- A rotatory motion of blood in the left atrium occurs when blood from pulmonary veins meets stagnant atrial blood. It produces a swirling 'smoke-like' pattern of echodensities within the left atrium due to clumping of RBCs (rouleaux formation) which become more echo-reflective.
- This is known as the 'whirlpool sign' or 'spontaneous contrast effect'. These signs indicate the presence of or a propensity towards thrombus formation.
- A ball-valve thrombus can rarely obstruct the mitral valve orifice and prove fatal. When identified, it is an indication for urgent surgical intervention (Fig. 16.4).
- In a patient of mitral stenosis with atrial fibrillation who presents with a stroke due to cerebral embolism, it can be safely presumed that there is a left atrial thrombus.
- Failure to demonstrate an atrial thrombus could be due to its small size, location in the atrial appendage or the fact that it has already embolized.

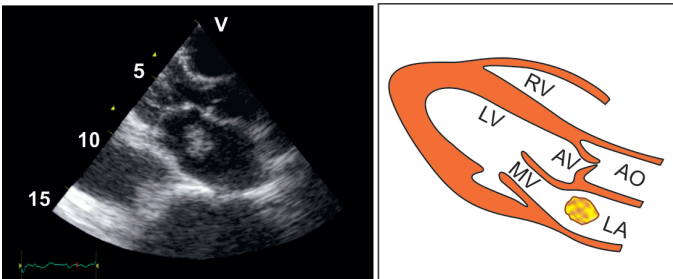


Fig. 16.4: A4CH view showing a thrombus in the left atrium floating freely in the chamber

- When planning balloon mitral valvuloplasty, transesophageal echo is useful to detect a left atrial thrombus, particularly in the left atrial appendage.

VENTRICULAR THROMBUS

- Requisites : dilated ventricular cavity
reduced wall contractility
stagnation of blood flow.
- Predisposing conditions : dilated cardiomyopathy
myocardial infarction
ventricular aneurysm.
- Type of thrombus : pedunculated (ball-like)
laminated (mural).
- Other LV masses : LV tumor
papillary muscle
technical artefact
LV false tendon.
- Other RV masses : RV tumor
technical artefact
RV moderator band.

Echo Features of Ventricular Thrombus

- On 2-D imaging, a ventricular thrombus appears as a bright well-defined rounded mobile mass, which protrudes into the ventricular cavity (Fig. 16.5).
- A pedunculated thrombus is attached to the ventricular wall through a stalk.
- The mobility of the thrombus is not synchronous with the ventricular wall.
- The thrombus may be highly echogenic due to calcification or variable in echodensity due to necrotic areas. In the latter case, it is more likely to embolize.

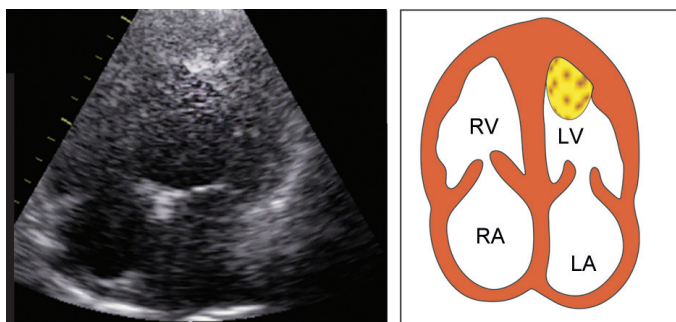


Fig. 16.5: A4CH view showing a pedunculated thrombus protruding into the left ventricular cavity

- A mural ventricular thrombus is a flat, laminated mass, contiguous with the ventricular wall (flat thickening) with which it moves synchronously (Fig. 16.6).
- Laminated thrombus is more echogenic than the myocardium and less likely to embolize than a mobile thrombus.

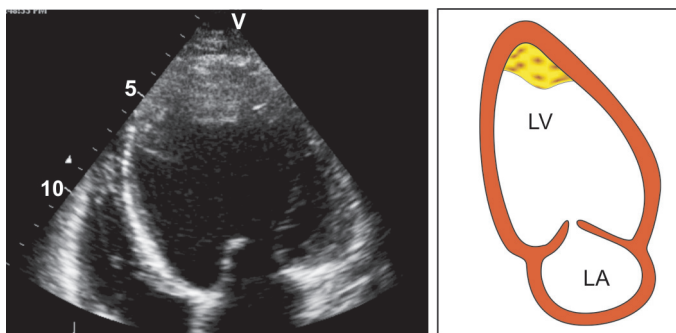


Fig. 16.6: A4CH view showing a laminated thrombus contiguous with the left ventricular wall

- A fresh thrombus of recent origin may be isoechoic with the adjacent myocardium.
- Sometimes, waves of cloudy echoes drift in a swirling pattern representing stagnant blood and creating boundaries of acoustic impedance and increased echogenicity.
- They represent a heightened tendency towards genuine thrombus formation.

Differentiation from Other Ventricular Masses

- Mural thrombus can be distinguished from localized myocardial thickening since myocardium thickens during systole while a thrombus does not.
- Thrombus can be differentiated from a cardiac tumor by the fact that adjacent wall motion is almost always abnormal in case of a thrombus and often normal in case of a tumor.
- Thrombus always has a clear identifiable edge while an artefact caused by stagnated blood has a hazy appearance.
- On color flow mapping, the flow stops abruptly at the edge of a thrombus but not at the edge of an artefact.



17 Thromboembolic Diseases

A fairly common question asked, when an echo is requested in a patient with transient ischemic attack or cerebrovascular accident is:

Is there a cardiac source of embolism?

INDICATIONS FOR ECHO IN CVA

- To detect a lesion with high risk of thromboembolism.
 - mitral stenosis, left atrial dilatation, atrial fibrillation (see Valvular Diseases)
 - prosthetic mitral or aortic valve, mitral valve prolapse
 - dilated ventricle, hypokinesia, ventricular aneurysm (see Intracardiac Masses).
- To detect a direct source of embolism from the heart.
 - left atrial thrombus
 - left atrial myxoma
 - ventricular thrombus (see Intracardiac Masses).
- To detect an indirect source of peripheral embolism.
 - patent foramen ovale with atrial septal aneurysm allowing passage of venous thrombus from the right to left. (see Congenital Diseases)

- aortic atheroma in the descending thoracic aorta that is large, mobile, pedunculated and ulcerated. (see Diseases of Aorta)

Who Should HAVE an Echo?

Not every patient who has had a TIA or cerebral stroke needs echocardiography. However, an echo is certainly important in the following situations:

- Abrupt occlusion of a peripheral artery in the lower limb or a major visceral blood vessel.
- Young patient (< 50 years) with acute cerebral infarction.
- Older patient (> 50 years) without evidence of cerebrovascular disease or any other obvious cause of CVA.
- Strong clinical suspicion of cardiac embolism, e.g. recurrent peripheral or cerebral embolic events.
- Clinical evidence of relevant structural heart disease, e.g. mitral stenosis, or dilated left ventricle.
- Clinical suggestion of cardiac conditions causing embolism, e.g. endocarditis or left atrial myxoma.
- Abnormal ECG findings indicating underlying heart disease, e.g. Q waves, loss of R waves, ST-T changes or arrhythmias such as atrial fibrillation and ventricular tachycardia.

Who Should HAVE a TEE?

Many a time, a cardiac source of embolism is evident on conventional transthoracic echo. Sometimes a subsequent transesophageal echo (TEE) is indicated in these situations:

- Young patient (< 50 years) with TIA or stroke even in the absence of clinical cardiac abnormalities.
- Older patient (> 50 years) with no other cause of CVA.
- Normal or inconclusive transthoracic scan with strong clinical suspicion of cardiac embolism.

The following rare conditions can only be diagnosed by transesophageal echo (TEE):

- Occult left atrial myxoma
- Left atrial appendage thrombus
- Left atrial spontaneous contrast effect
- Patent foramen ovale with atrial septal aneurysm
- Aortic atheroma in the descending thoracic aorta.

Who Should NOT HAVE an Echo?

An echo is not indicated in TIA or stroke in these situations:

- When there is evidence of intrinsic cerebrovascular disease sufficient to cause the clinical event, e.g. more than 70% carotid stenosis on Doppler scan.
- When the results of echocardiography will not influence therapeutic decisions, e.g. diagnosing patent foramen ovale in a patient already on anticoagulants.

THROMBOEMBOLISM IN MITRAL STENOSIS

- The risk of thromboembolism in mitral stenosis is very high, particularly if atrial fibrillation is present and more so if it is intermittent.
- Mitral stenosis can be safely assumed to be the cause of cerebral infarction even in the absence of a demonstrable left atrial thrombus.
- A thrombus that is too small for detection, an atrial appendage thrombus and one that has already embolized may be missed on echo.
- In such patients anticoagulation can be initiated rightaway provided there is no systemic contraindication to anticoagulants and cerebral hemorrhage has been excluded by a cranial CT scan.
- Occasionally, an echo may show a large left atrial ball thrombus which is an indication for urgent surgery, since this is potentially fatal if it occludes the valve.



18

Systemic Diseases

The echo abnormalities observed due to cardiac involvement in certain systemic diseases, are enumerated in this section. It must be remembered that only some and not all of the echo features may be present in any given case.

Diabetes Mellitus

- Effects of coexistent hypertensive heart disease
- Effects of coexistent coronary artery disease
- Left ventricular diastolic dysfunction (early stage)
- Left ventricular systolic dysfunction (late stage).

Hypothyroidism

- Left ventricular hypertrophy (eccentric)
- Left ventricular systolic dysfunction
- Pericardial effusion (minimal)
- Associated sinus bradycardia.

Chronic Anemia

- Left ventricular hypertrophy (eccentric)
- Left ventricular dilatation (volume overload)
- Left ventricular diastolic dysfunction
- Associated sinus tachycardia.

Rheumatic Fever

- Left ventricular dilatation (myocarditis)
- Mitral or aortic regurgitation (valvulitis)
- Mild pericardial effusion (pericarditis).

Chronic Renal Failure

- Pericardial effusion (uremic)
- Left ventricular systolic dysfunction
- Effects of coexistent hypertensive disease
- Effects of coexistent coronary artery disease.

Malignant Disorder

- Pericardial effusion (metastatic)
- Cardiac tumor (direct invasion)
- Marantic endocarditis.

Collagen Disorder

- Pericarditis and effusion
- Myocardial infiltration
- Valvular regurgitation (MR, AR)
- Libman-Sacks endocarditis.

HIV Infection

- Dilated cardiomyopathy and myocarditis
- Pericardial effusion and tamponade
- Infective endocarditis (bacterial or fungal)
- Non-infective (marantic) endocarditis.
- Cardiac metastasis (Kaposi's sarcoma).



Index

Page numbers with *f* indicate figure.

A

Acute

- mitral regurgitation 103, 114
- myocarditis 76
- pericardial effusion 119
- viral myocarditis 75

Amyloidosis 95

Aneurysm

- of aorta 145, 150
- sinus of Valsalva 143*f*, 147, 251

Aneurysmal dilatation 145*f*

Angiography 228

Ankylosing spondylitis 215

Anomalous

- left coronary artery 92
- origin of artery 103
- pulmonary veins 155

Anterior

- aortic swing 57, 143
- cuspid 63
- mitral leaflet 60, 89, 96, 98, 100, 168
- myocardial infarction 92
- right coronary cusp 62

Aortic

- annulus 56, 141
- cuspid separation 57

dissection 150, 215

outflow velocity 60

regurgitation 75, 150, 214, 270

root 43, 57

abscess formation 251

diameter 57

dilatation 150, 215

dimension 59

width 141

stenosis 104, 201

valve 36, 41, 43, 62

cusps 38

level 36, 38, 38*f*, 52, 57, 59

orifice area 57

regurgitation 149

stenosis 75, 95, 120

Aortitis 145

Aortoseptal discontinuity 161

Applications of color Doppler 28

Ascending aorta 43

Assessing

severity of

MS 174

PS 228

Assessment of left ventricular

function 103

- Associated sinus
 - bradycardia 269
 - tachycardia 269
 - Asymmetrical septal hypertrophy 96, 101, 128
 - Atherosclerosis 144, 146
 - Athlete's heart 95
 - Atlantoaxial dislocation 47
 - Atrial
 - septal defect 138, 139, 151, 154, 244
 - thrombus 258, 259
 - Atrioventricular defect 152
- B**
-
- Bacterial endocarditis 181, 191, 214, 215
 - Bicuspid aortic valve 144, 147, 152, 201, 214
 - Blood-tinged sputum 45
 - Blunt chest-wall trauma 181
 - Bronchospasm 45
- C**
-
- Calcified valve annulus 248
 - Carcinoid syndrome 95, 193, 199, 225, 228
 - Cardiac
 - metastasis 270
 - tamponade 233, 237, 238
 - tumor 253, 270
 - Cardiomyopathies 87, 190
 - Causes of
 - aortic dissection 150
 - AR 214
 - AS 201
 - calcific mitral annulus 183
 - DCMP 91
 - flail mitral leaflet 181
 - large LV in
 - adults 92
 - infants 92
 - LV
 - diastolic dysfunction 81
 - systolic dysfunction 75
 - mitral
 - regurgitation 190
 - stenosis 175
 - MV prolapse 178
 - pericardial effusion 235
 - PR 228
 - PS 225
 - pulmonary hypertension 138
 - RCMP 95
 - RV dysfunction 85
 - small LV 95
 - tricuspid
 - regurgitation 199
 - stenosis 192
- Chest wall
- deformity 42
 - trauma 191, 215
- Chronic
- anemia 269
 - corpulmonale 199
 - obstructive pulmonary disease 140
 - renal failure 270
 - respiratory disease 138
 - thromboembolism 138
- Classification of
- endocarditis 243
 - HCMP 101
 - tumors 253
- Cleft mitral leaflet 190

- Coarctation of aorta 92, 144, 146, 147*f*, 150, 152, 244
- Collagen disorder 243, 270
- Color
- Doppler echo 23
 - flow mapping 170, 186, 195, 208
- Commissural calcification 176
- Congenital
- cardiomyopathy 92
 - diseases 151, 265
 - heart disease 190, 214, 244
 - mitral stenosis 175
 - tricuspid atresia 193
- Connective tissue
- disease 190, 214
 - disorder 175, 181, 199
- Constrictive pericarditis 108, 139, 233, 240
- Continuous wave 10, 15, 18, 71
- Coronary
- arterial fistula 103
 - artery
 - aneurysm 103
 - anomalies 119
 - disease 75, 81, 103, 120, 125, 190
- Cortriatriatum 175
- Criteria for severe
- AR 224
 - MR 190
 - MS 174
- Cystic medial necrosis 215
- D**
-
- Descending aorta 42
- Detection of
- aortic dilatation and coarctation 125
 - cardiac vegetations 245
 - coexisting coronary artery disease 125
 - left ventricular hypertrophy 125
 - local complications 249
 - mitral and aortic valve degeneration 125
 - myocardial ischemia 103
 - pulmonary hypertension 131
 - right ventricular infarction 103
- Diabetes mellitus 183, 269
- Diameter of aortic annulus 141
- Dilatation of
- aorta 144
 - inferior vena cava 136*f*
- Dilated cardiomyopathy 75, 87, 92, 108, 200, 270
- Dimension of inferior vena cava 84*f*
- Diseases of aorta 125, 141
- Dissection of aorta 148, 148*f*, 149*f*
- Duke criteria for endocarditis 249
- E**
-
- Ebstein's anomaly 152, 199, 200
- Effects of coexistent
- coronary artery disease 269, 270
 - hypertensive
 - disease 270
 - heart disease 269
- Ehlers-Danlos syndrome 179, 215
- Eisenmenger reaction 162, 199
- Endocardial
- cushion defects 155
 - diseases 243

Endocarditis 245
Endomyocardial fibrosis 95
Esophageal rupture 45
Estimation of pulmonary
hypertension 134

F

Failure of antibiotic therapy 250
Fallot's tetralogy 225
Flail
 leaflet 179
 mitral leaflet 179, 187
 tricuspid leaflet 199
Free wall right ventricle 41
Fungal endocarditis 250

G

Glycogen storage disease 95
Granulomatous aortitis 215

H

Heart rate and cardiac rhythm 80
High
 pulmonary artery pressure
 190
 pulse repetition frequency 13
HIV infection 270
Hurler's syndrome 175
Hypercholesterolemia 183
Hyperdynamic state 108
Hyperparathyroidism 183
Hypertensive heart disease 95
Hypertrophic
 cardiomyopathy 87, 95, 96
 myopathy 108

obstructive cardiomyopathy
 89, 98, 101

Hypothyroidism 269

I

Idiopathic
 dilated pulmonary artery 139
 hypertrophic sub-aortic
 stenosis 98, 101
 restrictive 95
Infective endocarditis 270
Inferior vena cava 42, 194
Inflammatory disease 215
Interatrial septum 39, 42
Interstitial lung disease 140
Interventricular septum 55, 98,
 125
Intracardiac
 masses 253, 265
 shunts 31
 tumor 95
Ischemic cardiomyopathy 90-92,
 111, 190

K

Kaposi's sarcoma 270
Kawasaki syndrome 120

L

Large
 anterior leaflet 61
 vegetation with
 embolization 251
 valve obstruction 251
Laryngospasm 45
Lateral wall left ventricle 41

Leaflet perforation 251

Left

atrial

- appendage thrombus 267
- diameter 57, 59
- myxoma 175, 254, 265
- systolic function 81
- thrombus 175, 258, 265

atrium 36, 38

bundle branch block 108, 139

ventricular

- aneurysm 117
- apex 41
- diastolic dysfunction 65, 269
- dilatation 269, 270
- dysfunction 111, 138, 149
- end-diastolic dimension 87, 93
- failure 167
- hypertrophy 81, 125, 269
- internal dimensions 182
- posterior wall 125, 181
- systolic dysfunction 65, 269, 270
- thrombus 90
- volume overload 190

Level of

- aortic valve 52
- left ventricle 52
- mitral valve 52

Libman-Sacks endocarditis 270

Loeffler's hypereosinophilia 95

Long-standing atrial fibrillation 167

LV

- diastolic dysfunction 77
- posterior wall motion 107
- pressure overload 92

systolic dysfunction 65

volume overload 92

M

Malignant

- disease 243
- disorder 270

Marantic endocarditis 270

Marfan's syndrome 146, 150, 190, 215

Measurement of aortic annulus diameter 72*f*, 142*f*

Mechanical prosthetic valve 248

Medial necrosis 144

Middle left coronary cusp 62

Mild pericardial effusion 270

Mitral

- annular calcification 175, 181, 190
- inflow velocity 59
- regurgitation 75, 167, 183
- stenosis 166, 256
- valve 36, 39, 60
 - disease 138
 - leaflets 39
 - level 36, 39*f*, 52, 57, 59
 - orifice 39, 59
 - prolapse 120, 150, 176, 187, 190

M-mode

LV

- dimensions 185
- level 168, 183
- MV level 168, 177, 179, 182, 185
- scan 234

Motion-mode echo 15, 17

Mucopolysaccharidosis 175

Multigate acquisition technique
13

Multiple small infarcts 75

Mural thrombus 103

Muscular defect 152

Mycotic aneurysm 146

Myocardial

contrast echo 47

infarction 105, 149, 191

infiltration 82, 95, 270

ischemia 49, 104

Myxomatous degeneration 178

N

Native valve 244

Negative test 123

Non-infective endocarditis 270

Noonan's syndrome 225

Normal

aortic dimensions 141

flow patterns 54

indices 65, 83

left ventricular end-diastolic
dimension 127

structures 53

transthoracic echo 251

valves 60

O

Obstructive airway disease 138

Occlusion of neck vessels 149

Occult left atrial myxoma 267

Ostium

primum defect 155

secundum

ASD 178

defect 155

Overriding of aorta 160

P

Papillary muscle 36, 39

dysfunction 190, 199

level 40f, 52

Parachute valve 190

Paraprosthetic leak 187

Patent ductus arteriosus 75, 138,
139, 152, 158, 244

Pericardial

constriction 82, 193

diseases 233

effusion 42, 86, 103, 149,
233, 269, 270

Pericardium 36

Pleural effusion 237

Poor thoracic window 251

Post-cardiac surgery 139

Posterior

cuspid 63

mitral leaflet 60, 114, 168,
181, 256

non-coronary cuspid 62

wall 36

infarction 108

Post-traumatic aneurysm 146

Prediction of infarction-related
artery 103

Predisposing cardiac lesions 244

Primary

myocardial disease 75, 200

pulmonary hypertension 138,
179, 199

Prosthetic valve 244

endocarditis 250, 251

Proximal

aorta 36, 41

coronary stenosis 103

Pulmonary

artery 36, 37, 43

- diameter 59
 - level 37, 38*f*, 52
 - velocity profile 137*f*
 - atresia 228
 - emphysema 42
 - hypertension 131, 173, 199, 229
 - outflow velocity 59
 - regurgitation 139, 228
 - stenosis 139, 152, 161, 225, 244
 - valve 37, 63
 - vascular disease 138
 - Pulse repetition frequency 13, 27
 - Pulsed wave 10, 15
 - Doppler 19, 21
- Q**
-
- Quantification of
 - pericardial effusion 234
 - shunt 162
- R**
-
- Red blood cells 6
 - Reduced depth of interrogation 13
 - Reiter's syndrome 215
 - Restrictive
 - cardiomyopathy 82, 87, 92, 95, 128, 242
 - lung disease 138
 - Rheumatic
 - disease 193, 225
 - fever 243, 270
 - heart disease 178, 190, 199, 201, 214, 228
 - mitral disease 199
 - valve 244
 - Rheumatoid arthritis 214
 - Right
 - atrial myxoma obstructing valve 193
 - atrial thrombus 258
 - sided endocarditis 199, 228
 - ventricle 36
 - ventricular
 - dysfunction 65, 113
 - hypertrophy 161
 - outflow tract 143, 231
 - overload 200
 - ward displaced aorta 161
 - Role of echo in
 - endocarditis 248
 - tumors 254
 - Rouleaux formation 260
 - Rubella syndrome 225
 - Rupture sinus of valsalva 139
- S**
-
- Sarcoidosis 95
 - Senile degenerative valve 201
 - Septal
 - defect 200
 - infiltration 99
 - Severe morbid obesity 42
 - Single large infarct 75
 - Sinotubular junction 56, 141
 - Sinus of valsalva 56, 141
 - aneurysm 143, 250
 - Small
 - pericardial effusion 90
 - septal leaflet 61
 - Stenotic
 - aortic valve 208*f*
 - lesions 28
 - mitral valve 167*f*

Stress echocardiography 121
 Stroke volume 60
 Subvalvular
 aortic stenosis 100
 PS 228
 stenosis 214
 ring 175
 Sustained ventricular tachycardia 45
 Symmetrical left ventricular hypertrophy 101
 Syphilitic aortitis 146
 Systemic
 diseases 269
 hypertension 75, 125, 183, 215
 lupus 190, 214
 Systolic anterior motion 89, 96, 98, 100

T

Tetralogy of Fallot 152, 160
 Thickened pericardium 236
 Thickening of chordae 176
 Thromboembolic diseases 265
 Thromboembolism in mitral stenosis 267
 Tracheoesophageal fistula 47
 Transesophageal echo 43, 45, 251, 267
 Transthoracic echo 33
 Tricuspid
 inflow velocity 59
 regurgitation 139, 194
 stenosis 191, 193
 valve 39, 40, 61, 199, 244
 Triple vessel disease 75

Type of thrombus 261

U

USG abdomen 241

V

Valve destruction and regurgitation 251
 Valvotomy 228
 Valvular
 AR 214
 AS 201
 diseases 114, 125, 165, 265
 heart disease 244
 regurgitation 270
 Valvulitis 270
 Venocclusive disease 138
 Ventricular
 aneurysm 103
 apex 109f
 dysfunction 65, 141, 183
 masses 263
 mural thrombus 118
 septal defect 75, 103, 116, 138, 139, 144, 151, 152, 160, 161, 244
 septum 39, 108f
 motion 108
 thrombus 95, 261, 265
 Volume loading 80

W

William's syndrome 202
 Worsening congestive heart failure 251